


IN SITU TISSUE ENGINEERING WITH INTEGRA EMBRYONIC HISTOGENESIS IN REGENERATIVE MATRICES

Marc E. Gottlieb, MD, FACS Phoenix, AZ

INGEGNERIA DEI TESSUTI IN SITU CON INTEGRA Istogenesi Embrionale in Matrici Rigenerativa

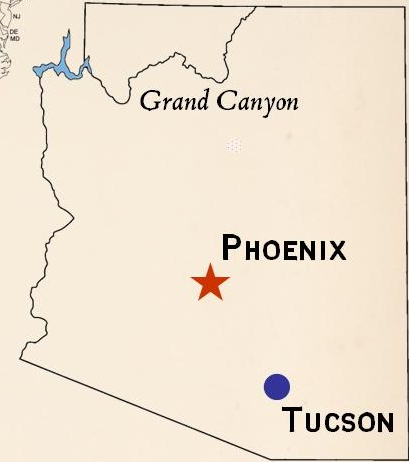
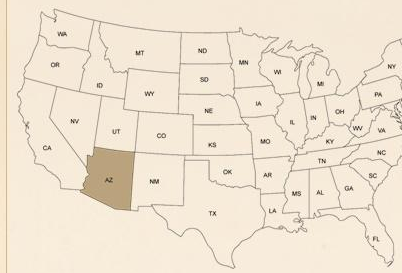
ANTELOPE PEAK.

Building something from bare landscape. —●— Arizona Territory, 1869 —●— Costruire qualcosa dal paesaggio spoglio.



University of Arizona



Banner
University Medical Center
Phoenix

ARIMEDICA

PRESENTATION IS ON THE WEBSITE

www.arimedica.com



ONE

INFLAMMATORY WOUND HEALING

- VS -

MATRIX HISTOGENESIS

**REPAIR, RECONSTRUCTION, AND
PATHOLOGICAL RISKS - THE**

INADEQUACIES

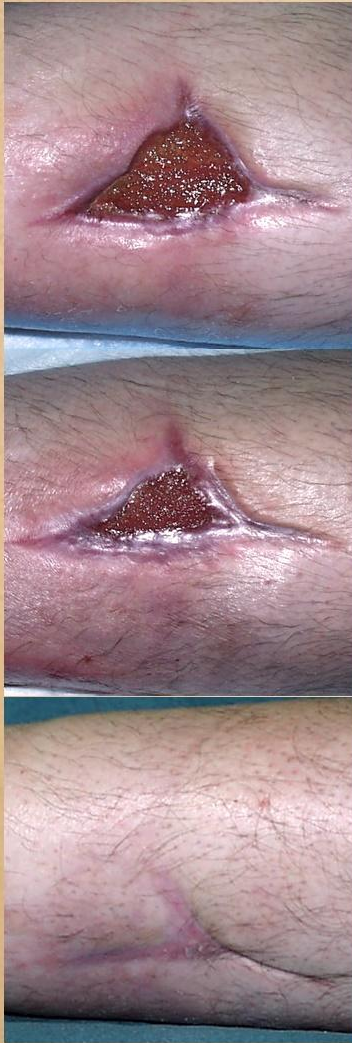**OF ORDINARY
SURGERY**

arimedica.com

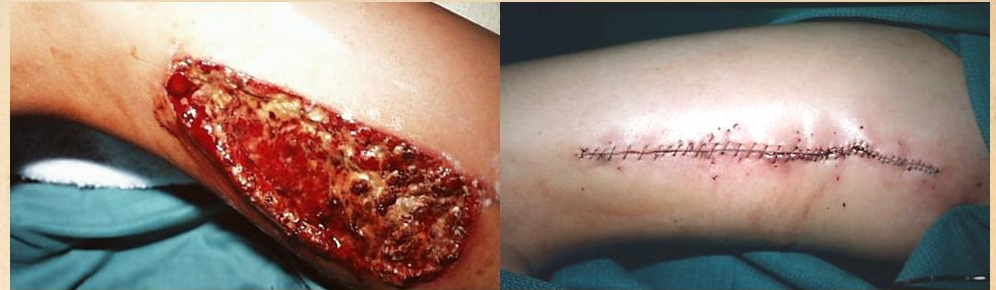2015

PARADIGMS OF CONVENTIONAL WOUND CLOSURE & RECONSTRUCTION

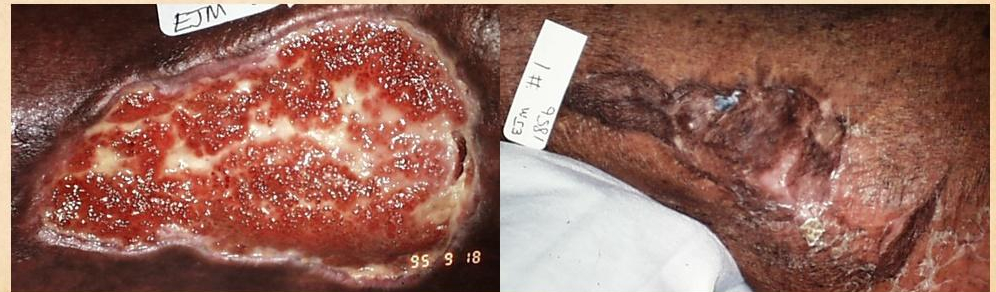All depend on normal post-inflammatory wound healing.



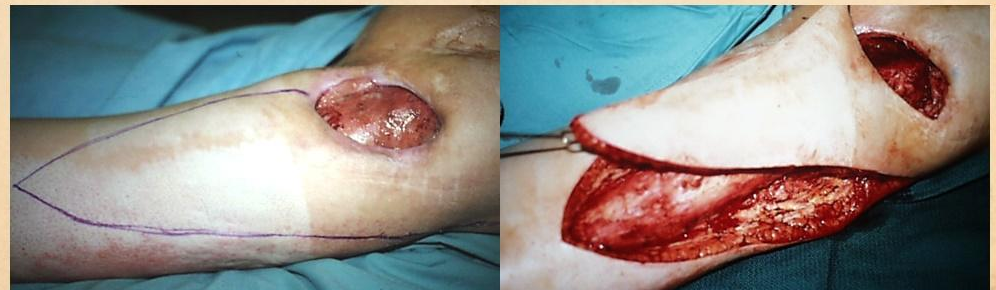0 -
Topical
Care
&
Natural
Contraction



1 - Simple Repairs



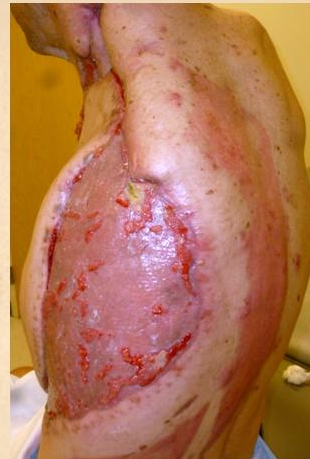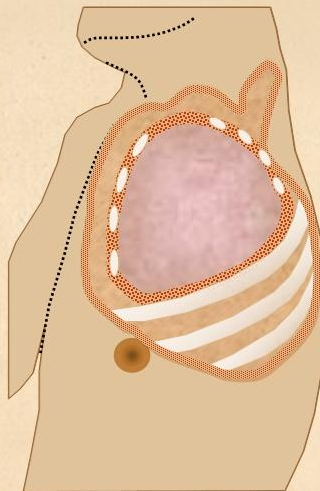
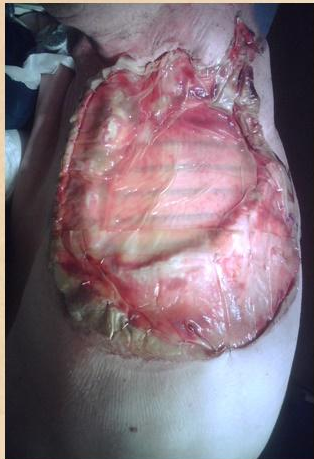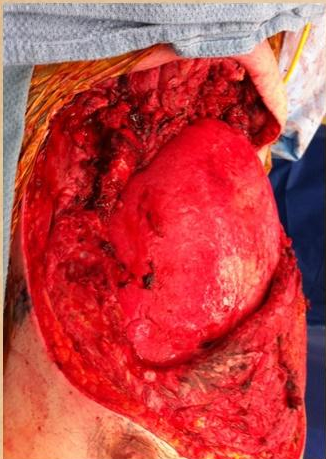2 - Grafts



3 - Flaps

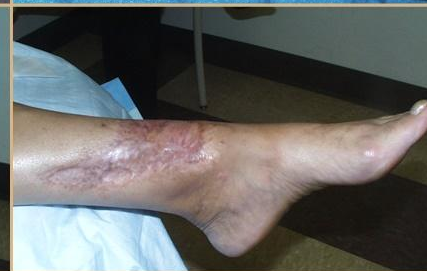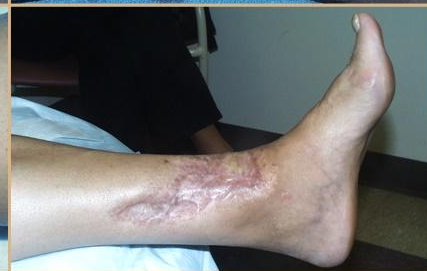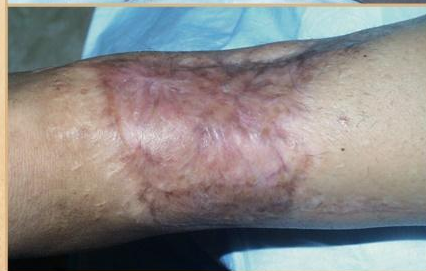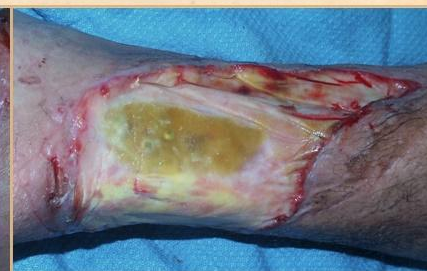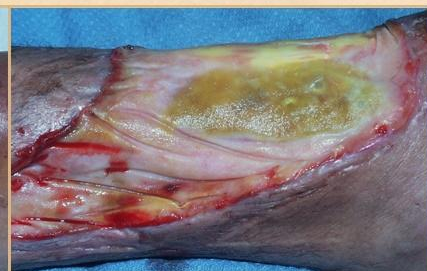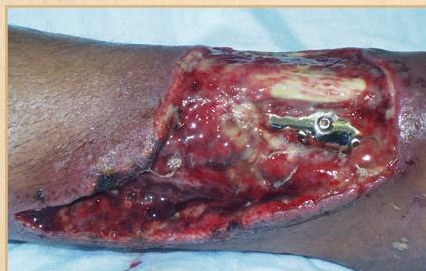WOUND CLOSURE AND ESSENTIAL COVERAGE

When flaps are required but not useable, matrices work.



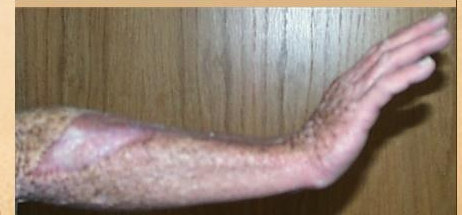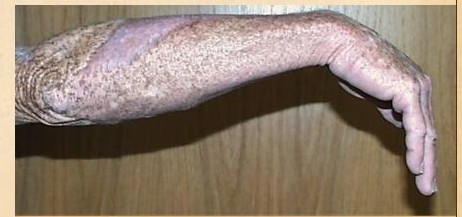
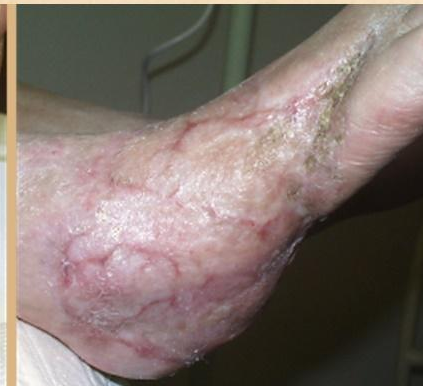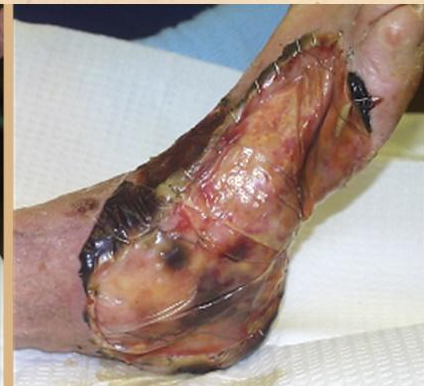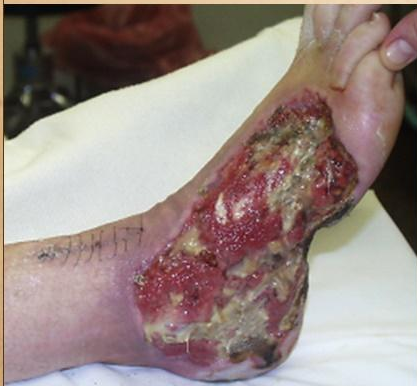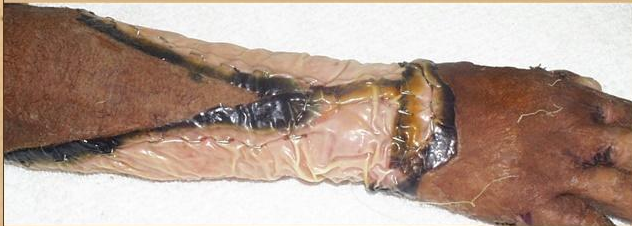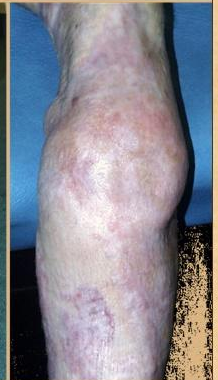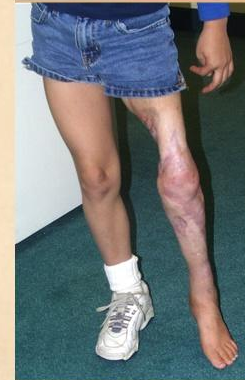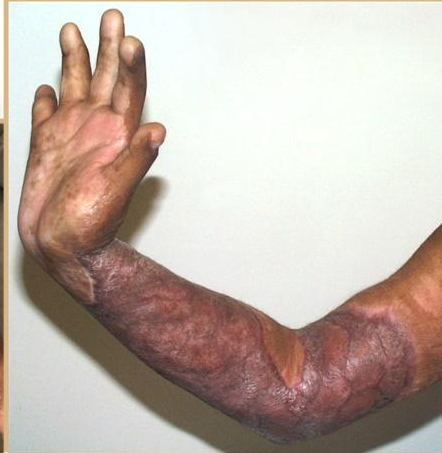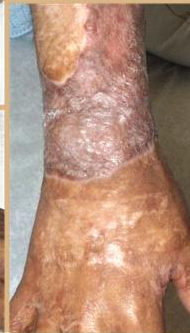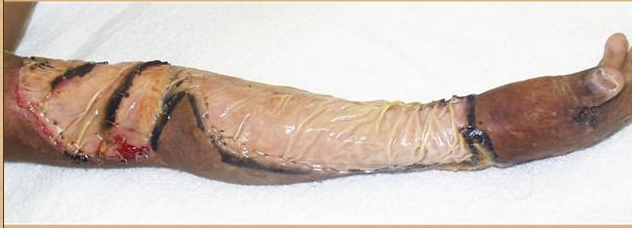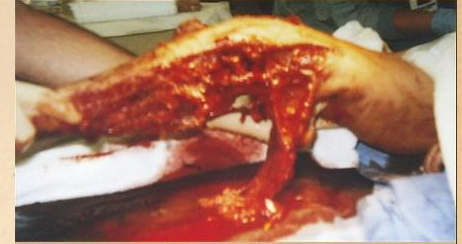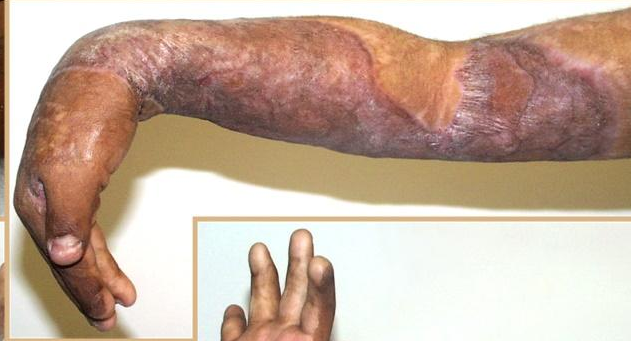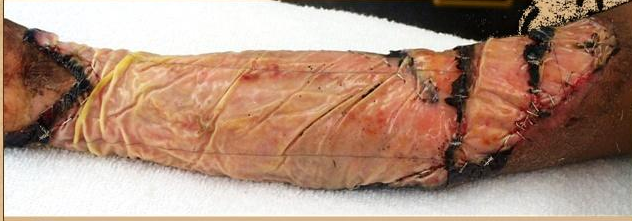*Why
Integra
?*

*Perché
Integra?*



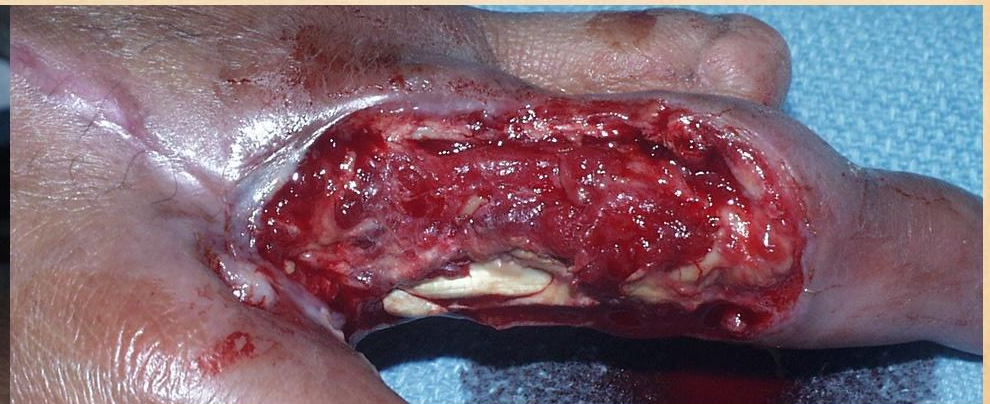
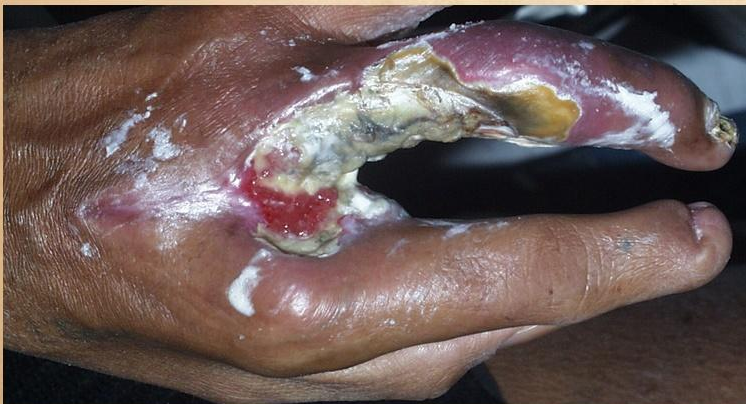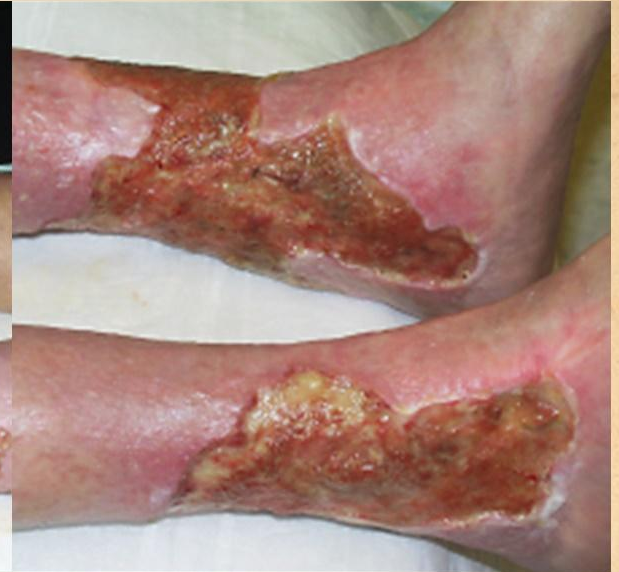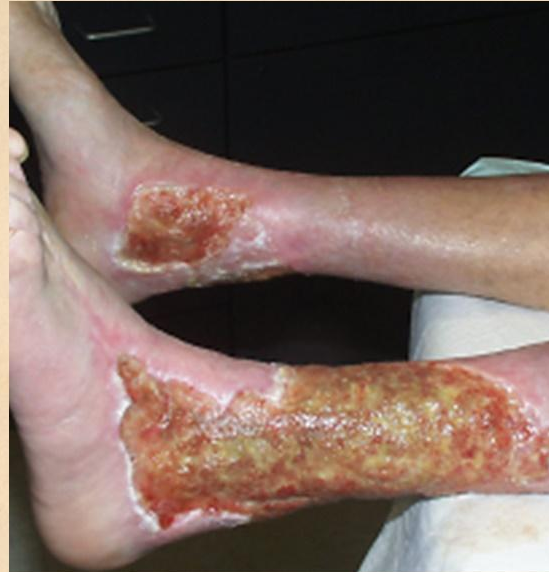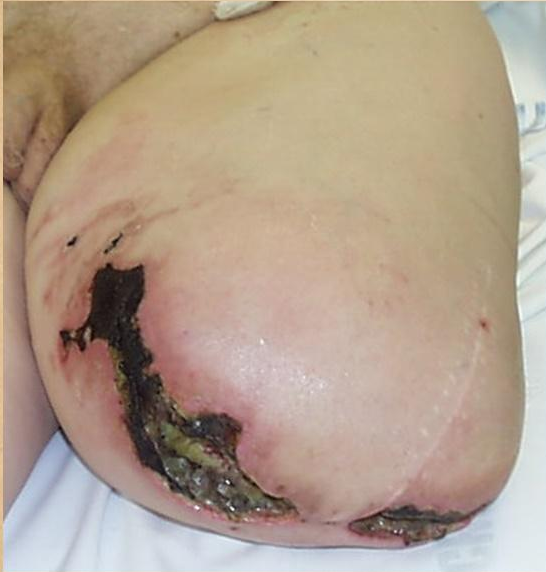SCAR CONTRACTURES AND SEQUELAE OF WOUNDS

Complications of normal post-inflammatory wound healing.



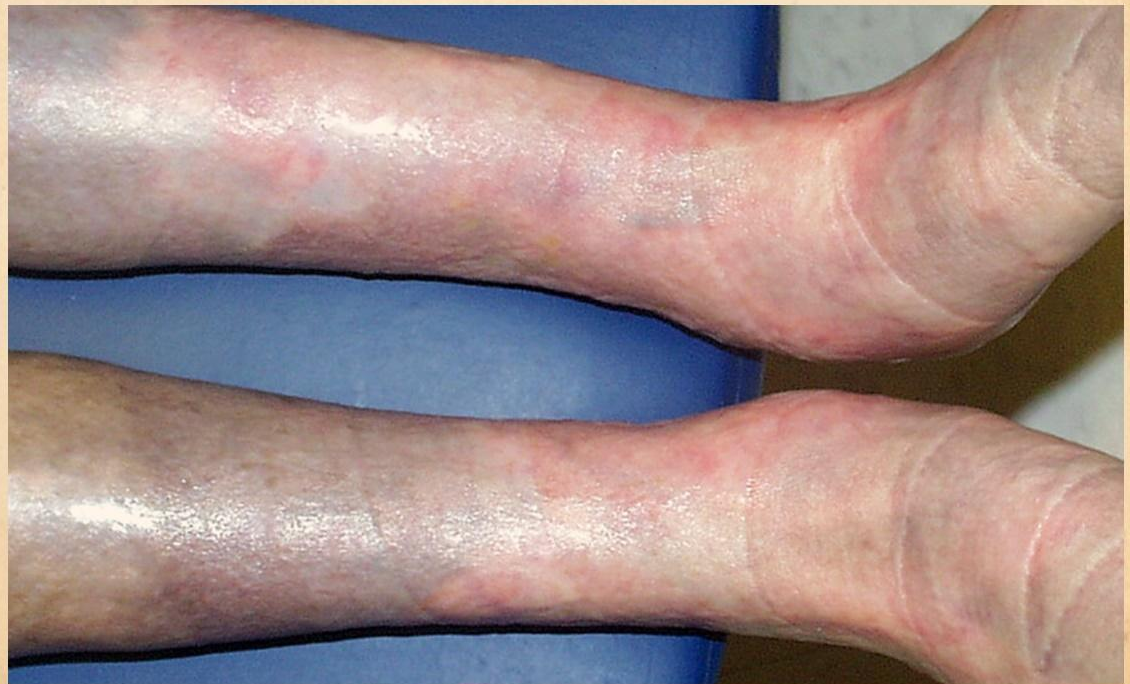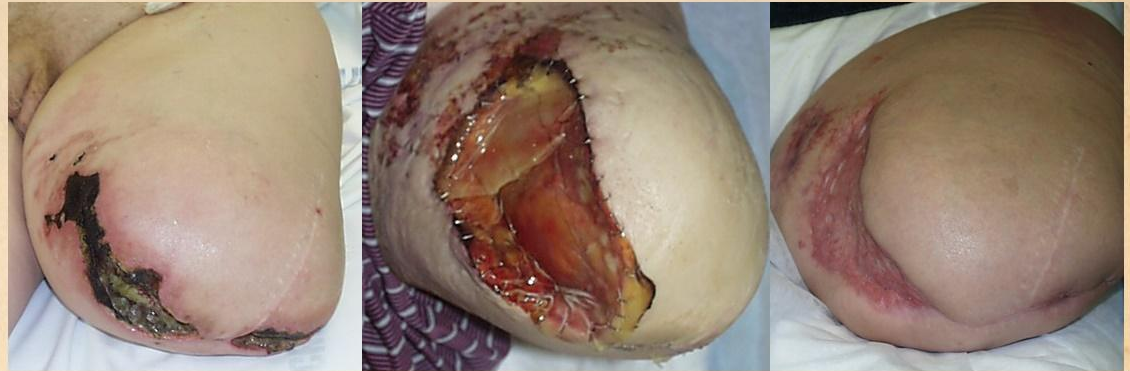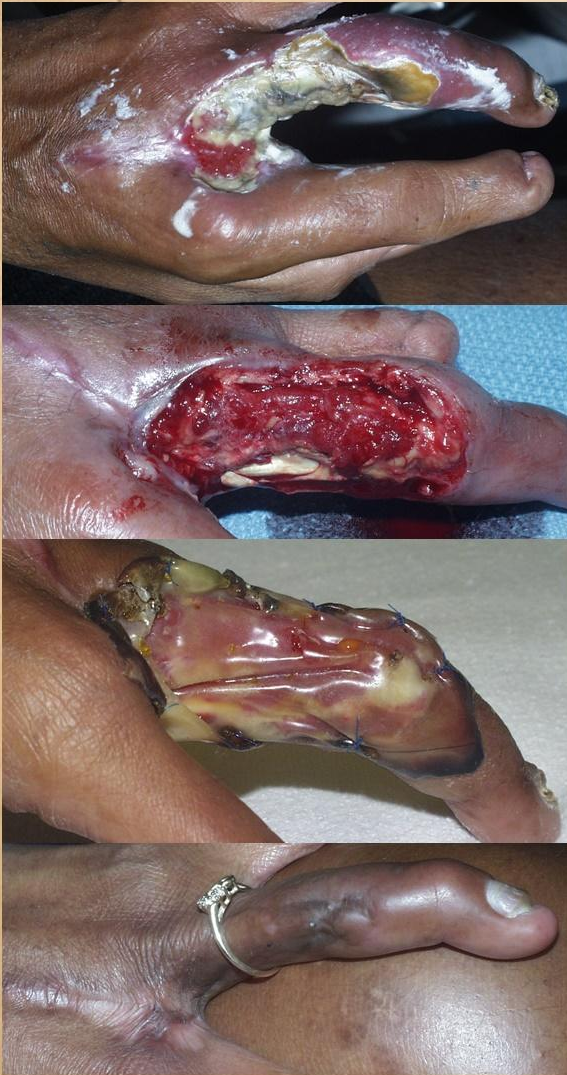THE CAVEATS OF CONVENTIONAL WOUND CLOSURE

Circumstances where normal surgery is impossible or ill-advised.



SOLVING PROBLEMS WITH REGENERATIVE MATRICES

Circumstances where normal surgery is impossible or ill-advised.

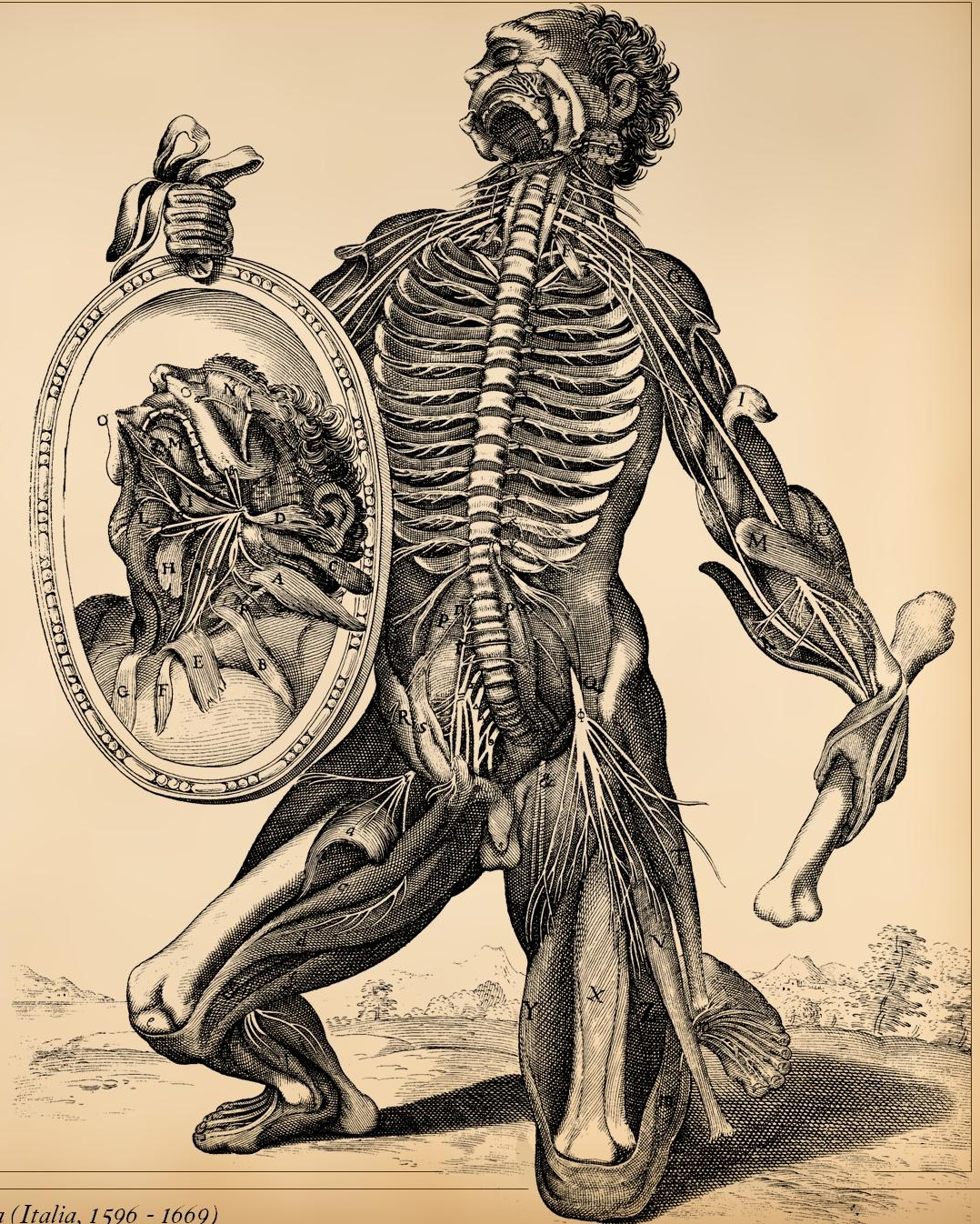

.. 2 ..

IN SITU
TISSUE ENGINEERING
- WITH -
REGENERATIVE MATRICES

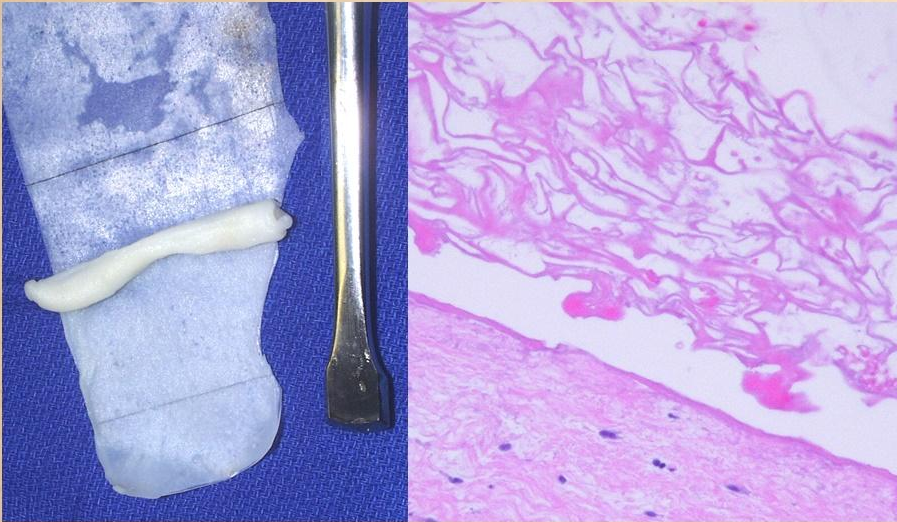
A PARADIGM OF SURGICAL
WOUND REPAIR AND
RECONSTRUCTION

INDEPENDENT
OF AND SUPPRESSES NORMAL
POST-INFLAMMATORY
WOUND HEALING



INTEGRA : A Bilaminar Surface Implant

- Layer 1** CGM – Collagen-GAG Matrix
(type 1 collagen, chondroitin-C)
- Layer 2** Silicone rubber “epidermis”

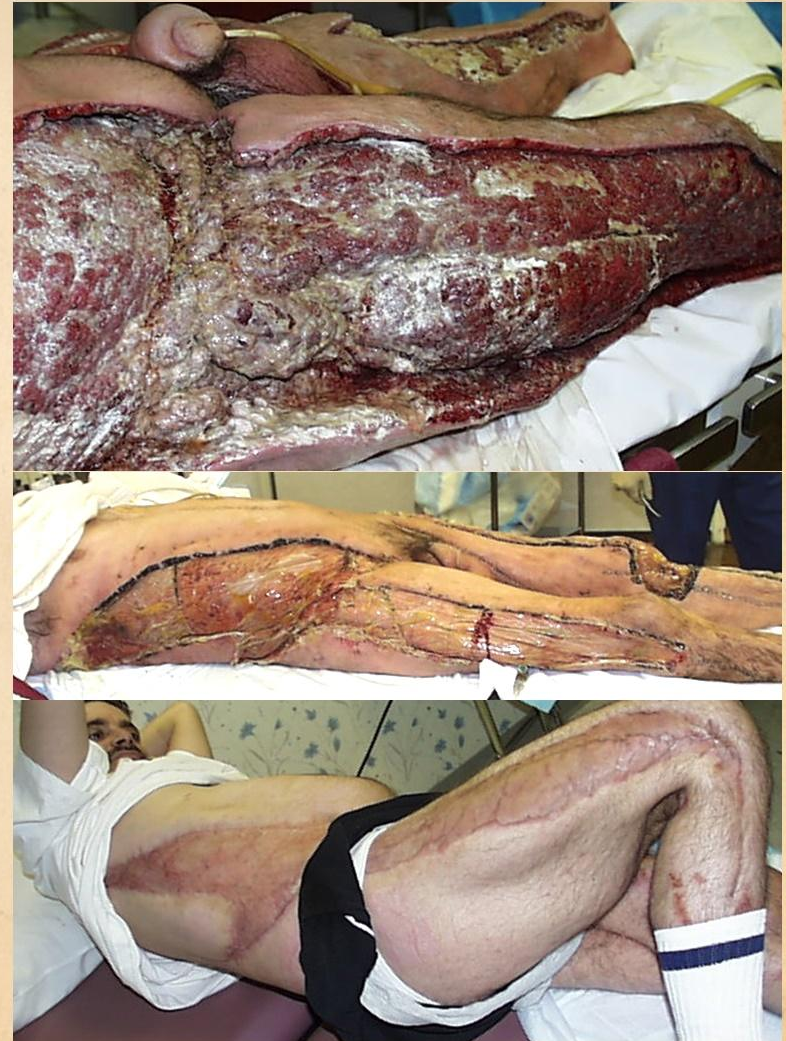

Crucial properties that confer clinical advantage

- (1) Not alive, so tolerant of adverse conditions.
- (2) Complete suppression of inflammation.
- (3) Control of residual pathology.
- (4) No inflammation ---> no wound healing ---> no scar.
- (5) Embryonic dermatogenesis ---> dermal equivalent.
- (4) No scar ---> no contraction.
- (5) Tangential histoconduction.

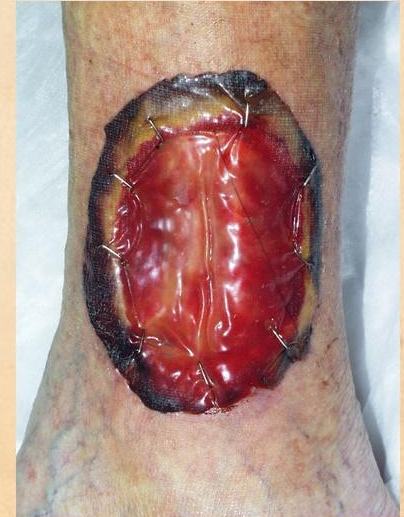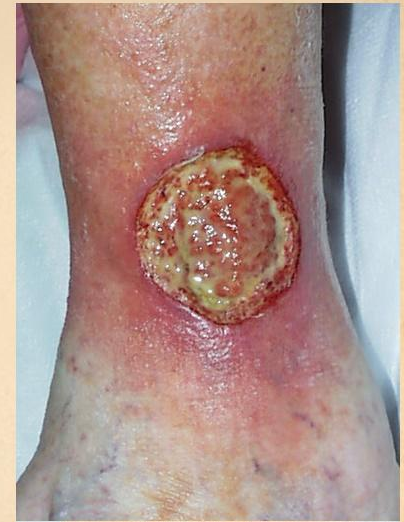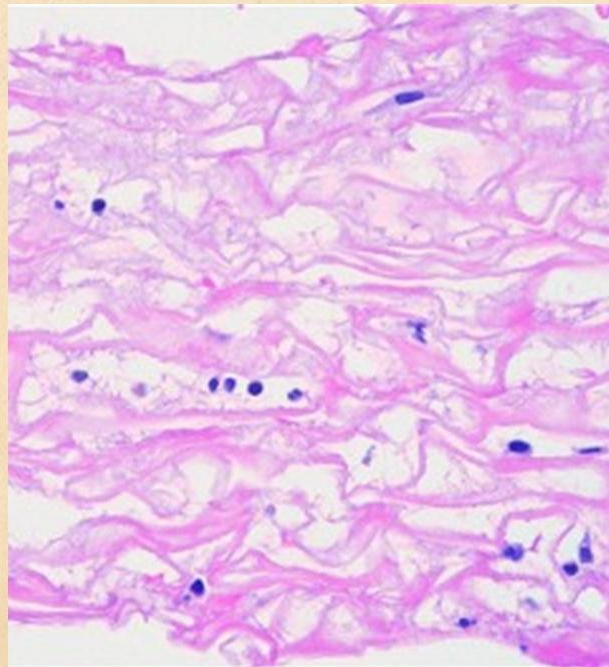
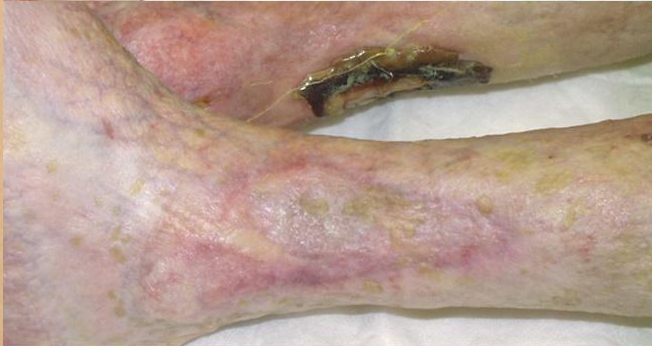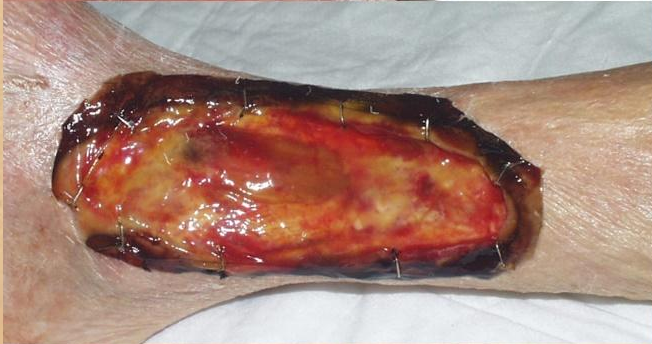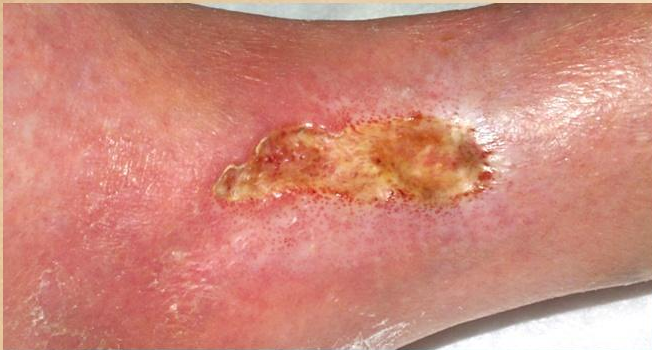1 - high quality acute artificial skin

2 - dermal regnerant & agent of reconstruction



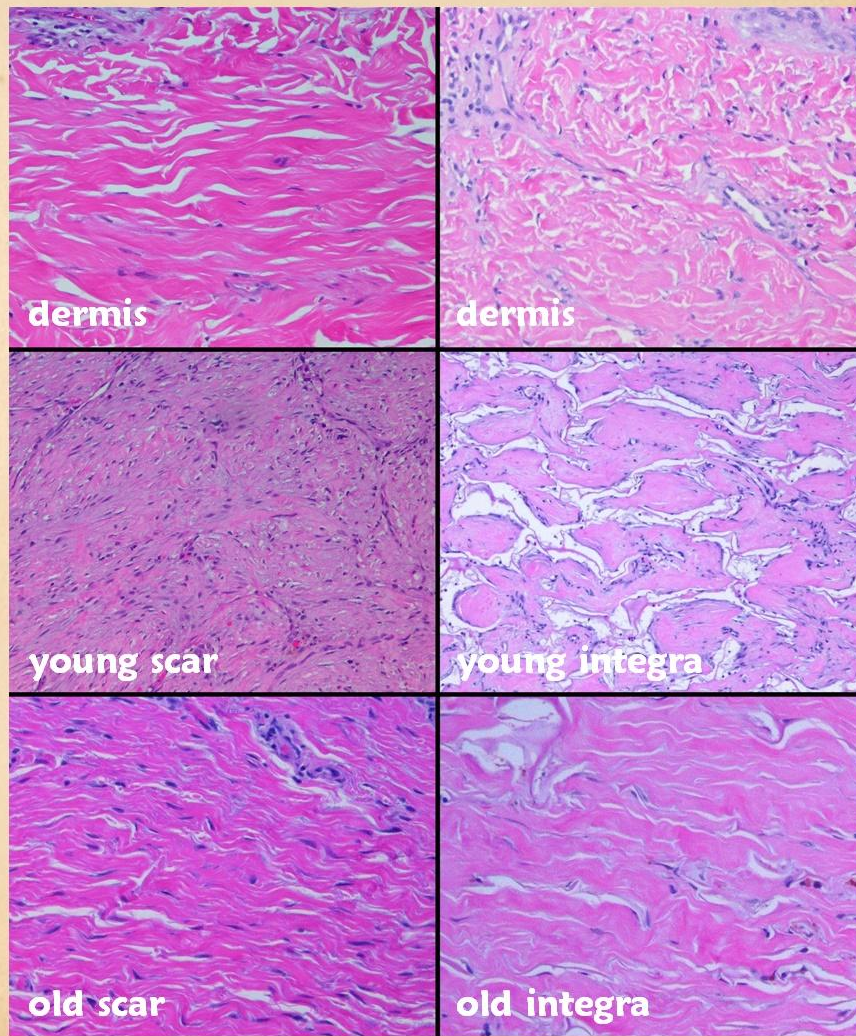
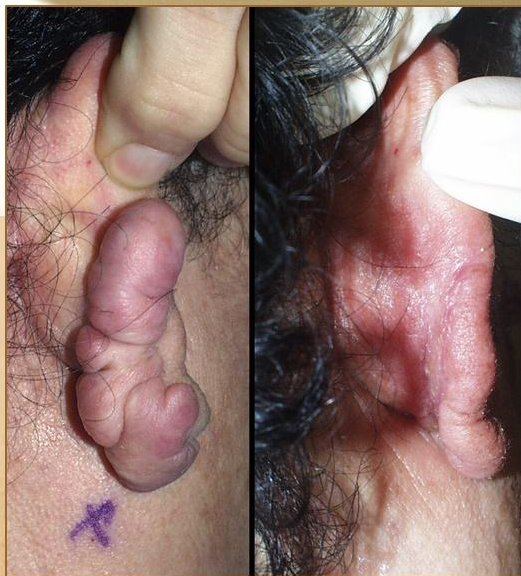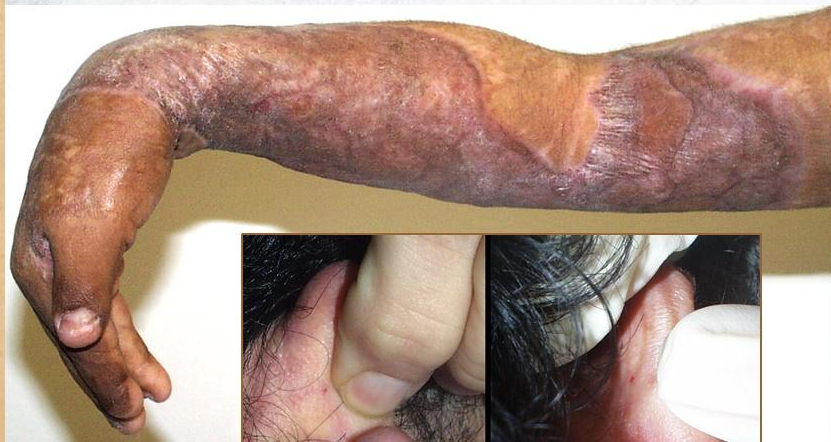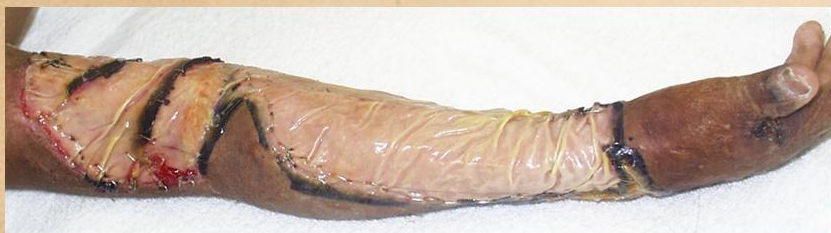INTEGRA ARRESTS INFLAMMATION

It hides the wound from the host, and it stops destructive events.

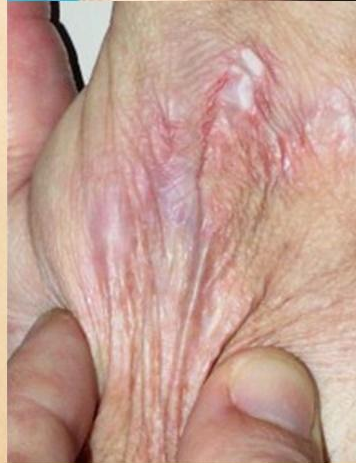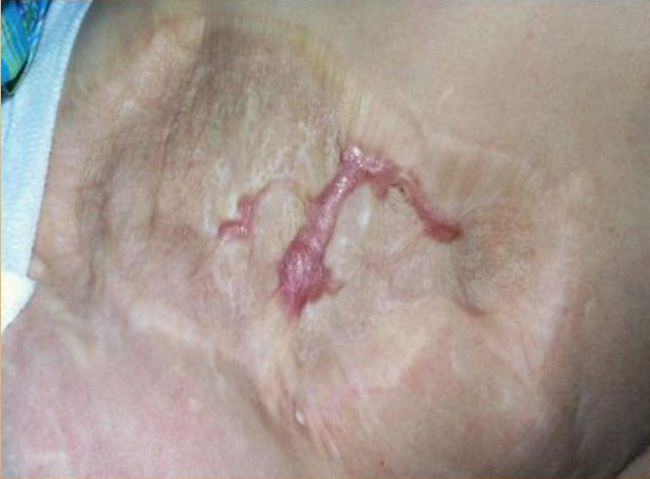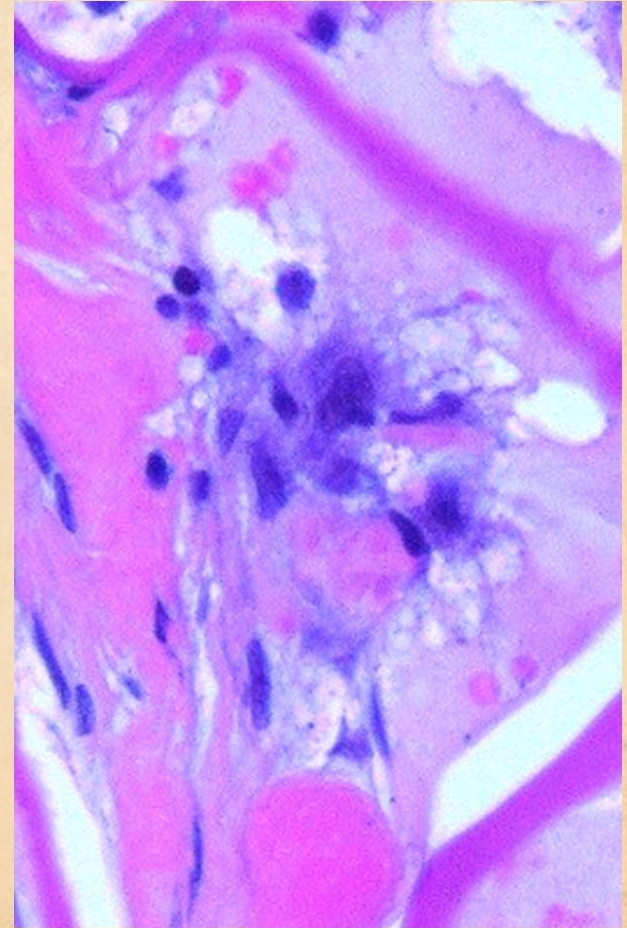


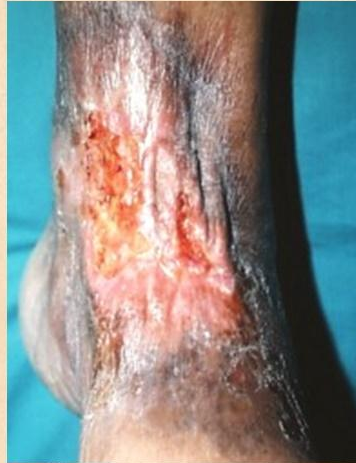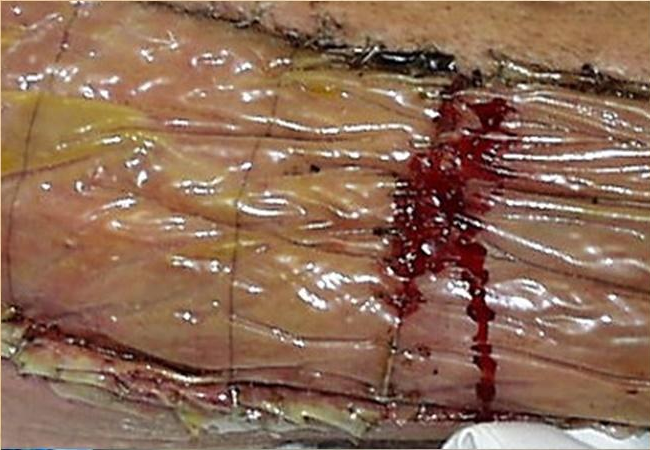INTEGRA STOPS POST-INFLAMMATORY REPAIR

No wound healing means no scar nor its sequelae.



THE CELLULAR AND BIOPHYSICAL BASIS OF INTEGRA'S EFFECTS CAN BE IDENTIFIED HISTOLOGICALLY



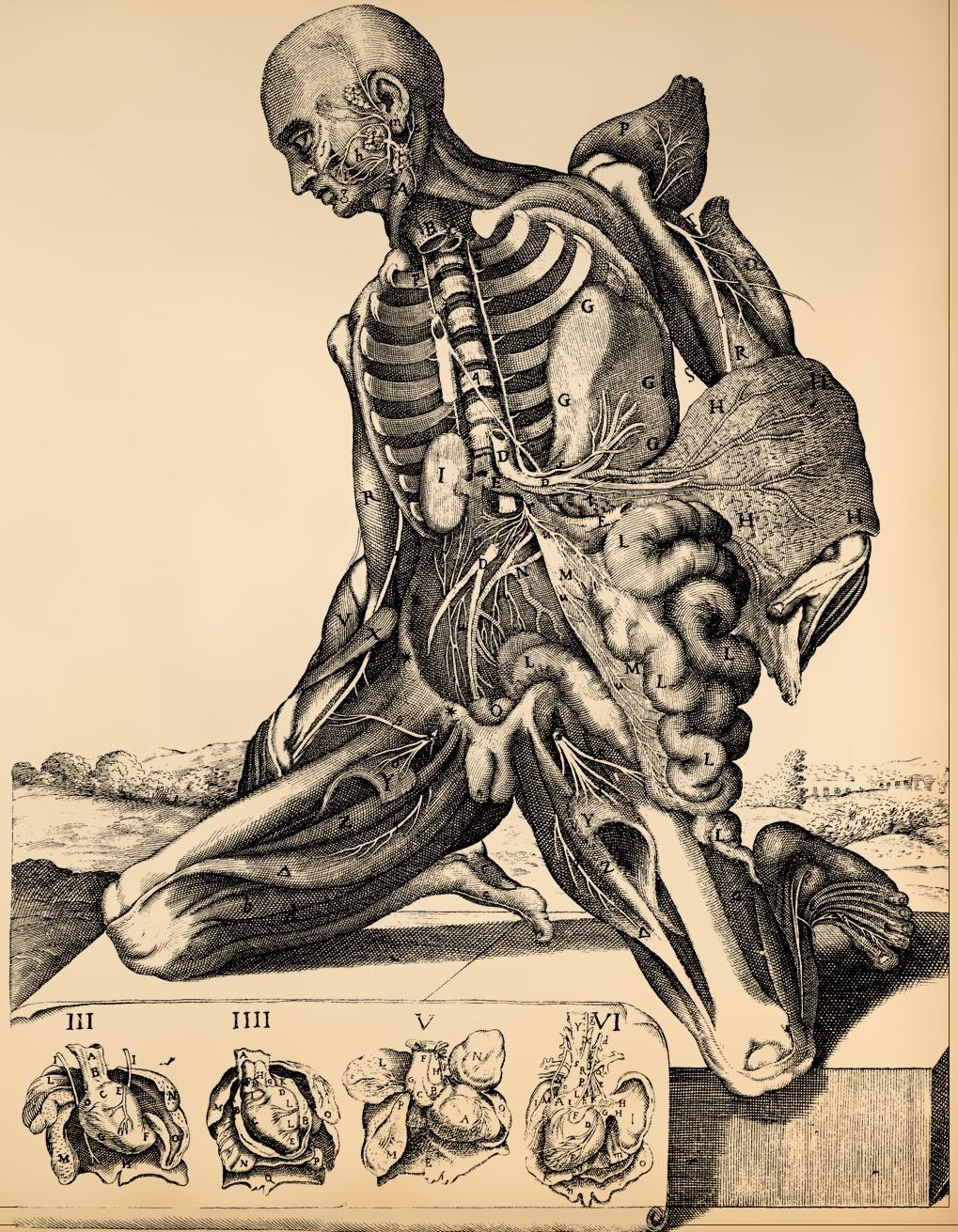

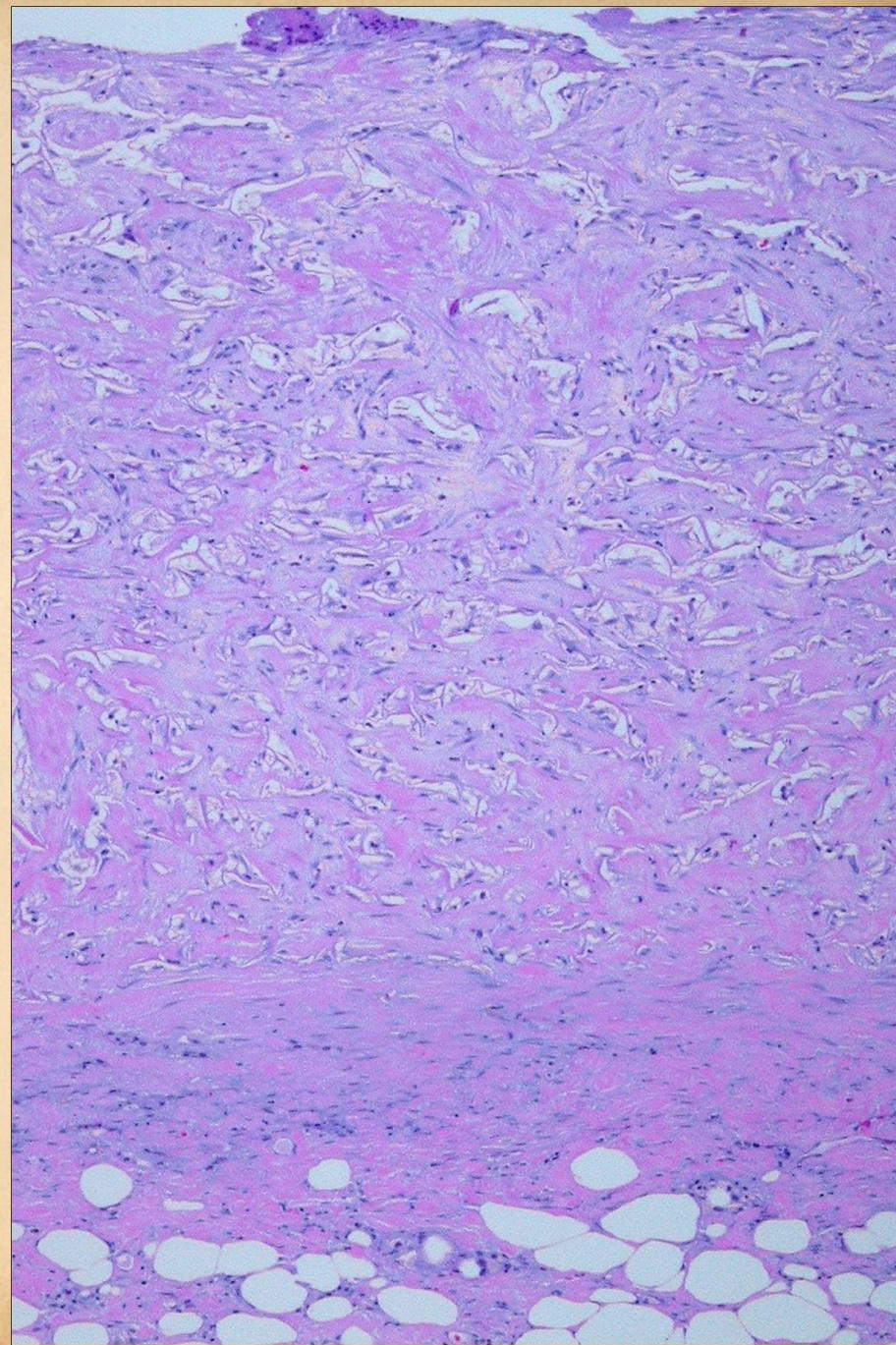
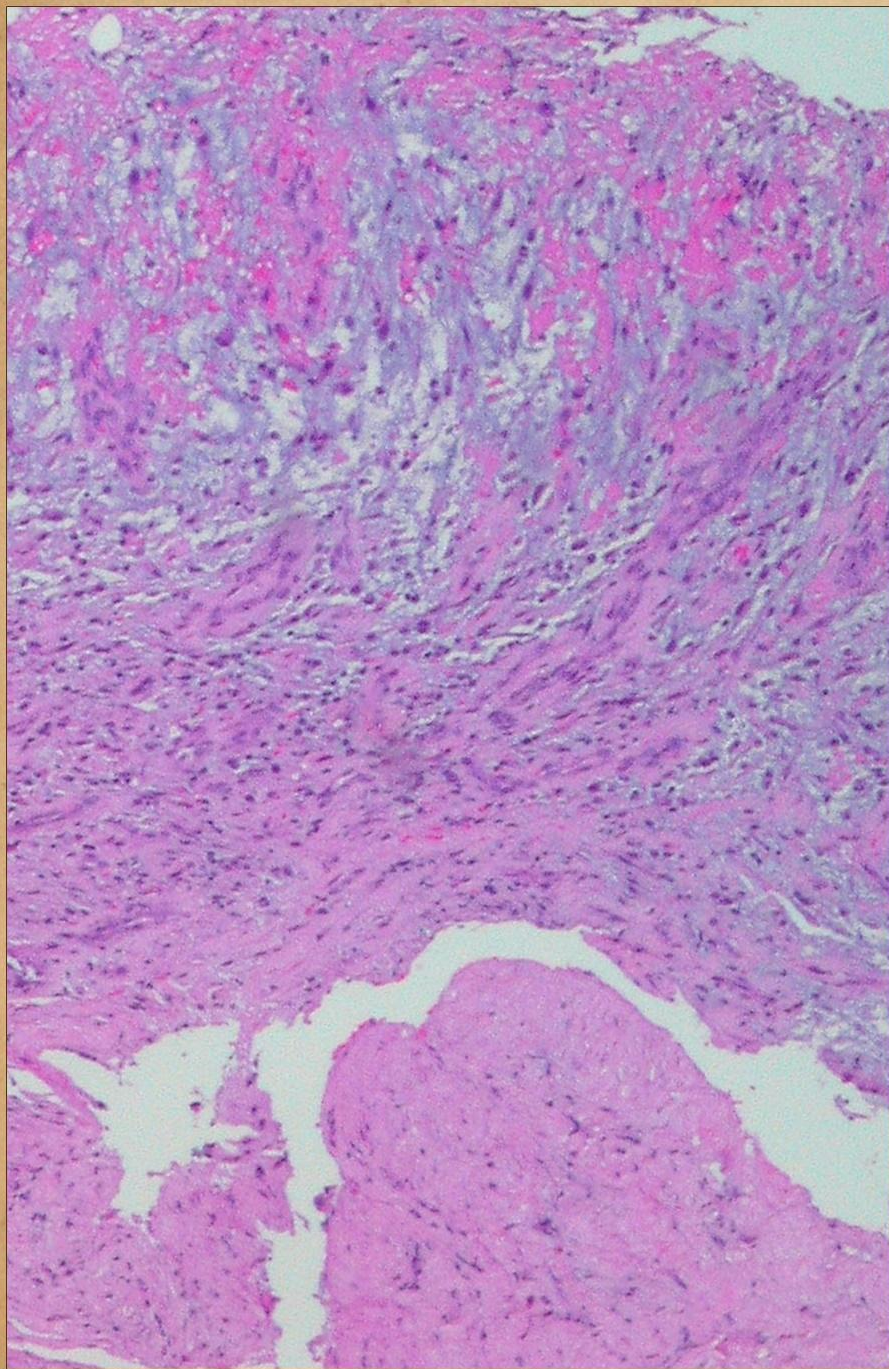
PHYSIOLOGY ^{AND} ANATOMY
- OF -
INTEGRA HISTOGENESIS

COMPARISON TO NORMAL
WOUND HEALING

HISTOLOGIC BASIS OF
ITS BIOLOGICAL
PROPERTIES

EMBRYONIC
MODE OF TISSUE
FORMATION







POST-INFLAMMATORY
WOUND HEALING



Natural Biology
and Classical Methods of Surgery



MATRIX HISTOGENESIS - INTEGRA

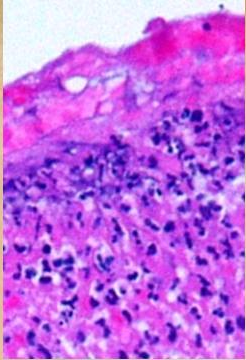


Technological method to prevent undesirable effects of normal wound healing by inducing embryonic tissue formation.



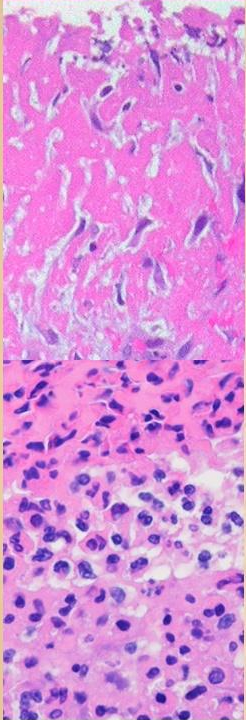
0
Injury & inflammation

*Plasma proteins.
Neutrophils.*



1
Inflammation Subsides

*Defensive, injurious.
Induces repair.*



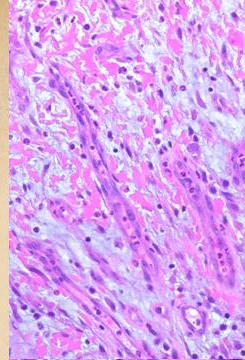
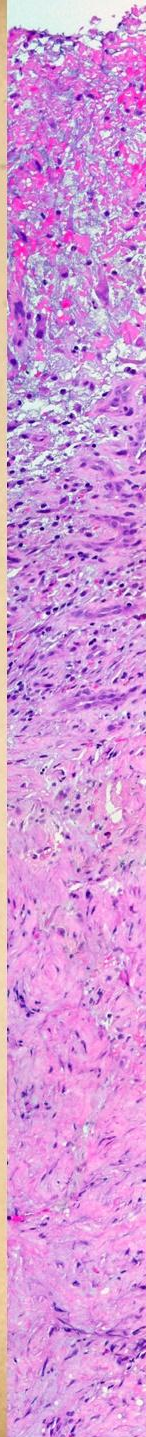
2
Monocyte - macrophages

*Separate eschar.
Recruit repair cells.*



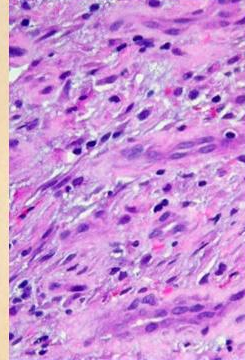
3
Aminoglycan ground substance

Environment for repair cells to create new structure.



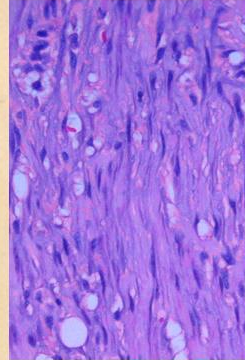
4
Angiogenesis inflammation

New blood vessels in the AG layer.



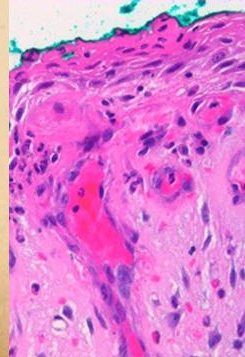
5
Fibroplasia

Connective protein tissue matrix.



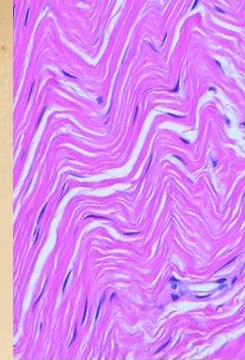
6
Contraction

Reduction of wound surface.



7
Epithelial migration

Outgrowth onto the other proliferative elements.



8
Maturation

Scar remodeling back to normal dermis or fascia.

NORMAL WOUND HEALING

SEQUENTIAL STRUCTURES & EVENTS

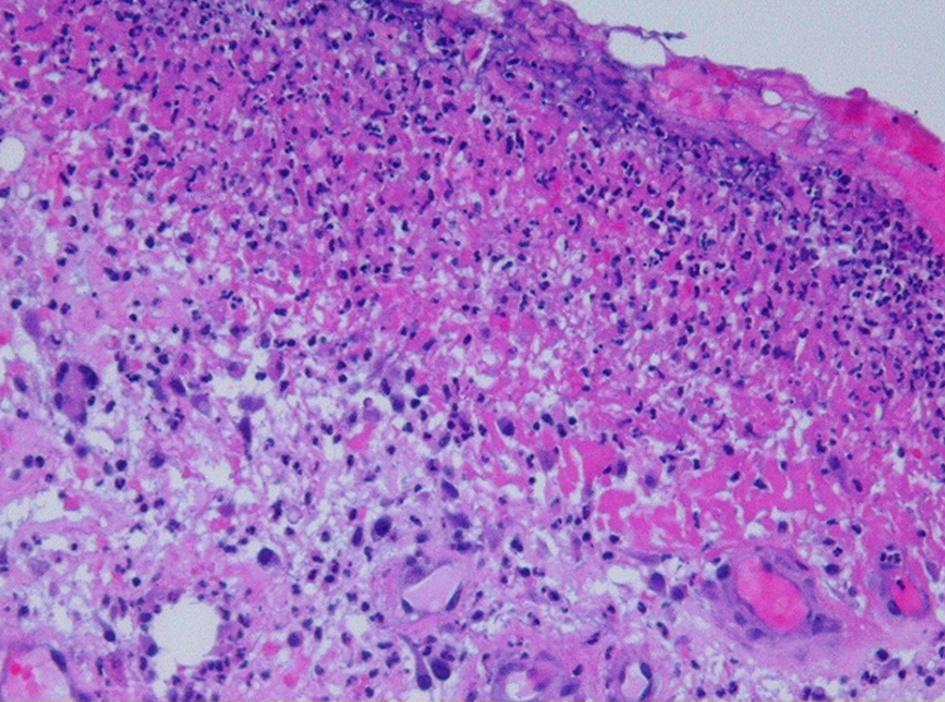
TEMPORAL & SPATIAL RELATIONS

0 TIME - DAYS

7

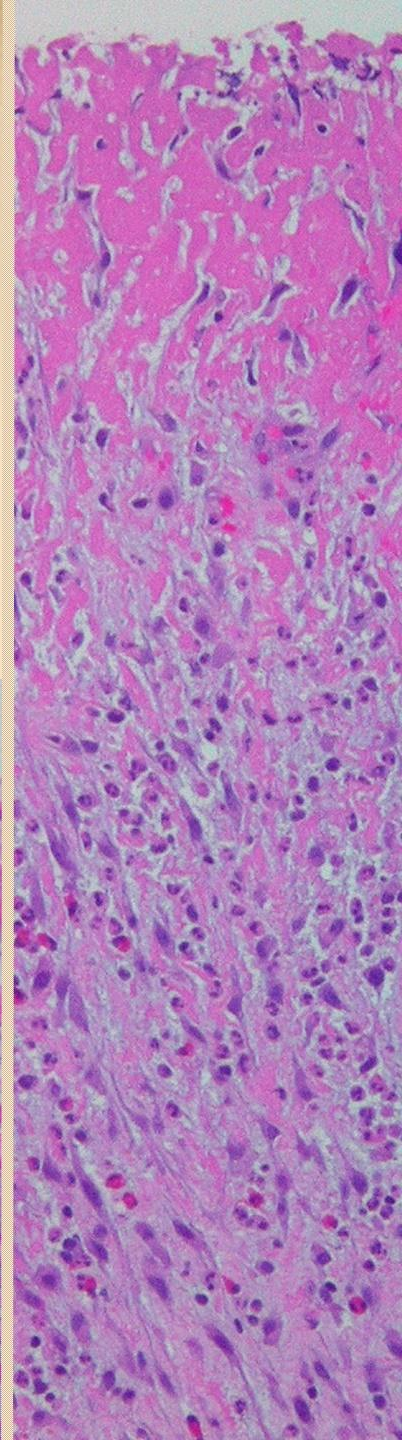
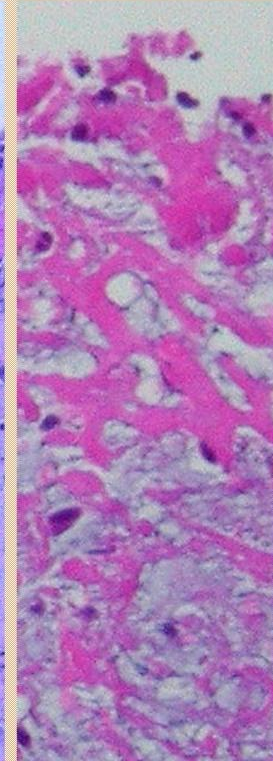
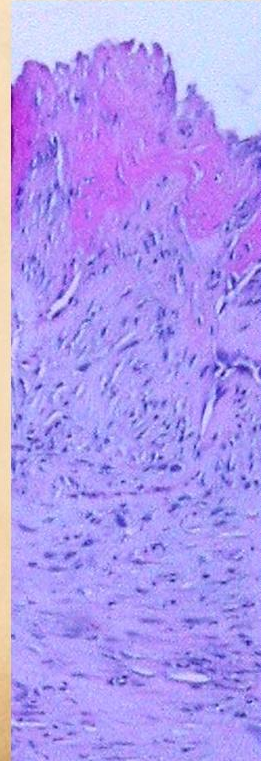
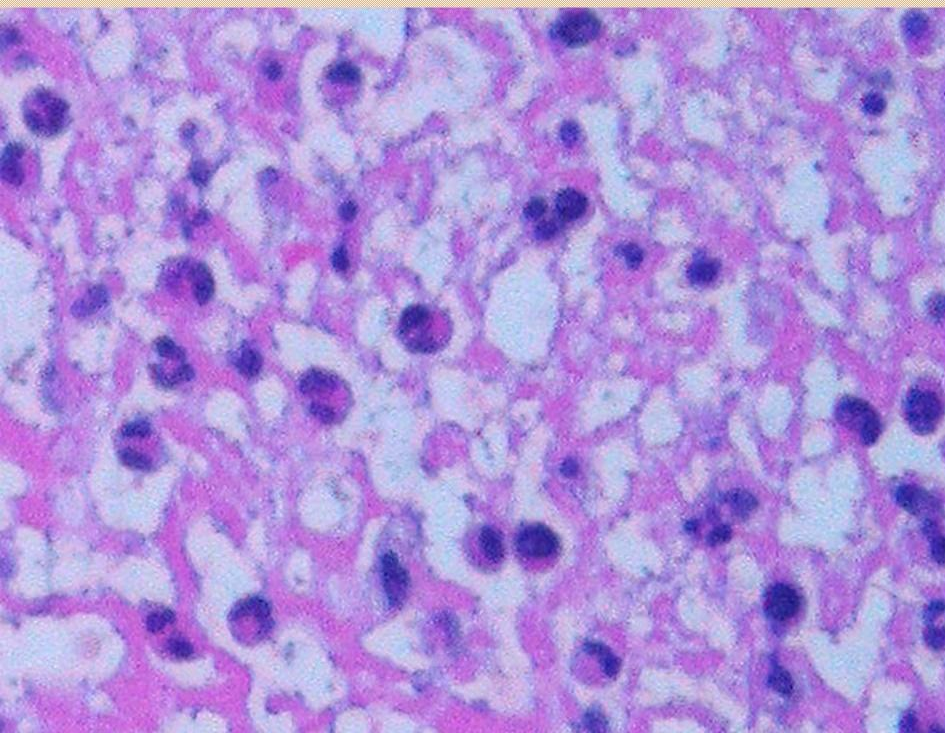
Plasma
Acute infl
Gag - attraction
Angio - acute inflammation
Gag - vertical migration
Angio - organization
Connectives
angiogenesis & granulation tissue

fibrogenesis & scar

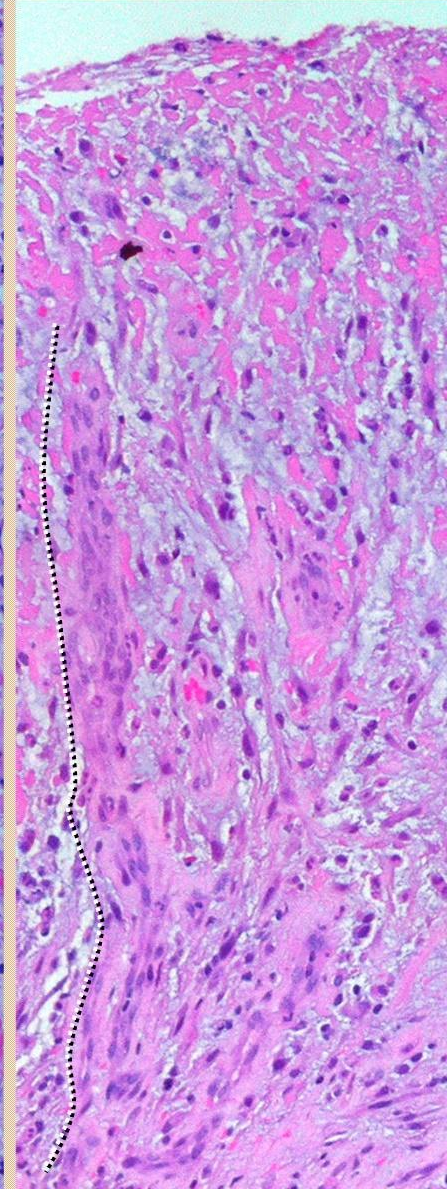
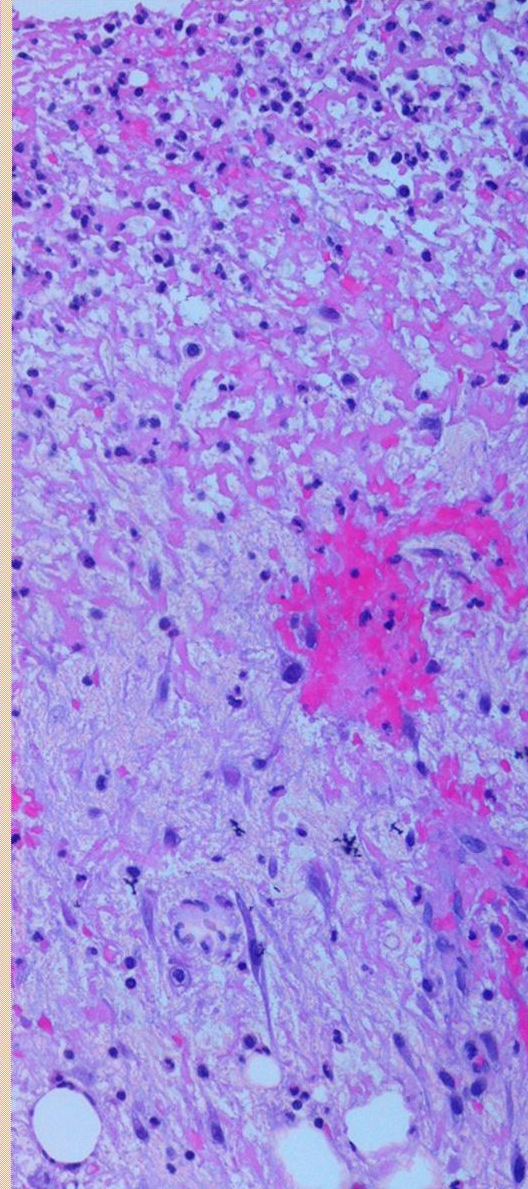
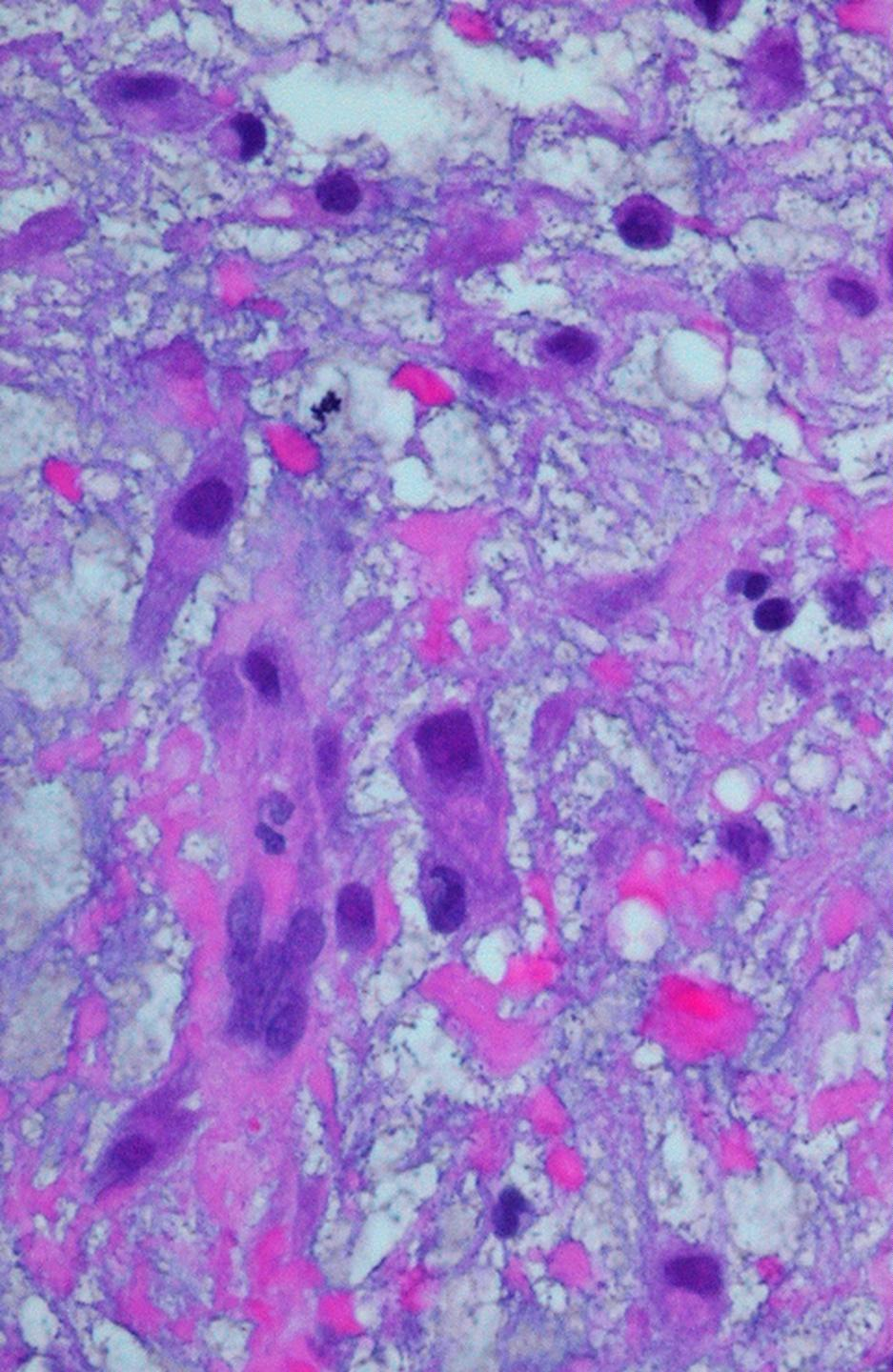


0
Inflammation
& Injury

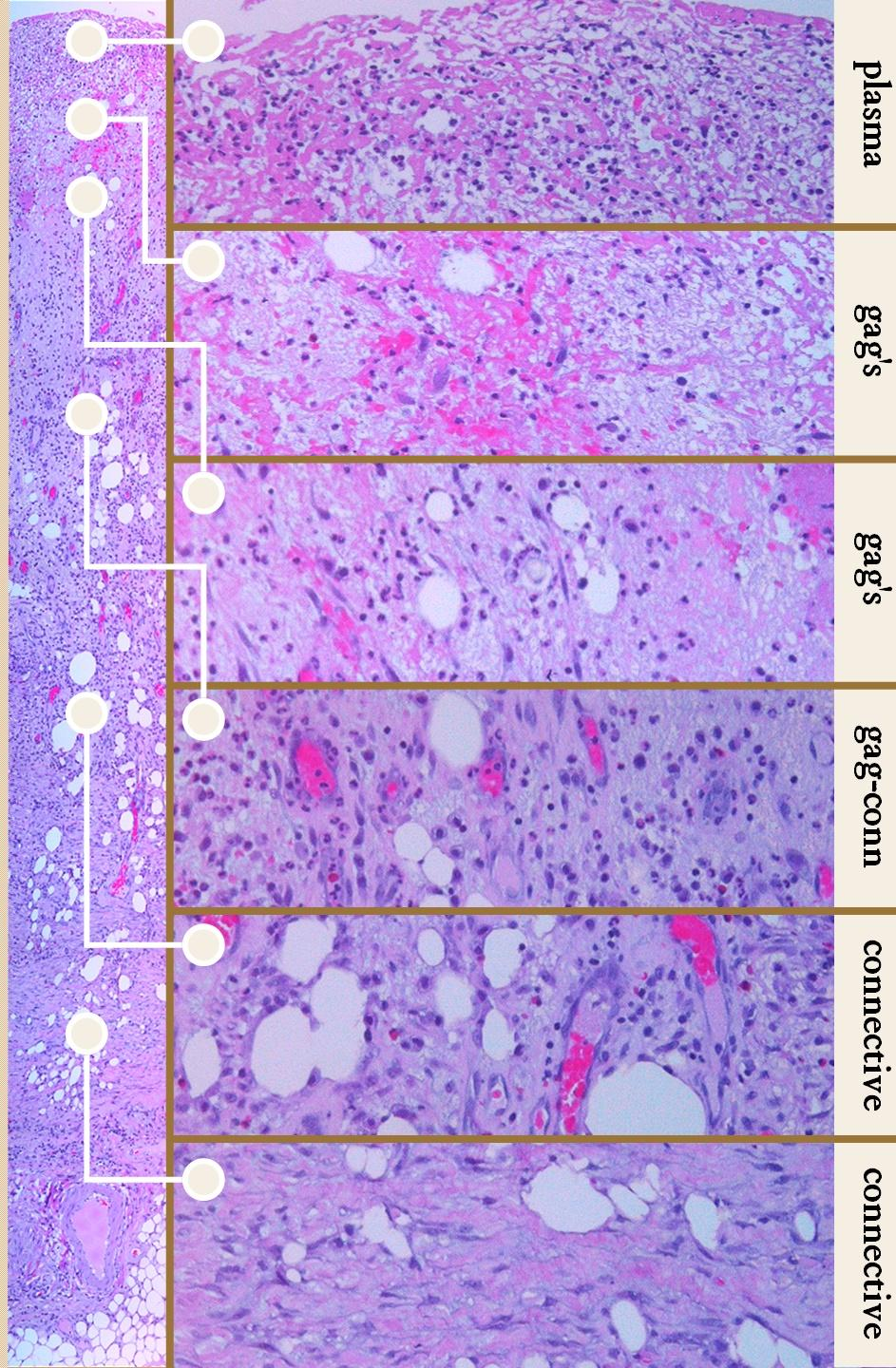

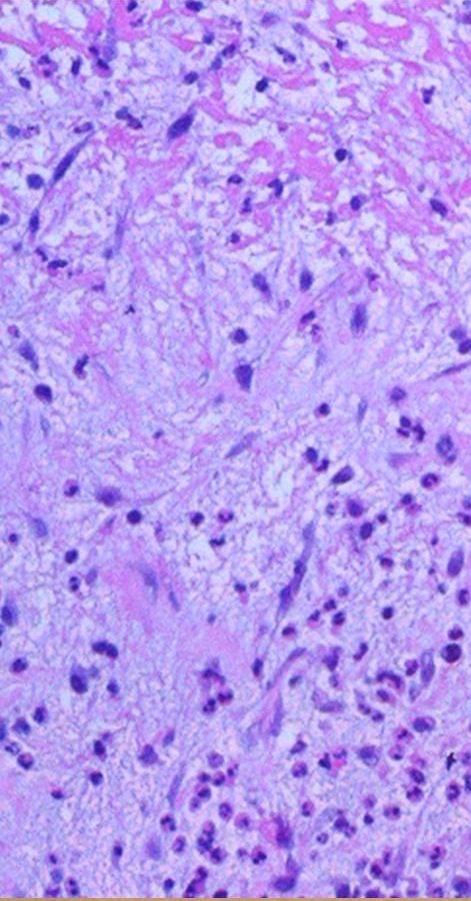
I
Inflammation
Subsides



II Macrophages & Cytokines Initiation of Repair



III Aminoglycan Ground Substance

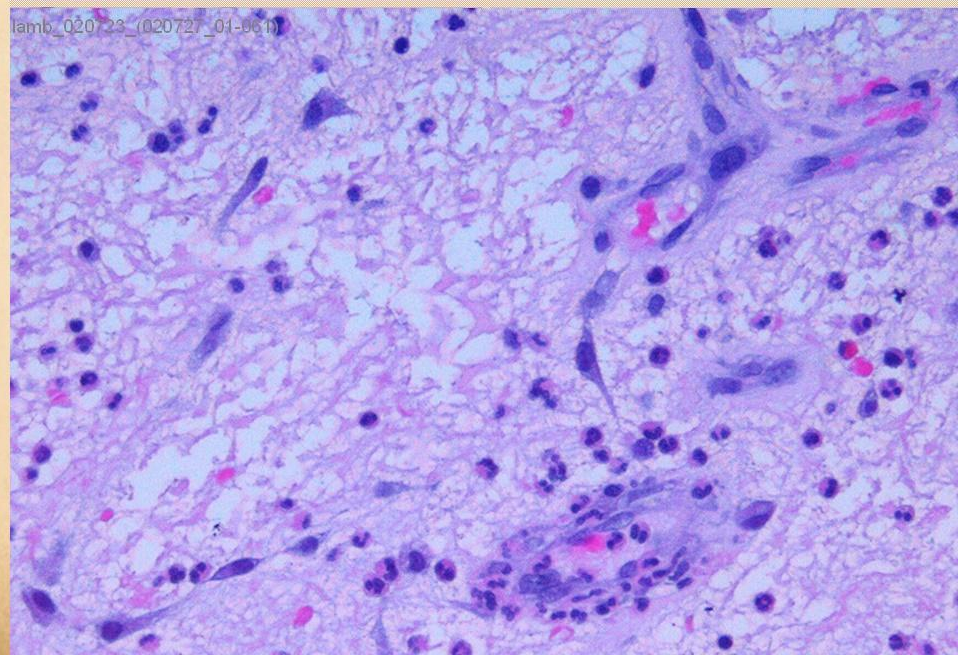
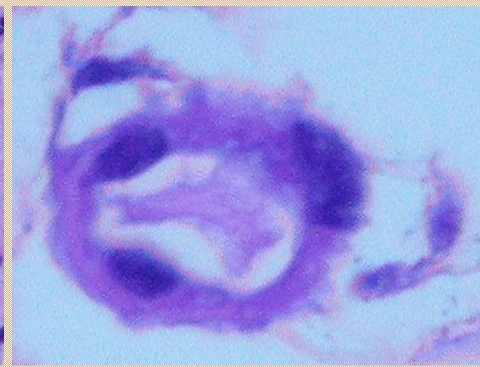
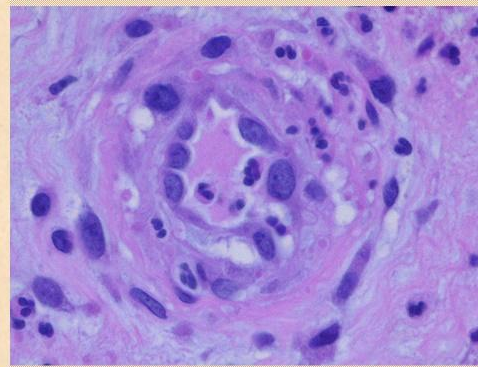
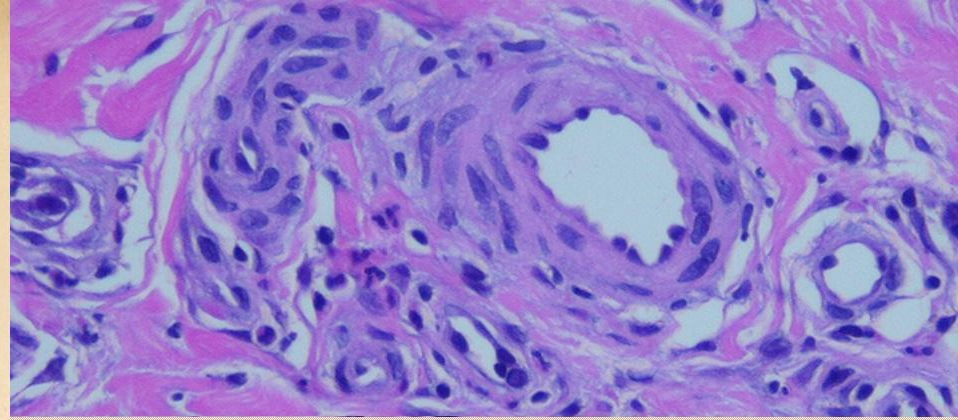
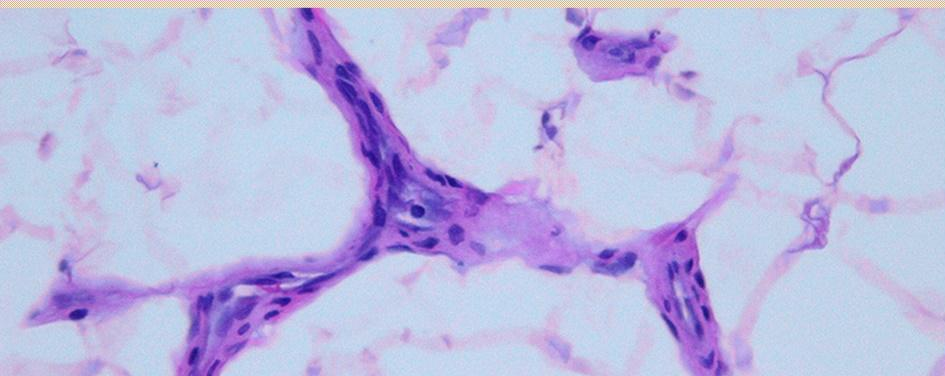
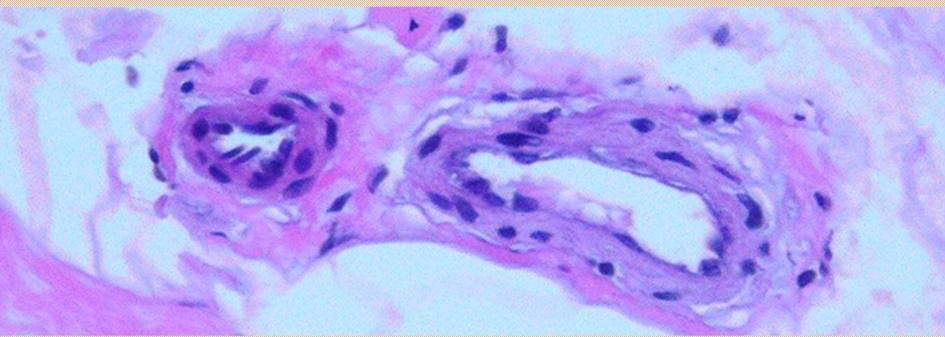
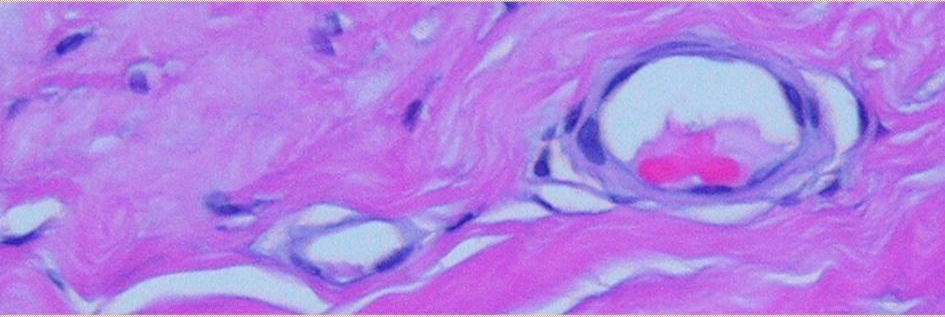


IV a

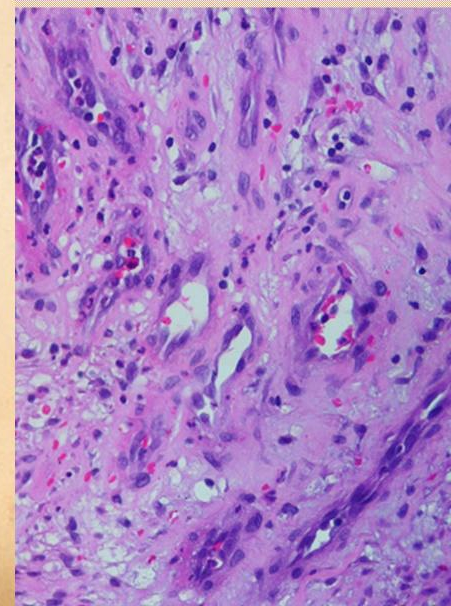
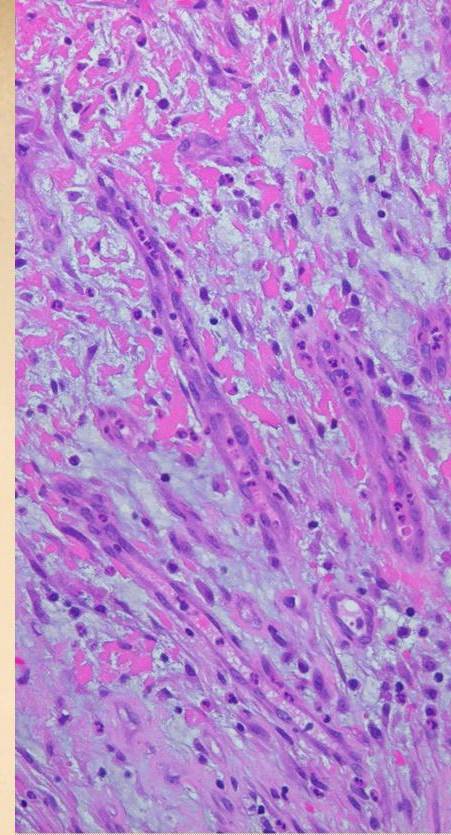
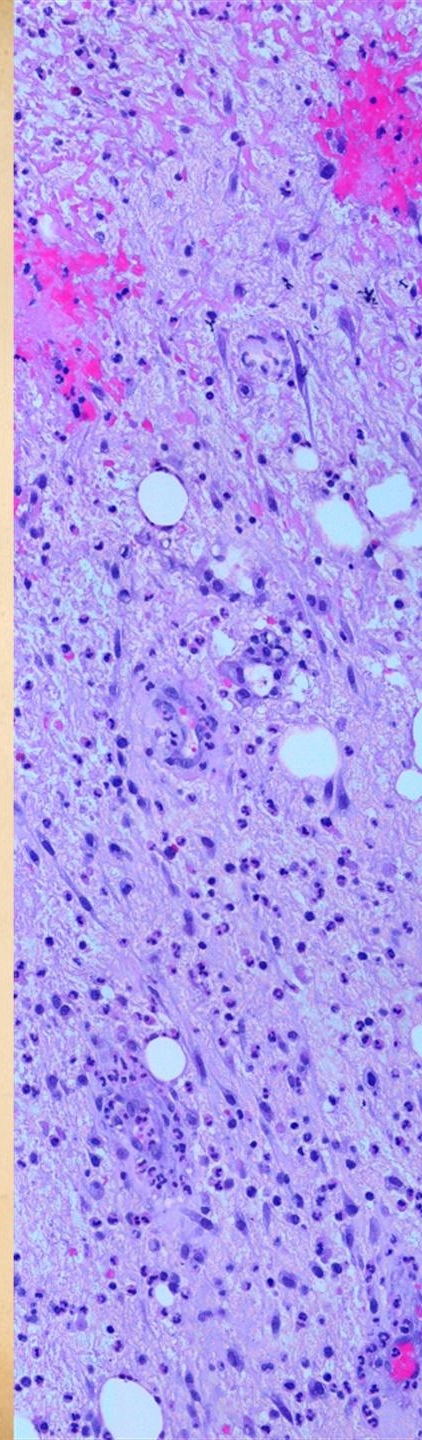
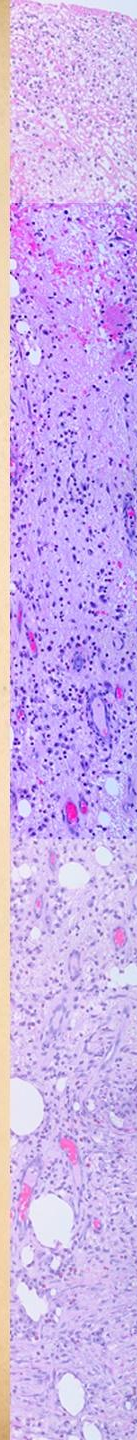
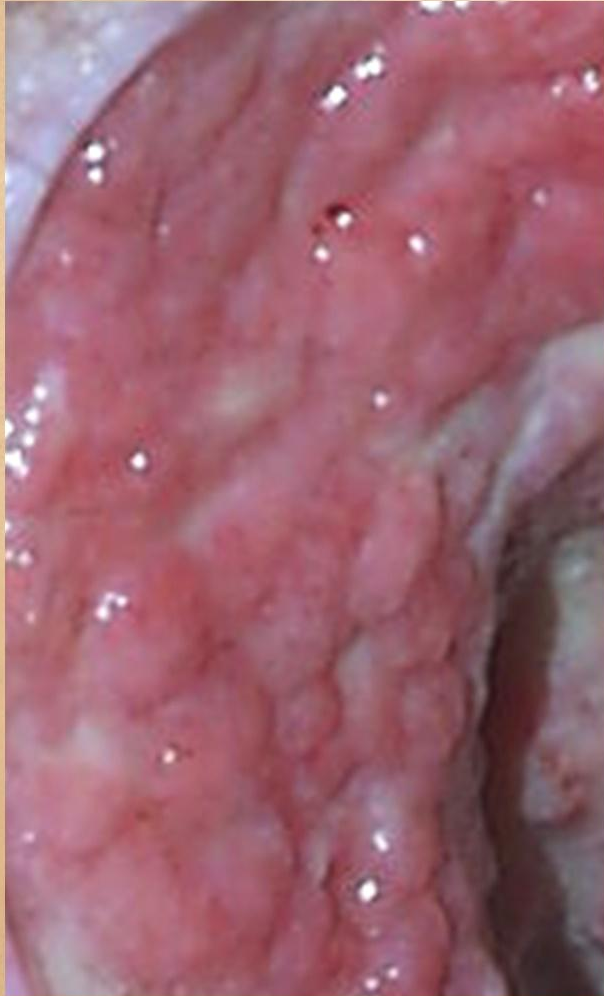Stimulated

Angiocytes & Histogenetic Cells

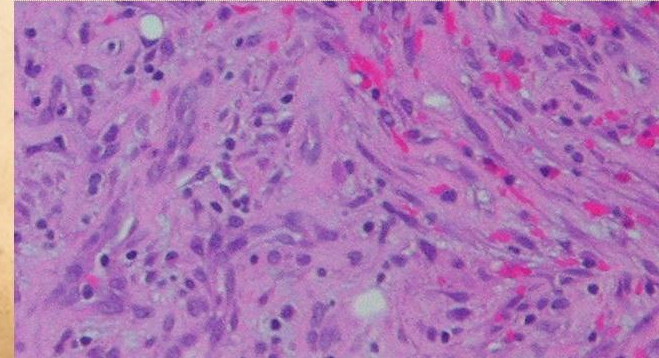
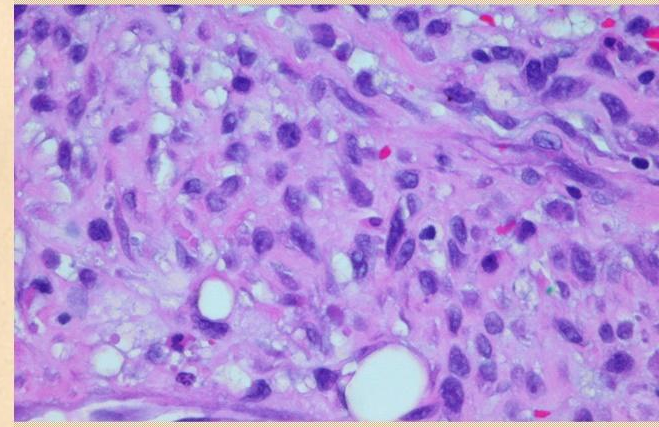
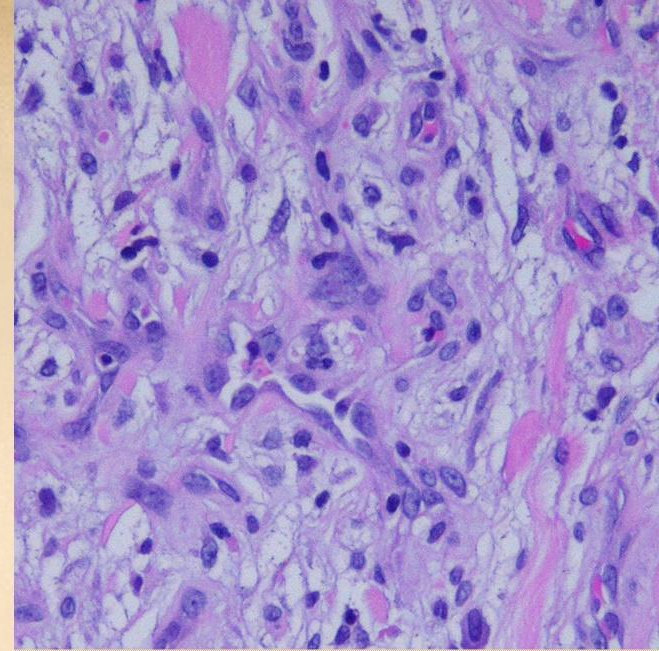
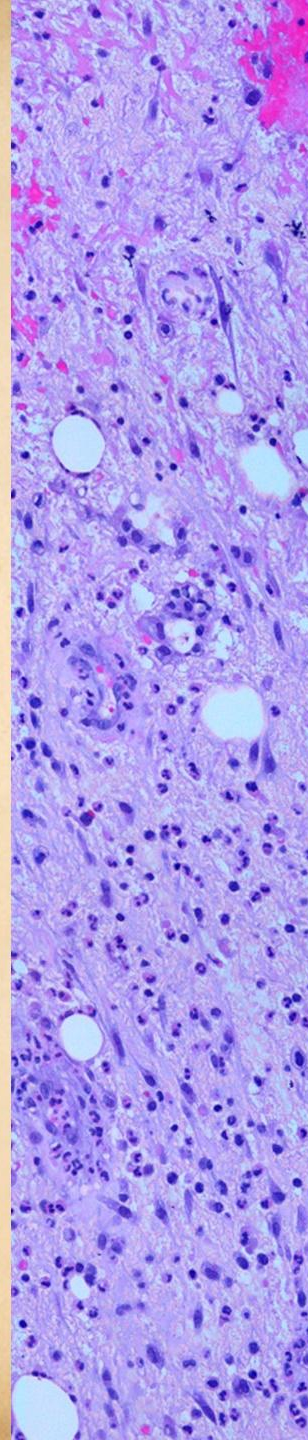
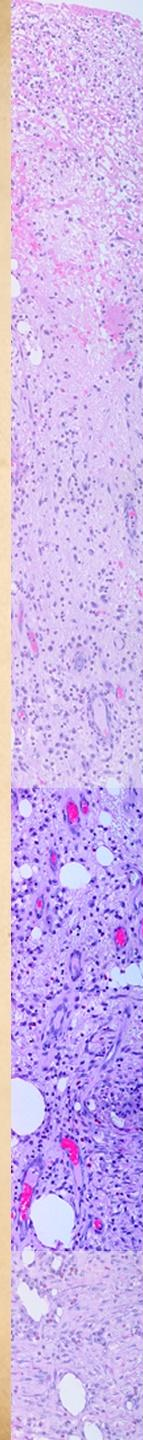
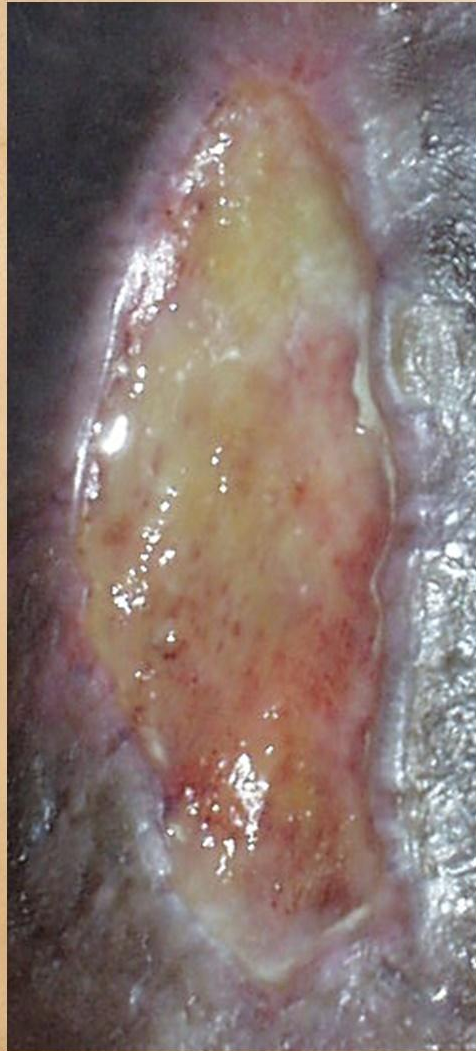
Normal



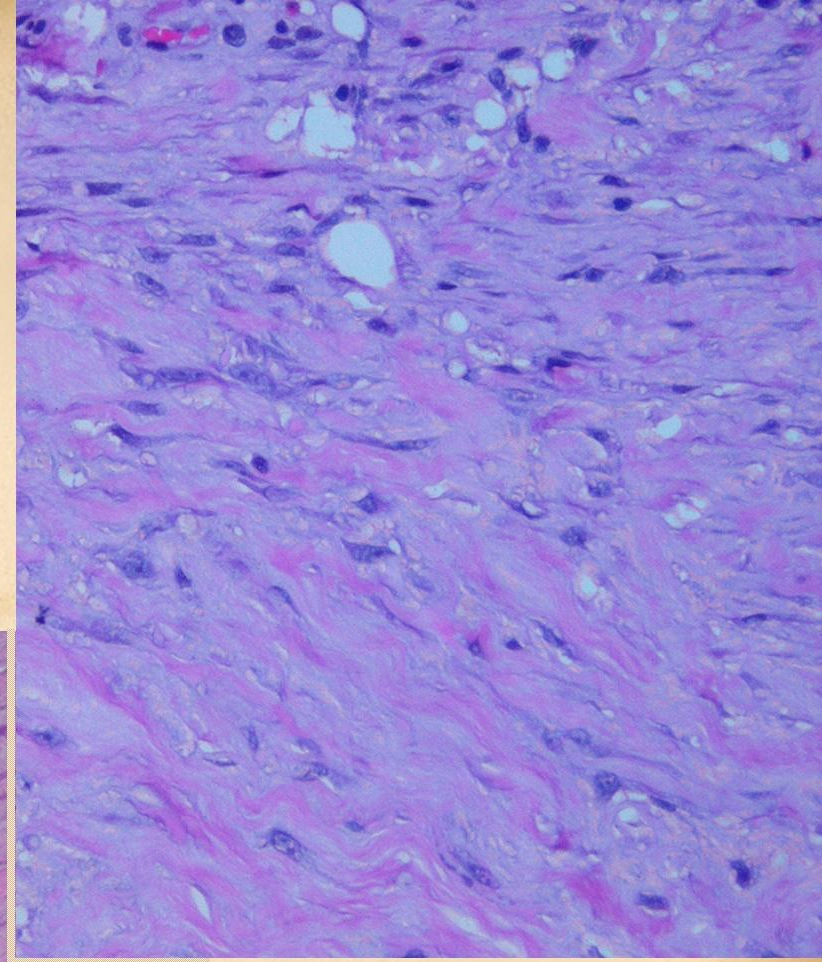
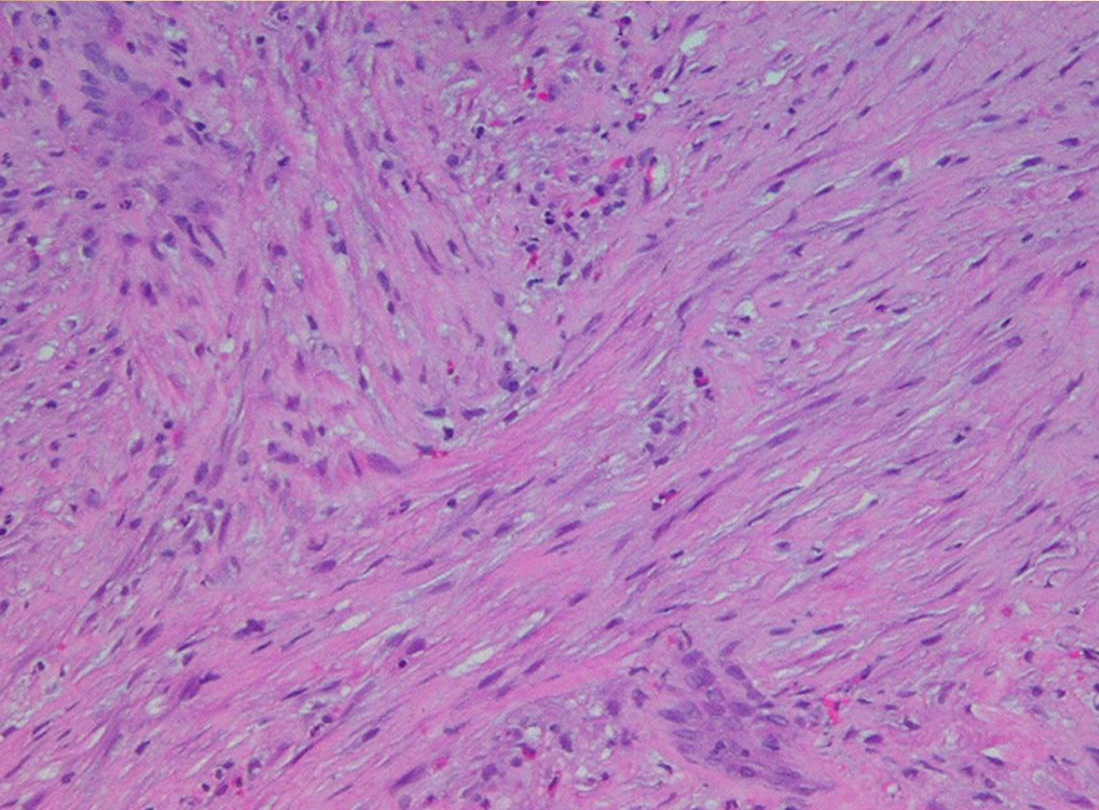
IV b Angiogenesis & Granulation Tissue

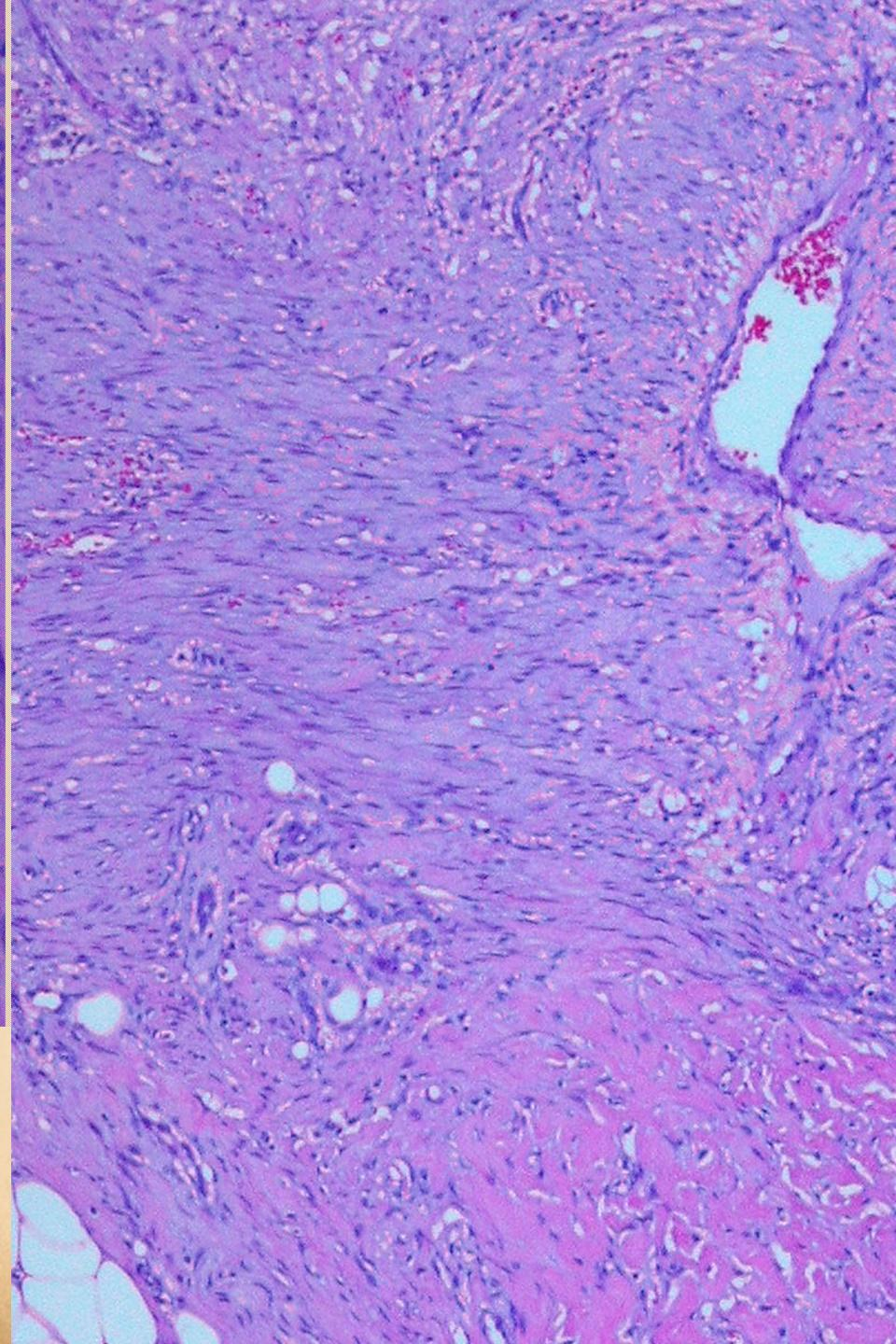
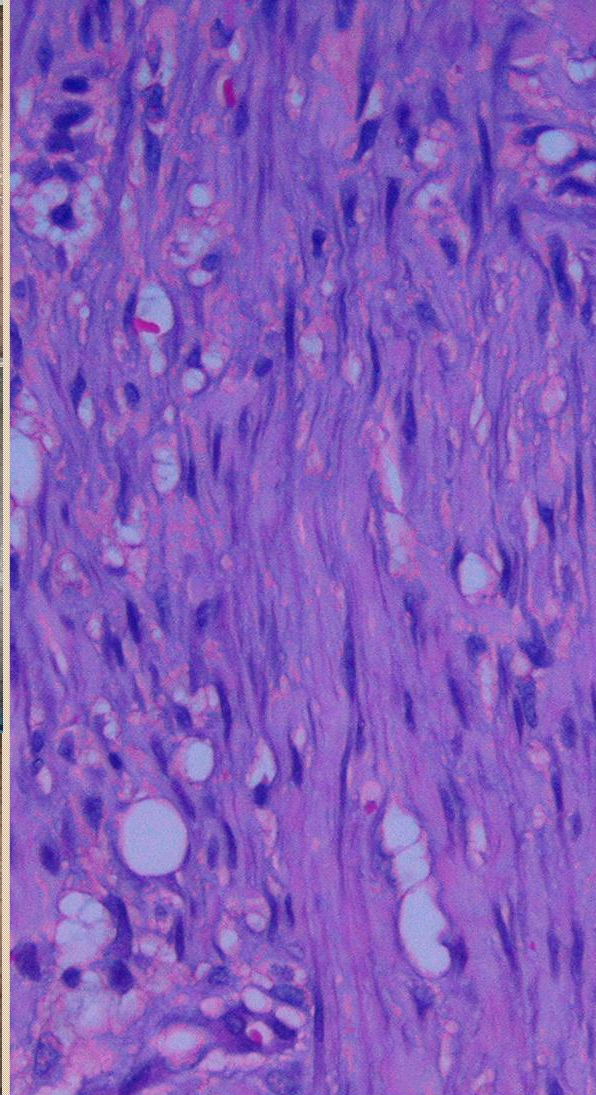
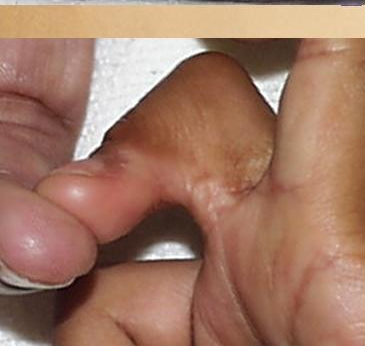
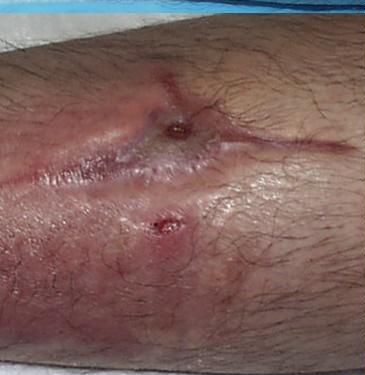
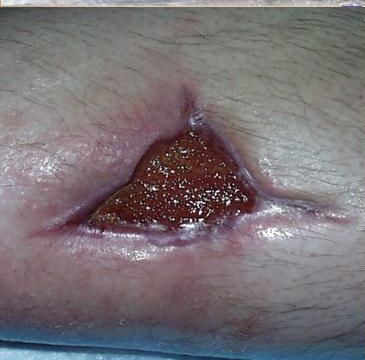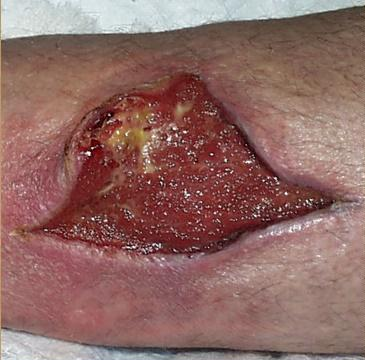V a
Fibroblasts &
Connective Matrix



V b
Fibroplasia & Scar

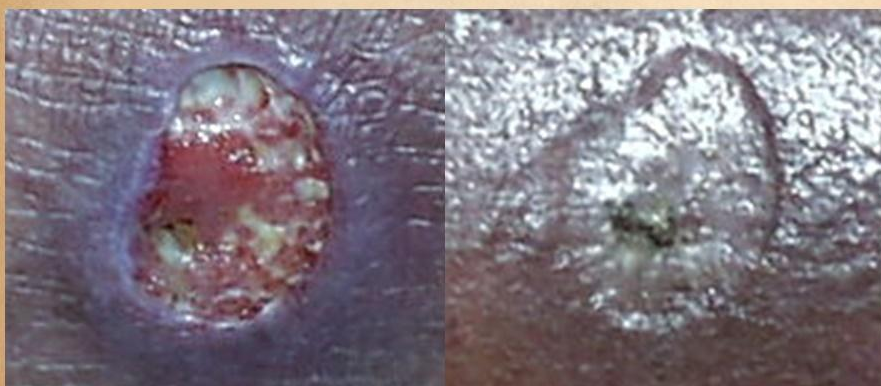
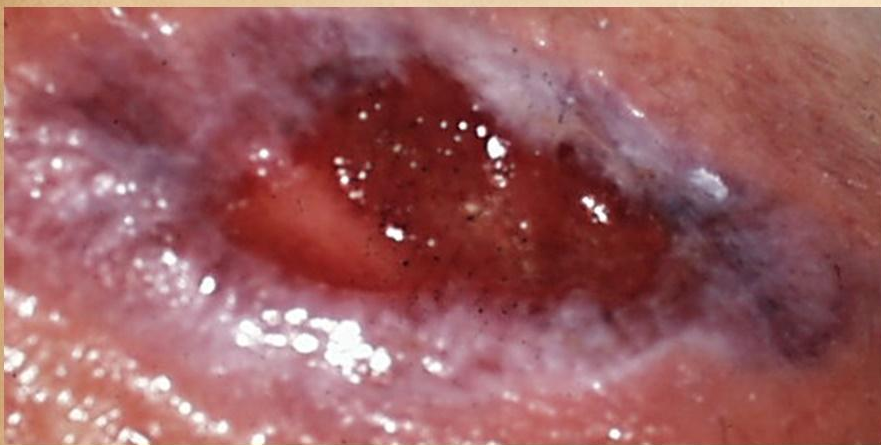
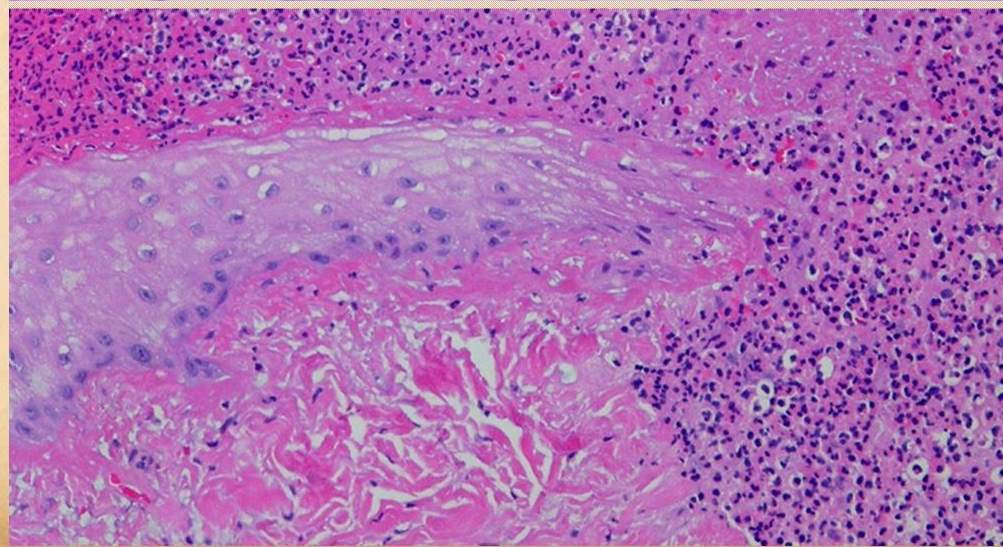
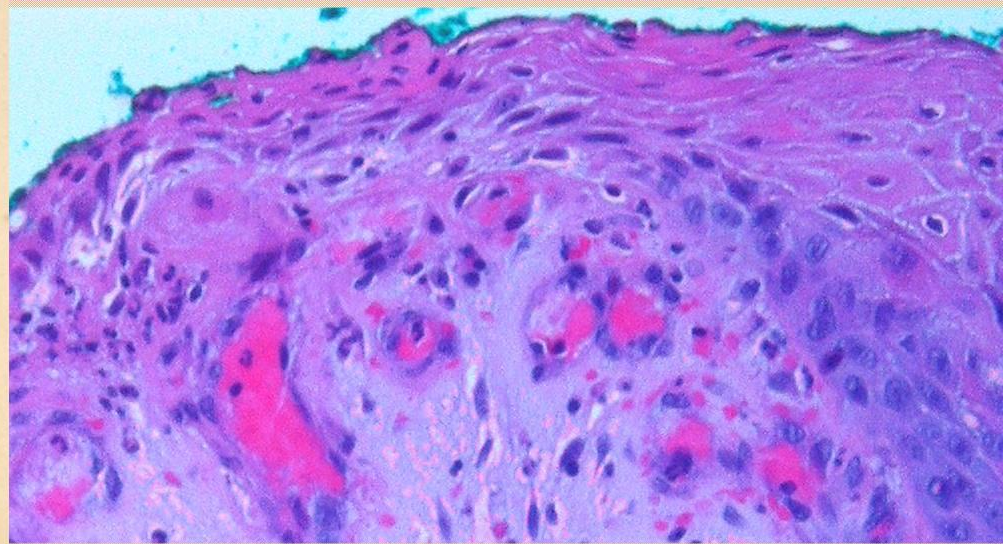
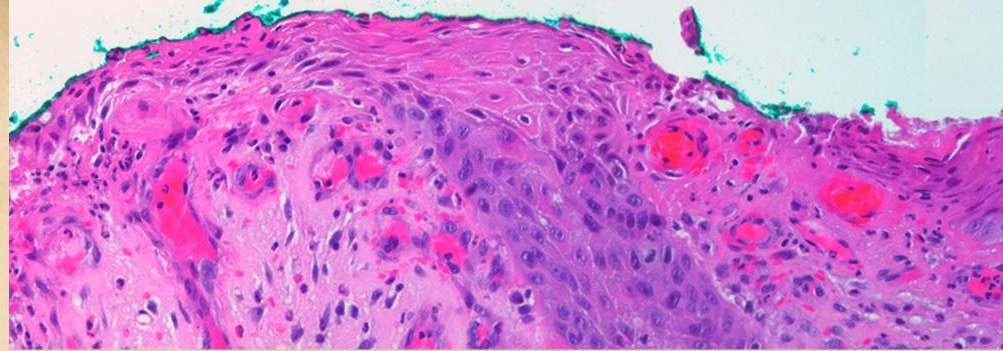




VI
Myofibroblasts &
Contraction

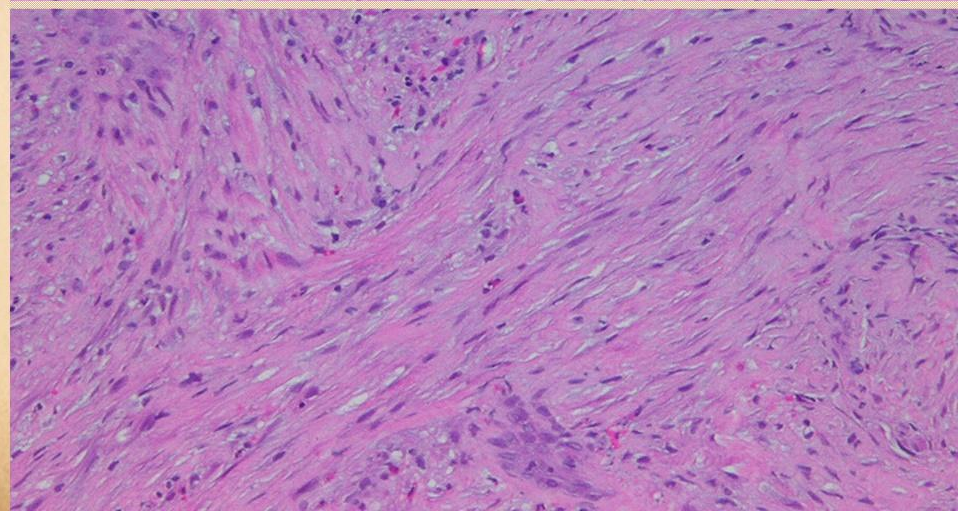
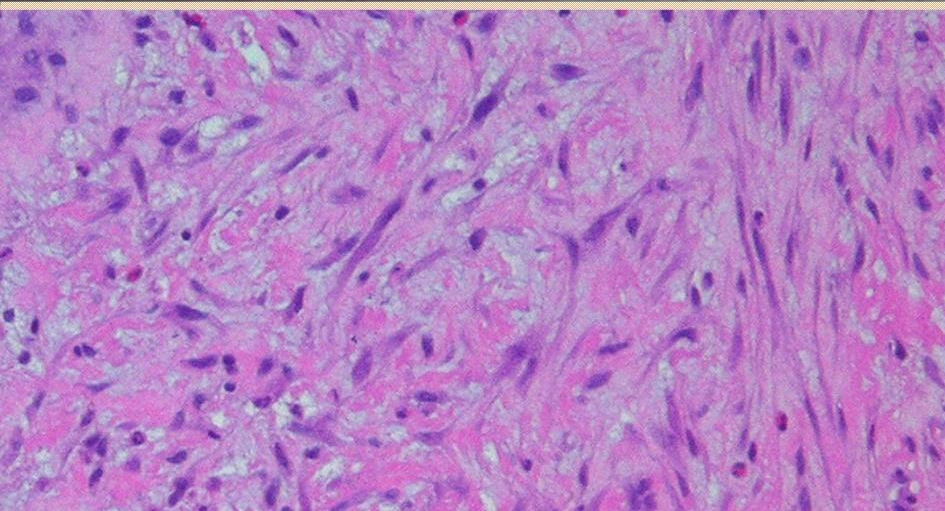
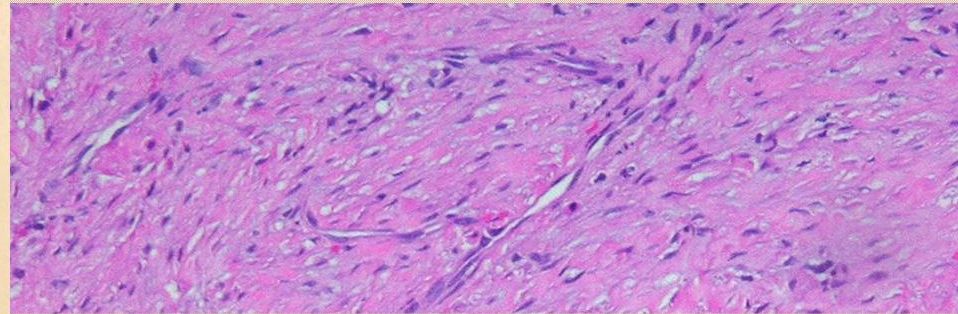
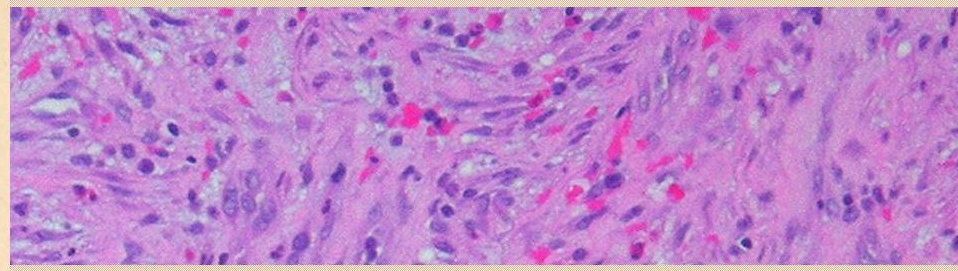
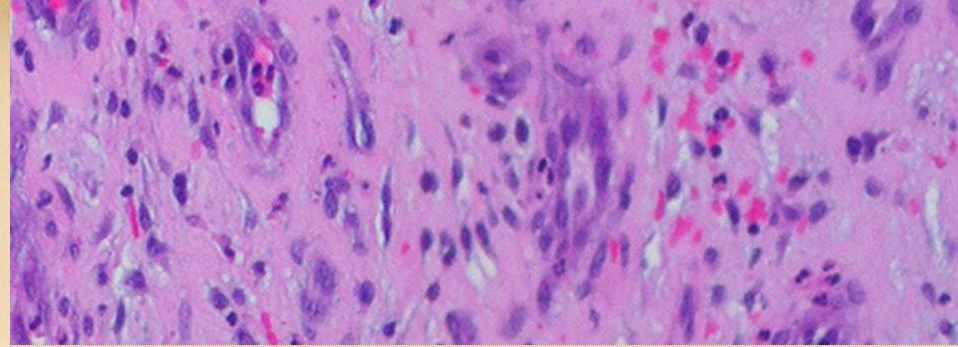
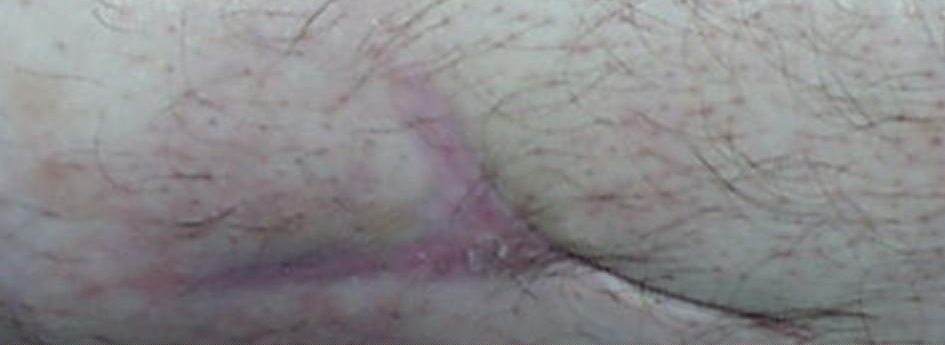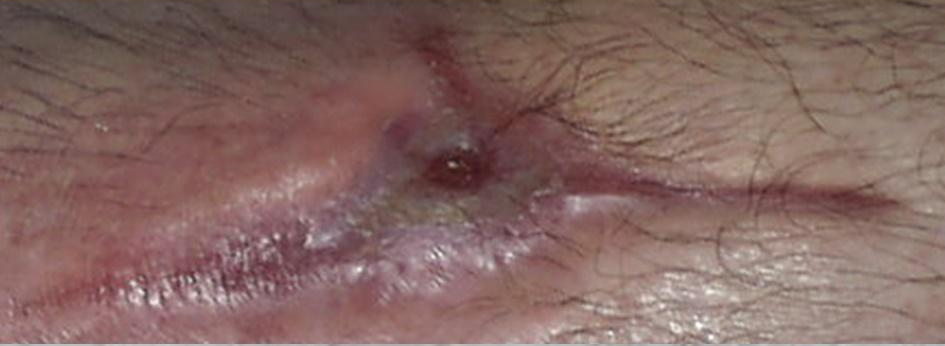VII

Epithelialization & Closure

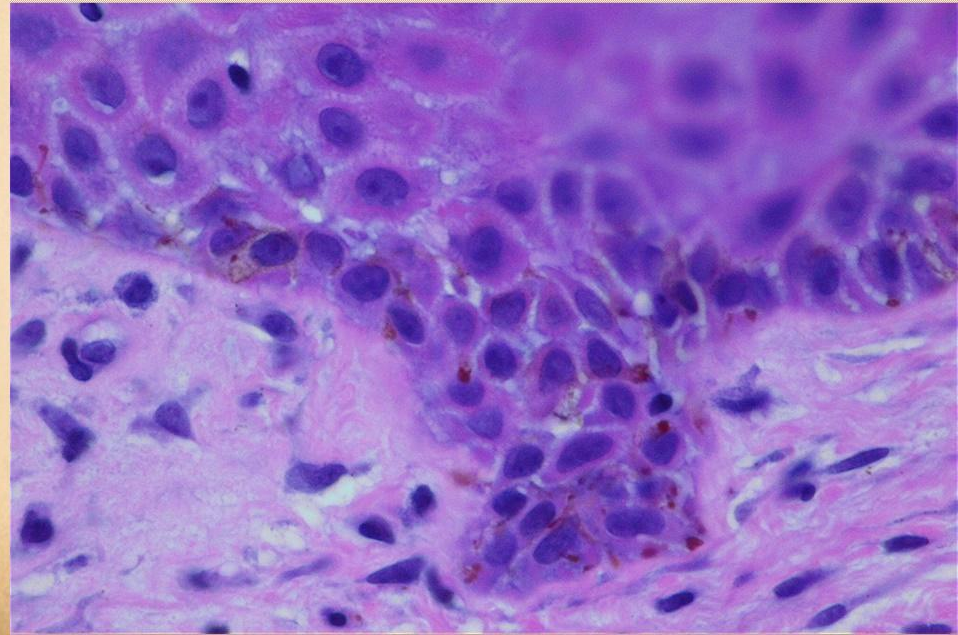
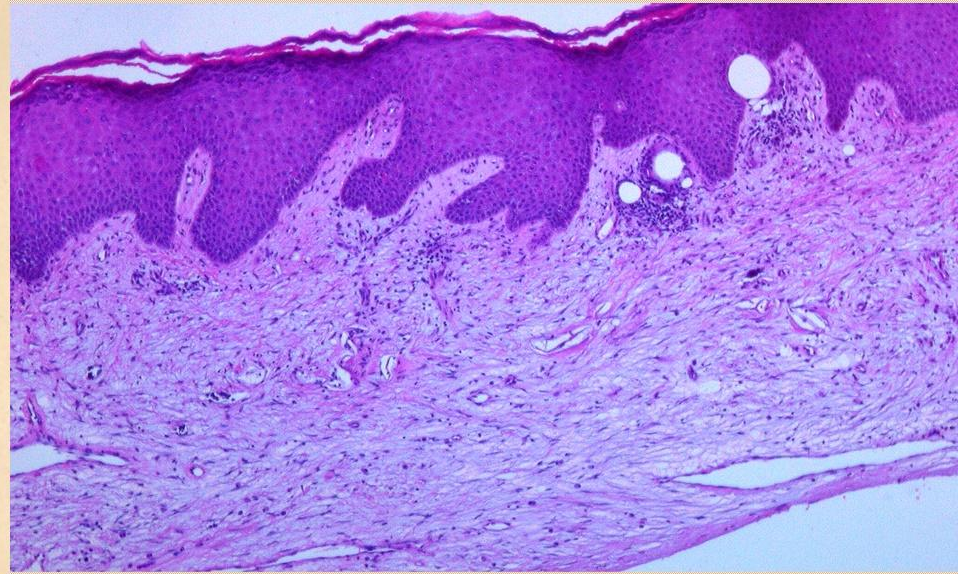
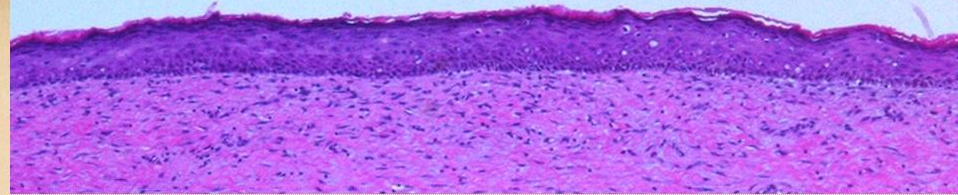
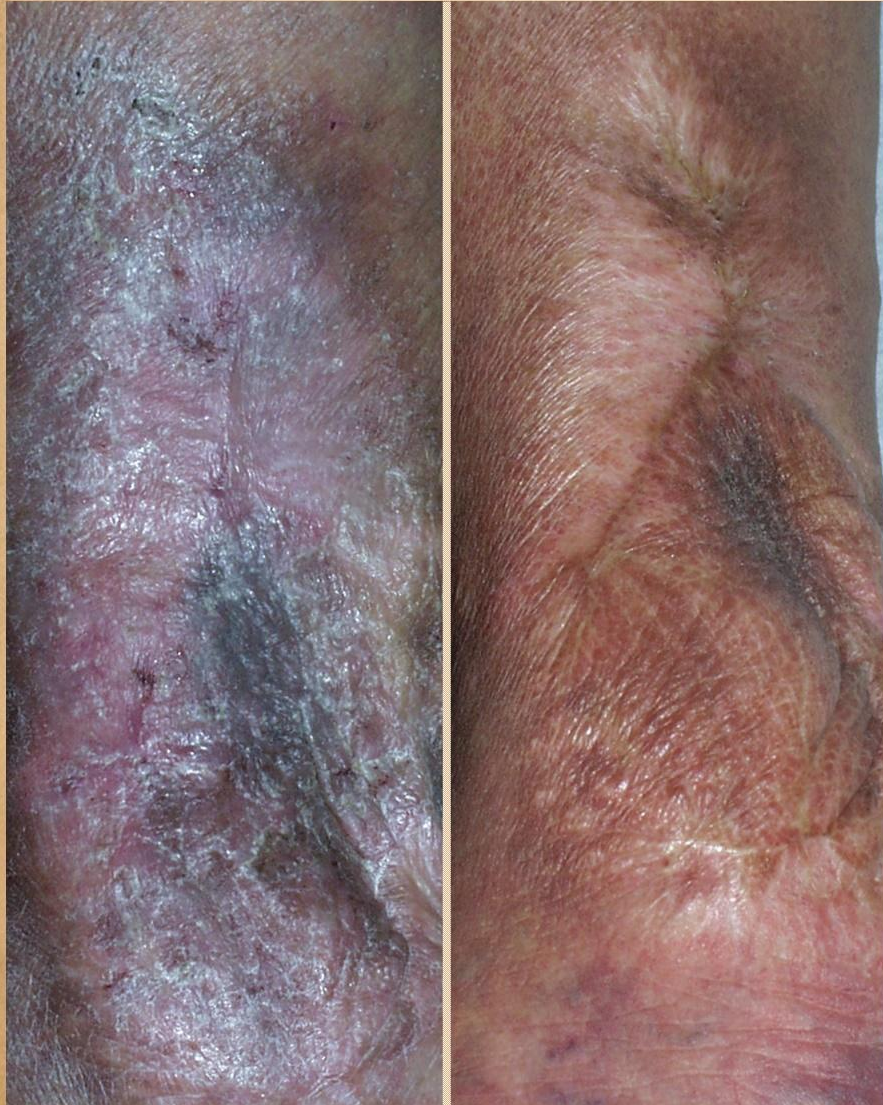

VIII a Maturation

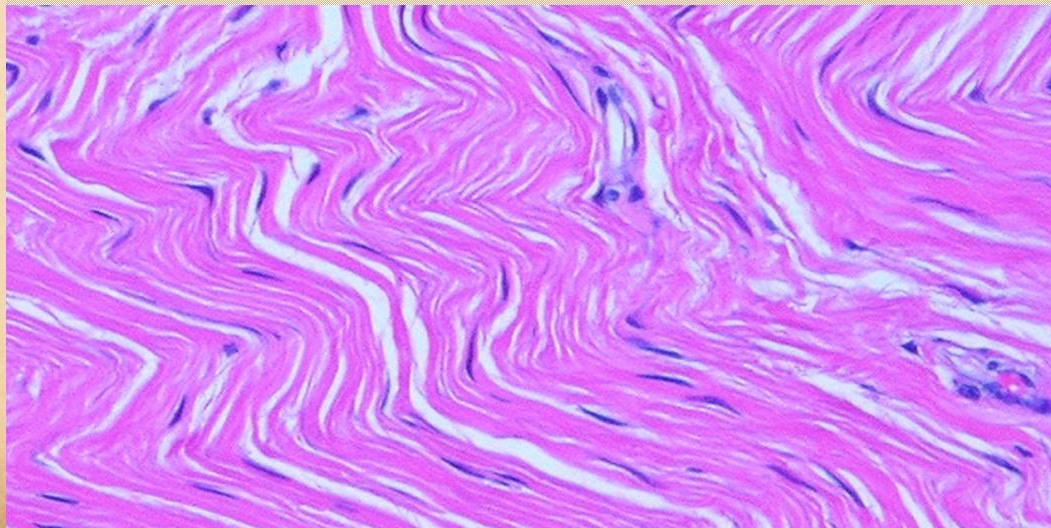
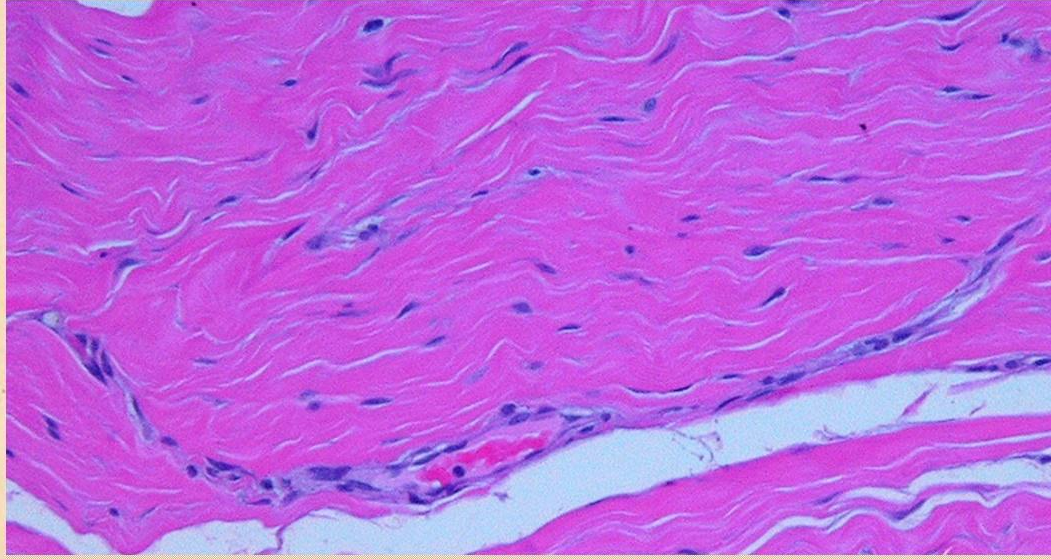
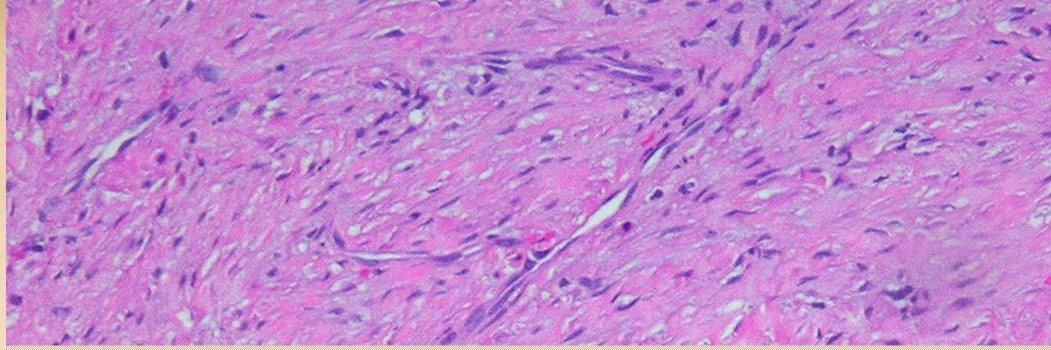
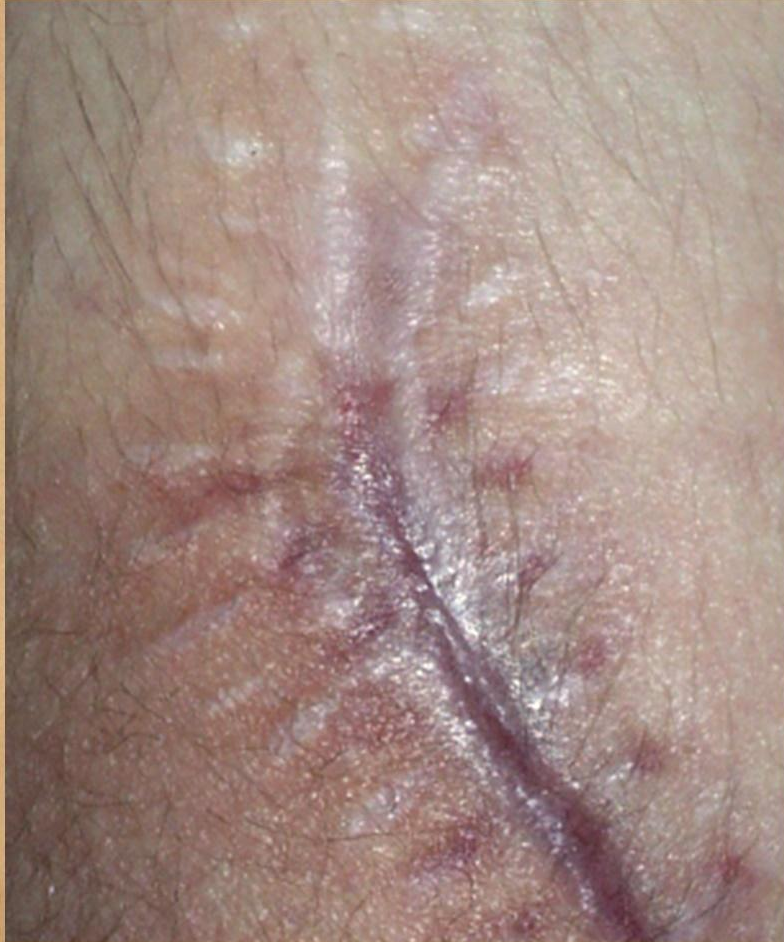Consolidation of fibrous scar



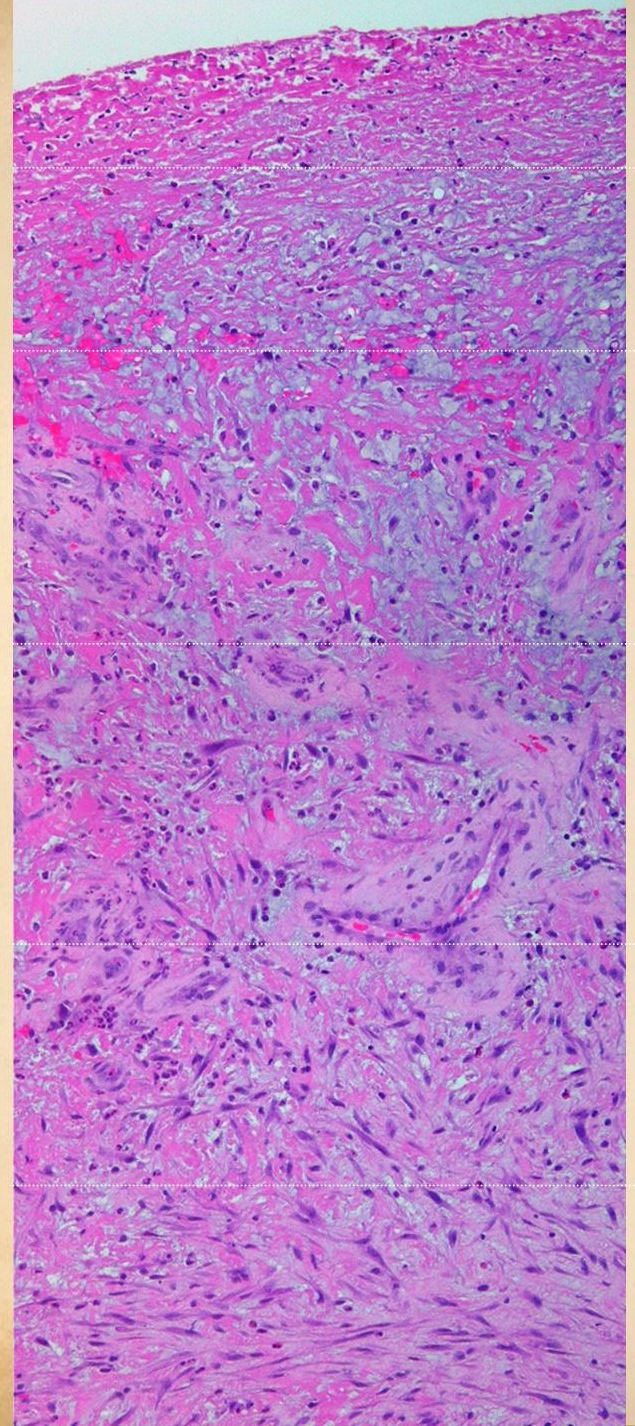
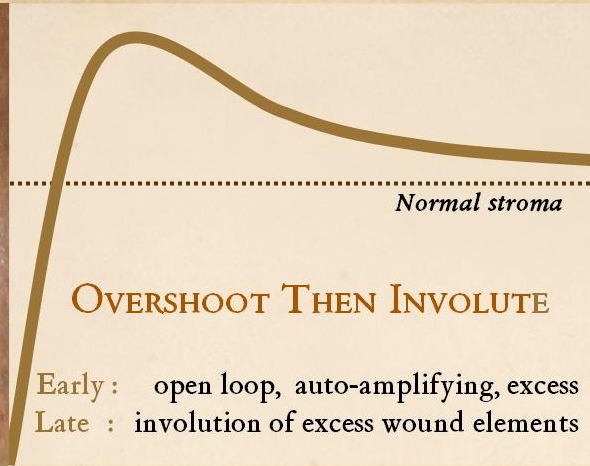
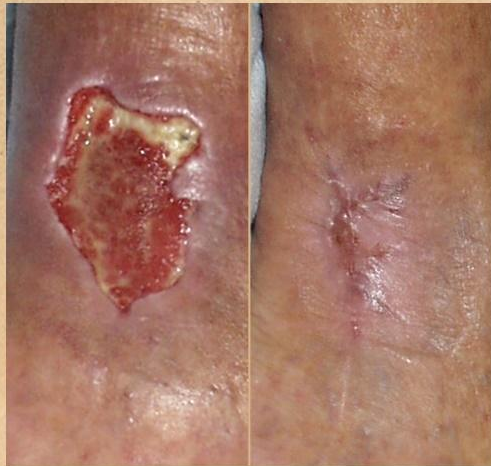VIII b
Maturation
Epidermal papillation



VIII c
Maturation
Involution



Inflammatory Wound Healing



plasma

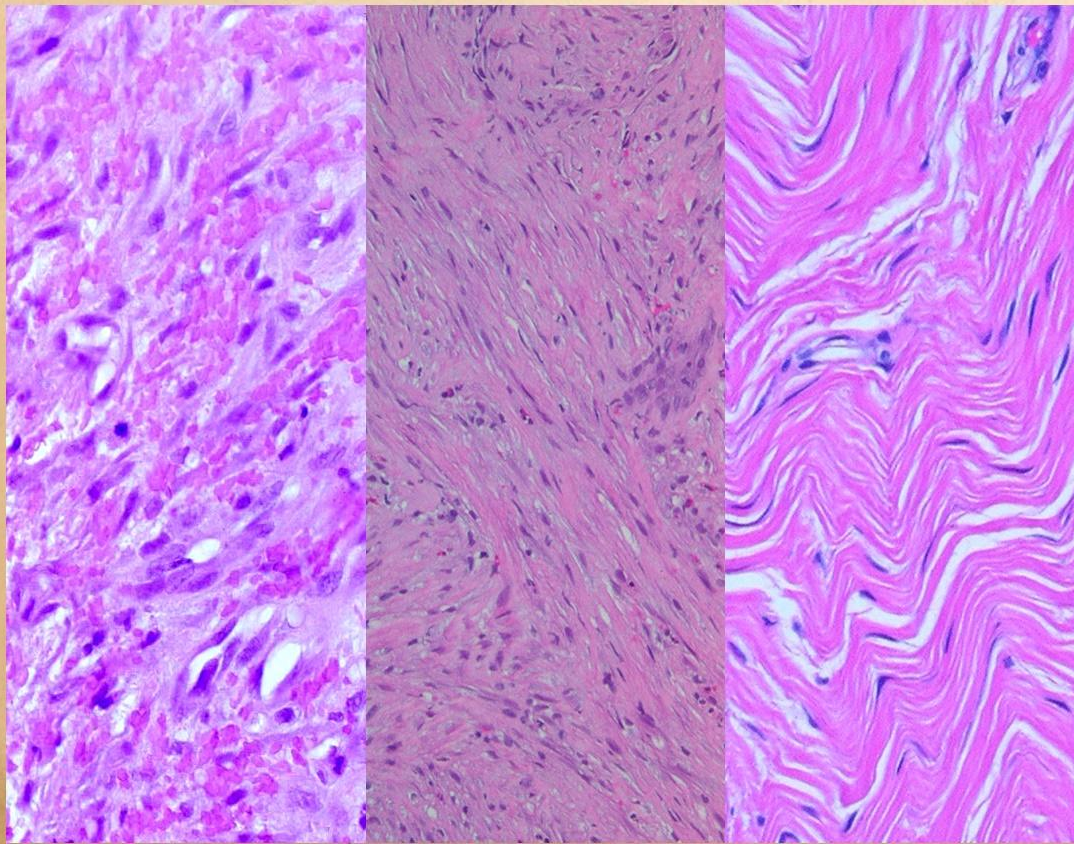
gag's

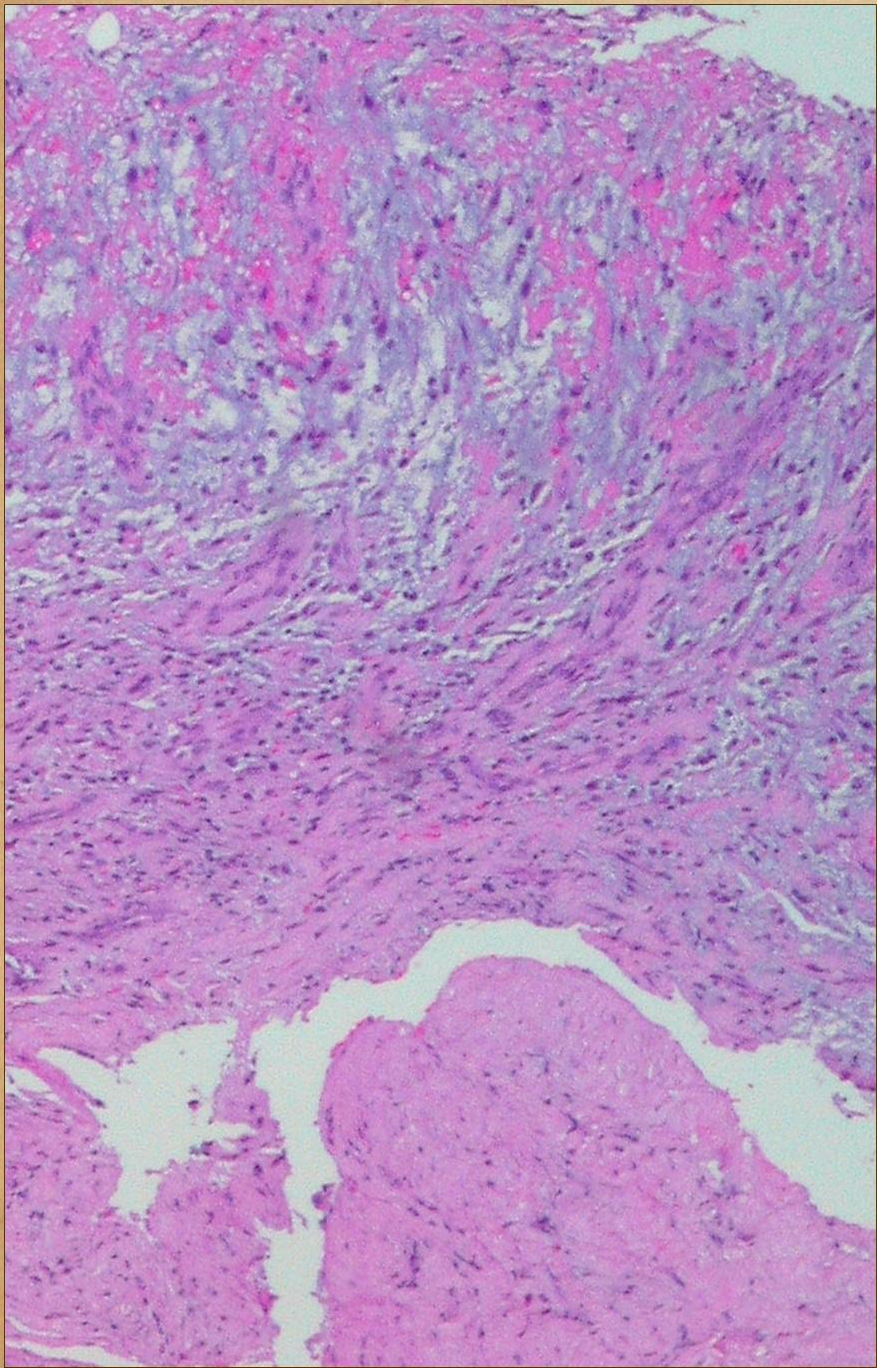
gag's

gag-conn

connective

connective

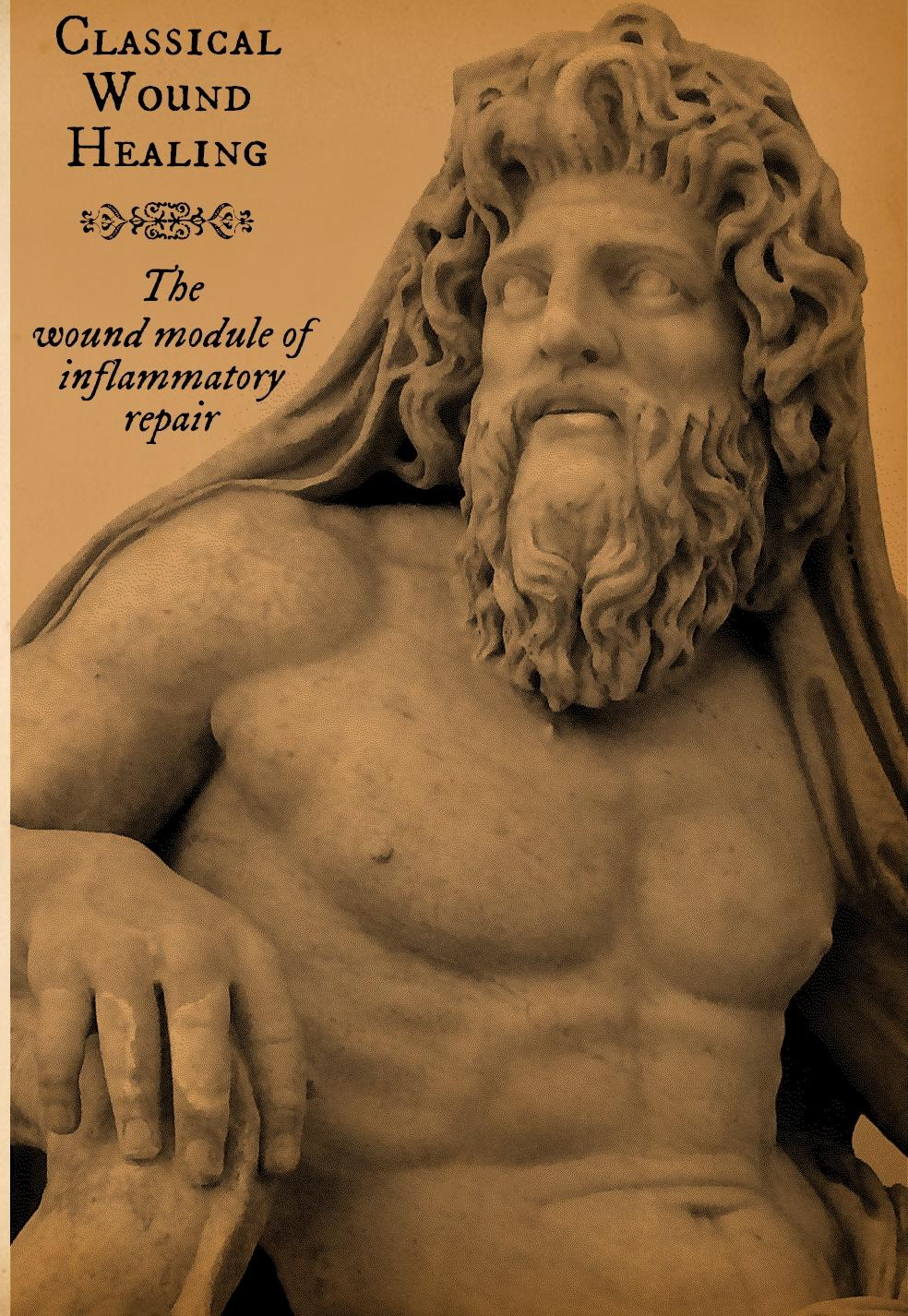





CLASSICAL WOUND HEALING



*The
wound module of
inflammatory
repair*

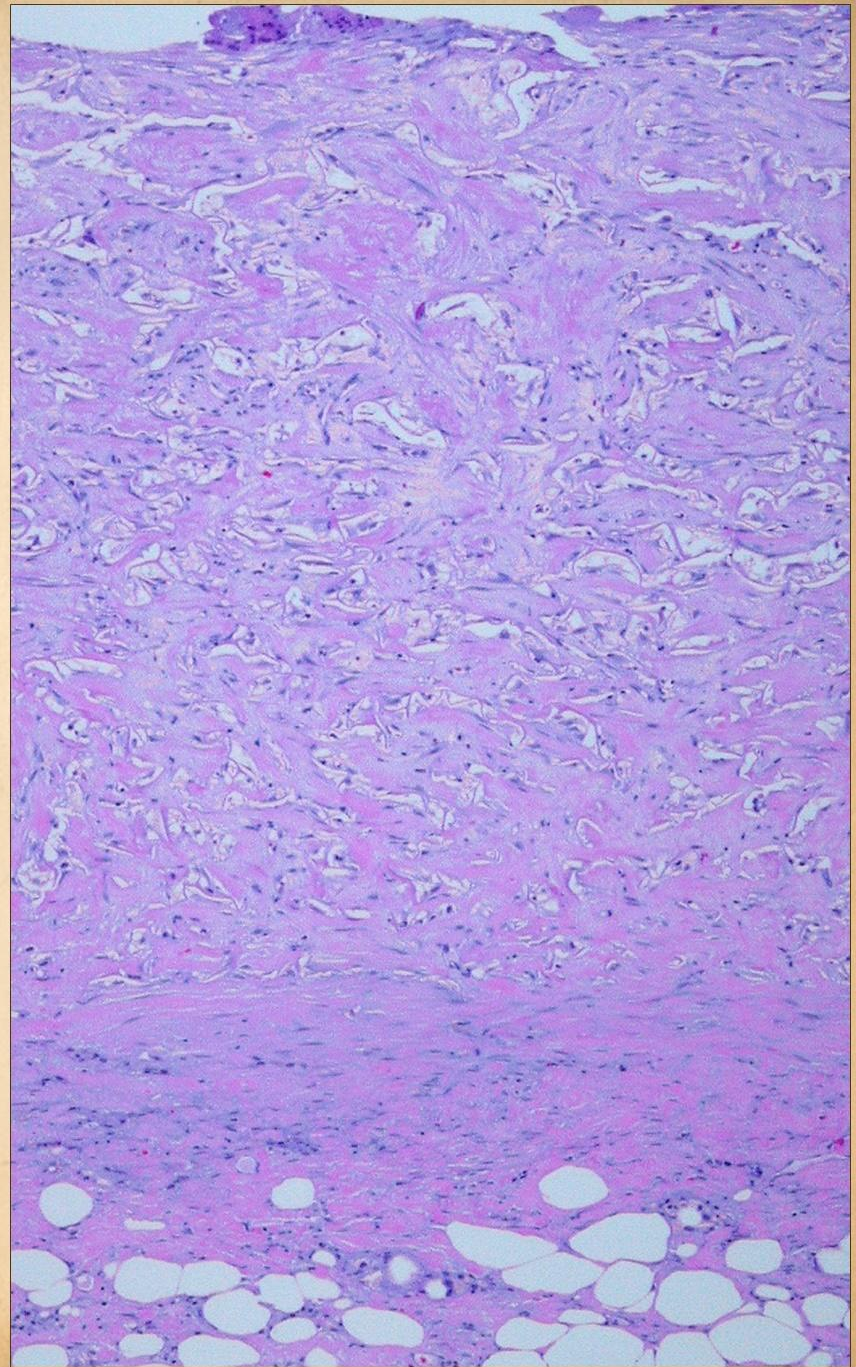


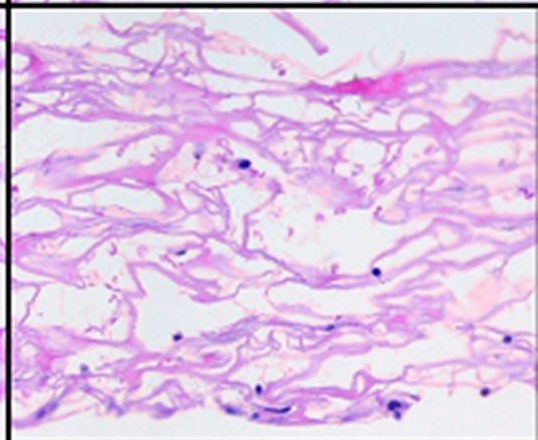
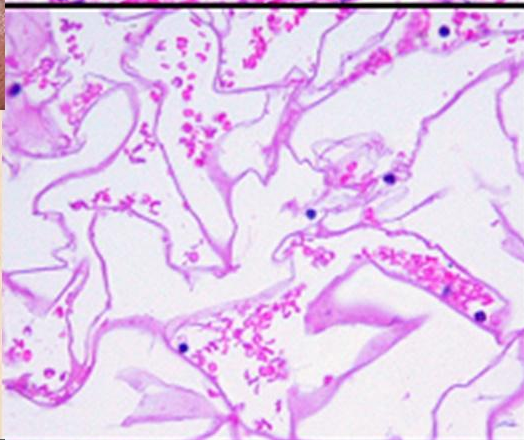
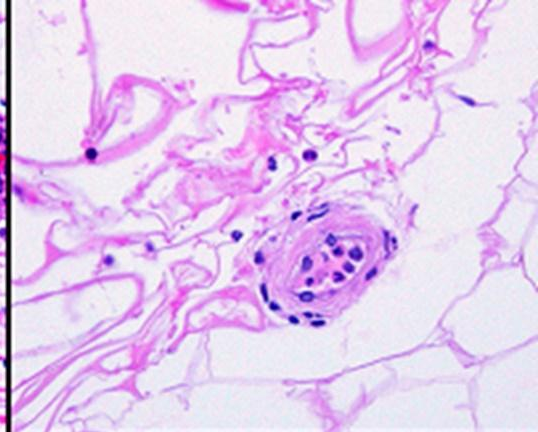
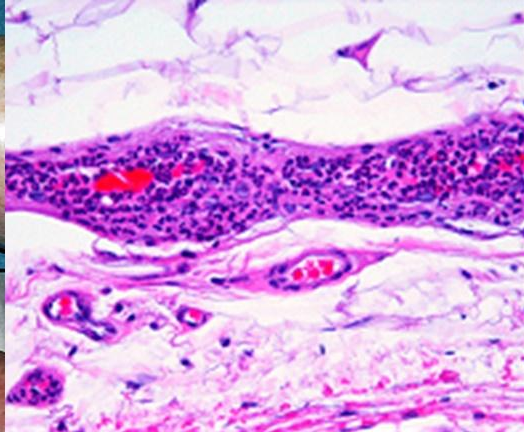
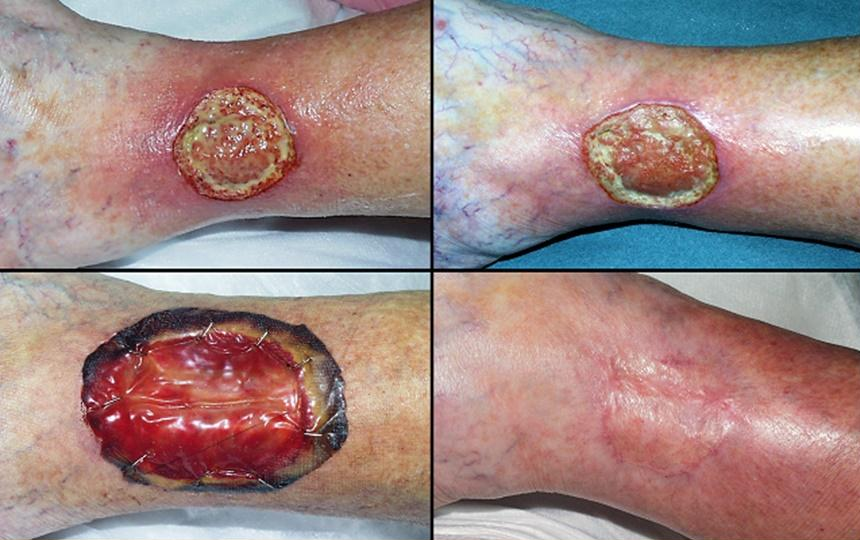

**Matrix
Histogenesis**

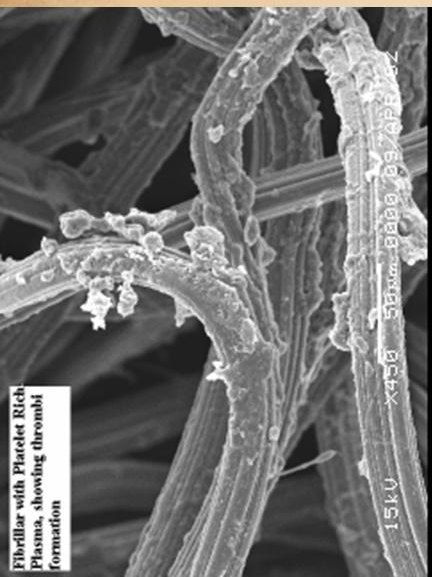


*Embryonic
regeneration*

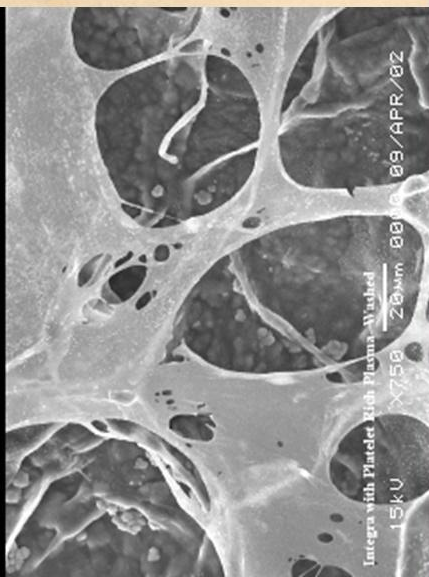




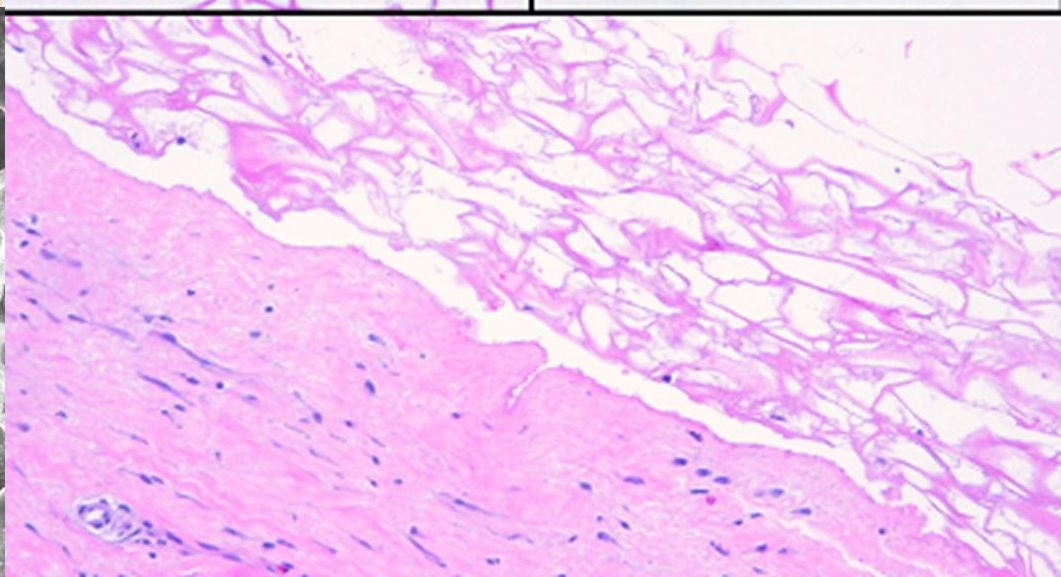
Arrest of inflammation



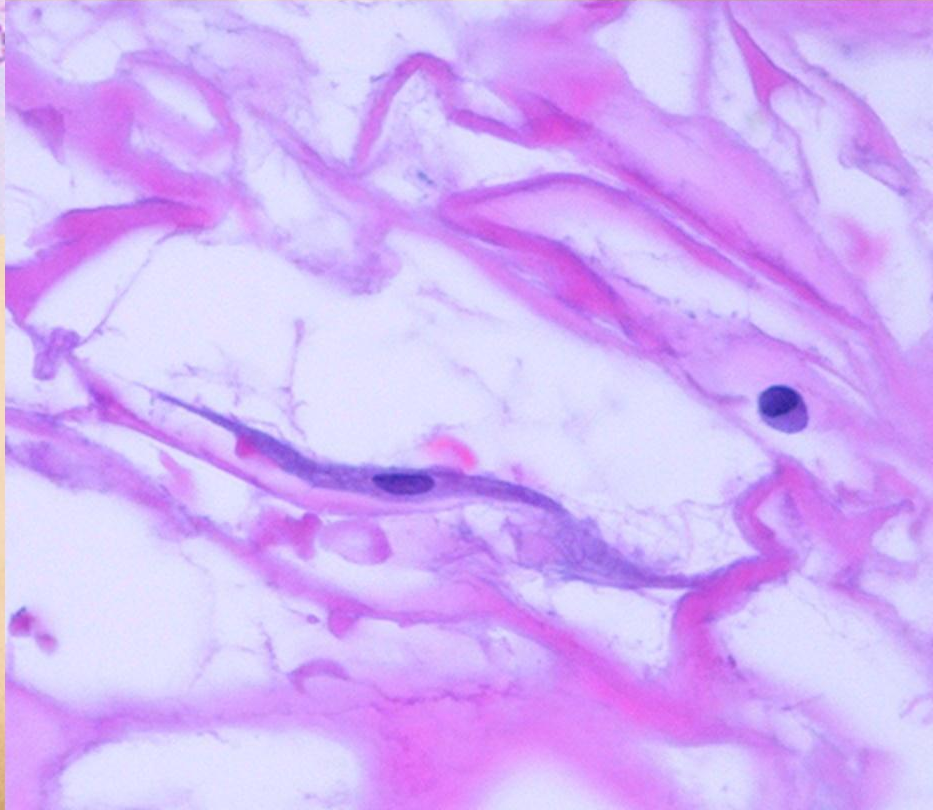
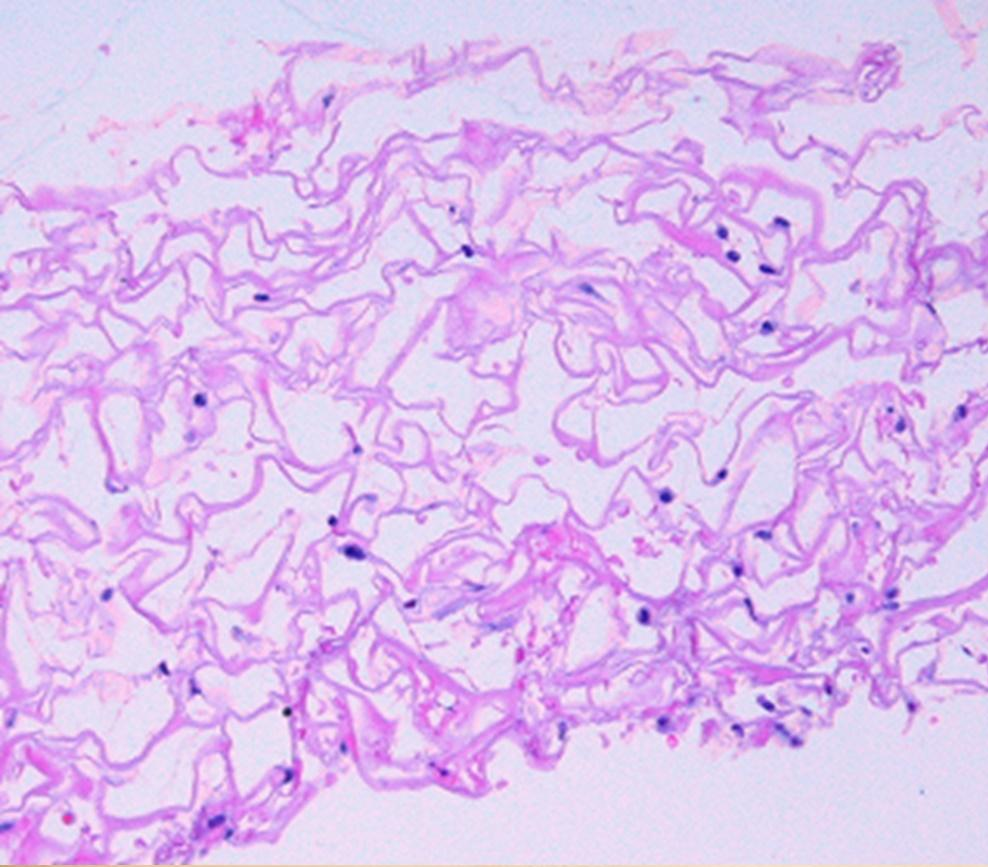
Fibrillar with Platelet Rich Plasma, showing thrombi formation



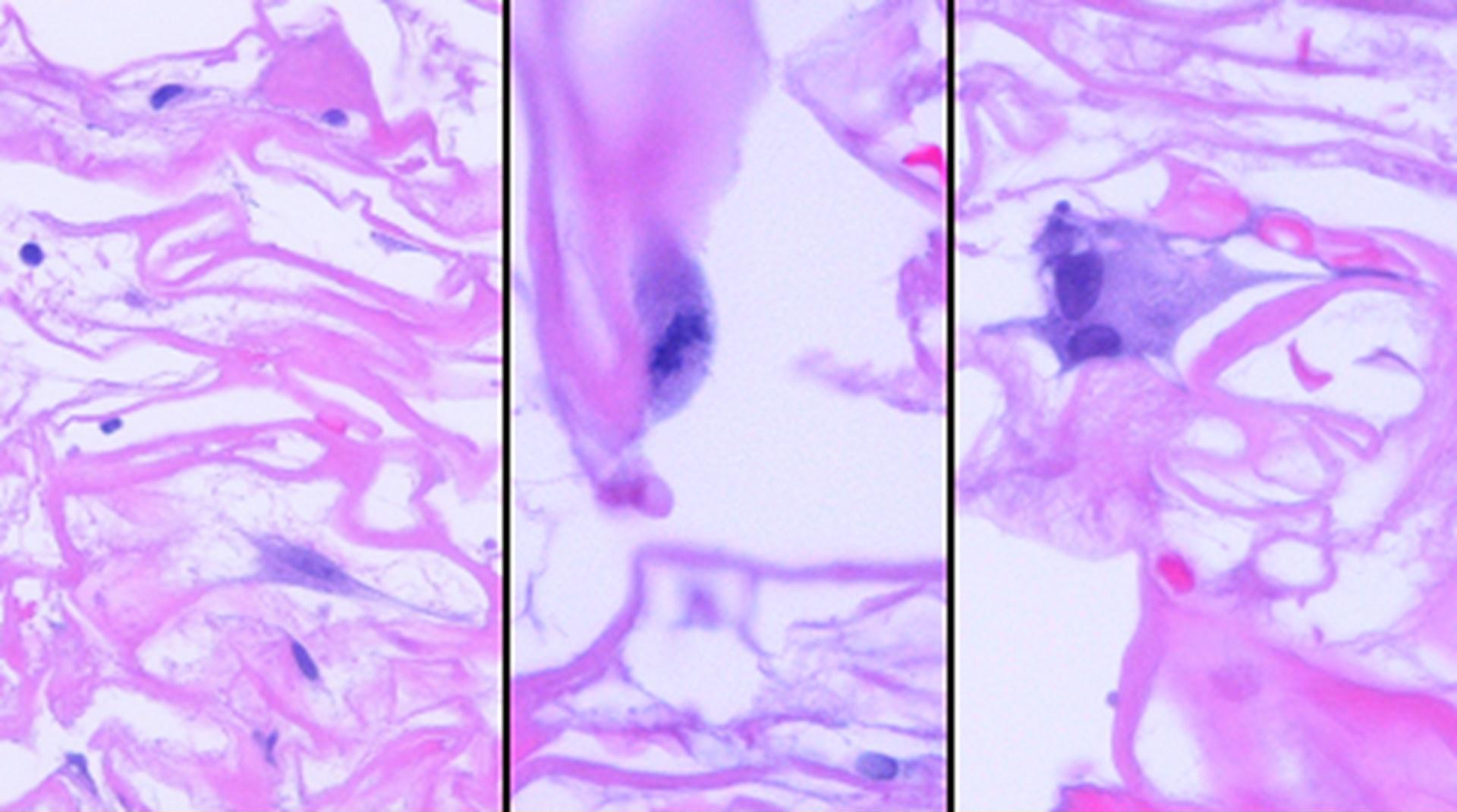
Integra with Platelet Rich Plasma, Washed



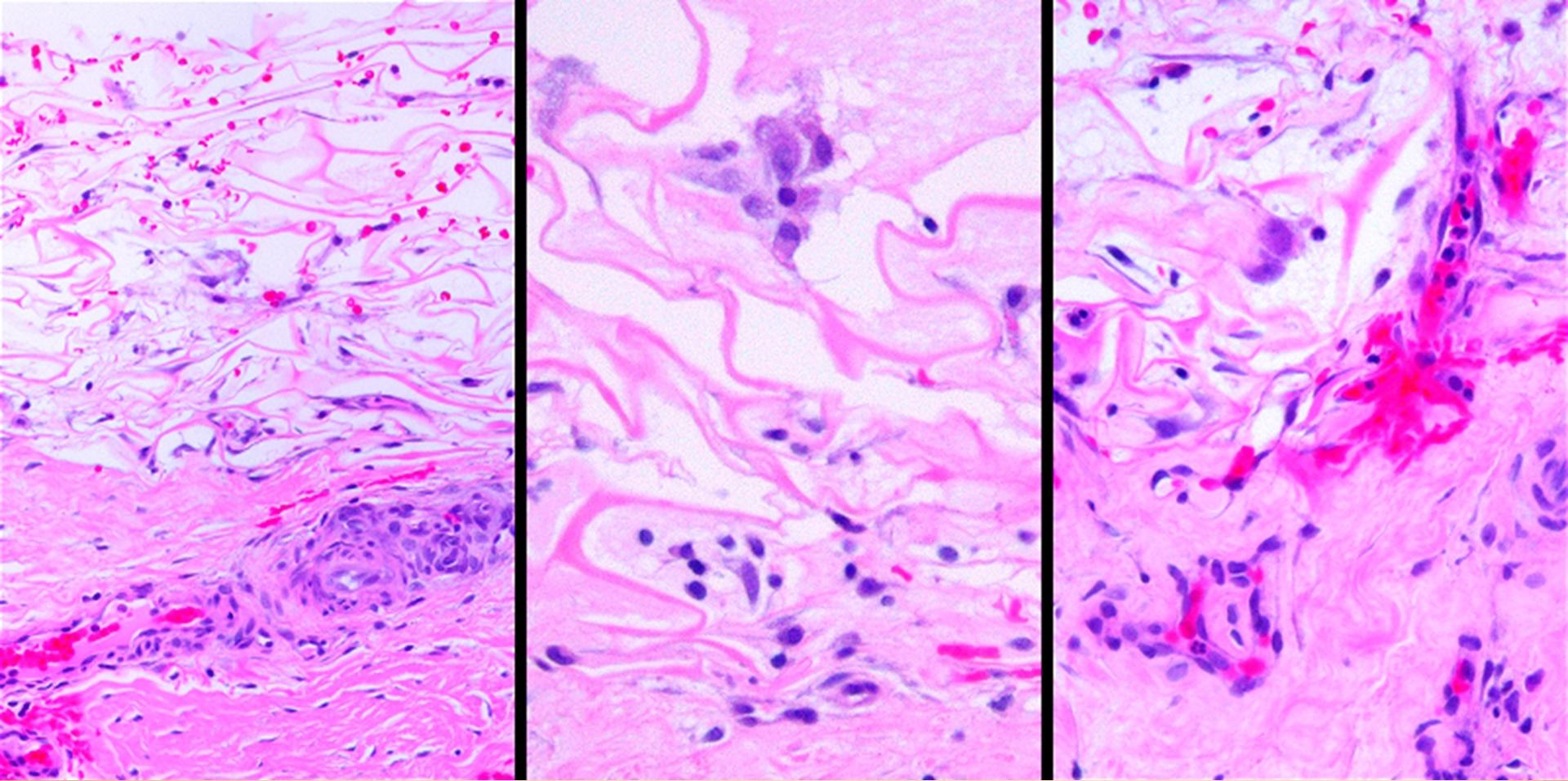
**Recognition of the matrix,
pioneer cells**



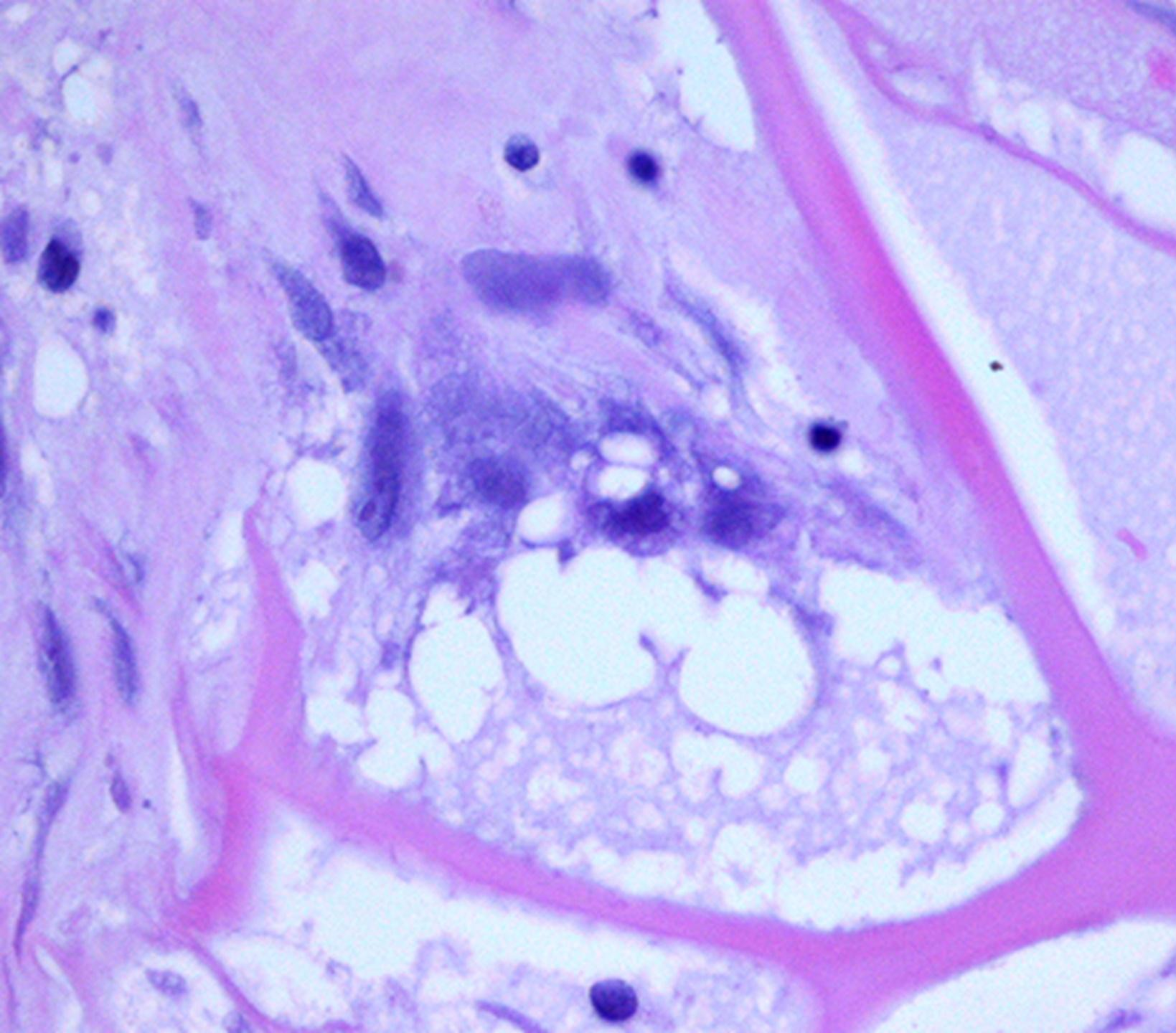
Transition



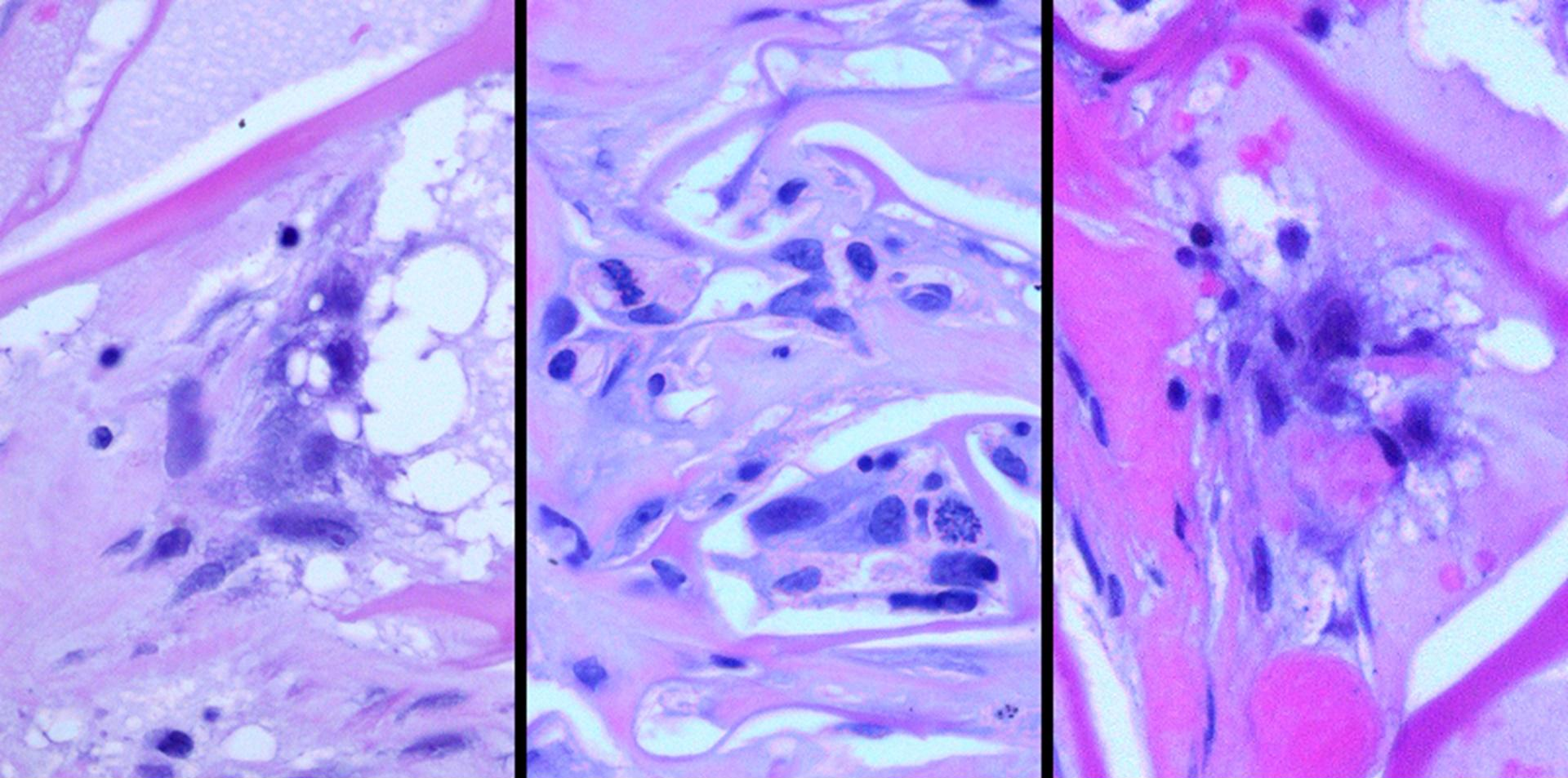
Syncytial transformation



Syncytial transformation

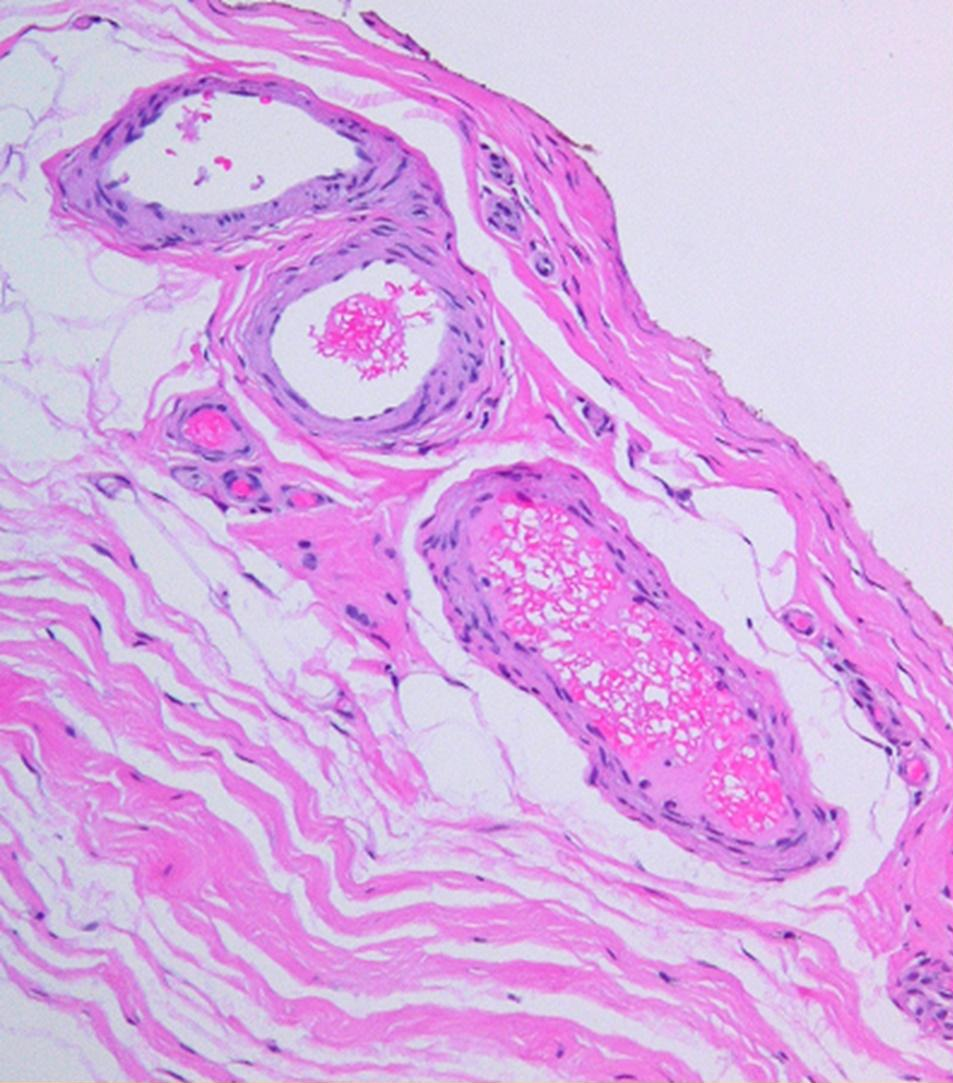


**Syncytial
clusters**

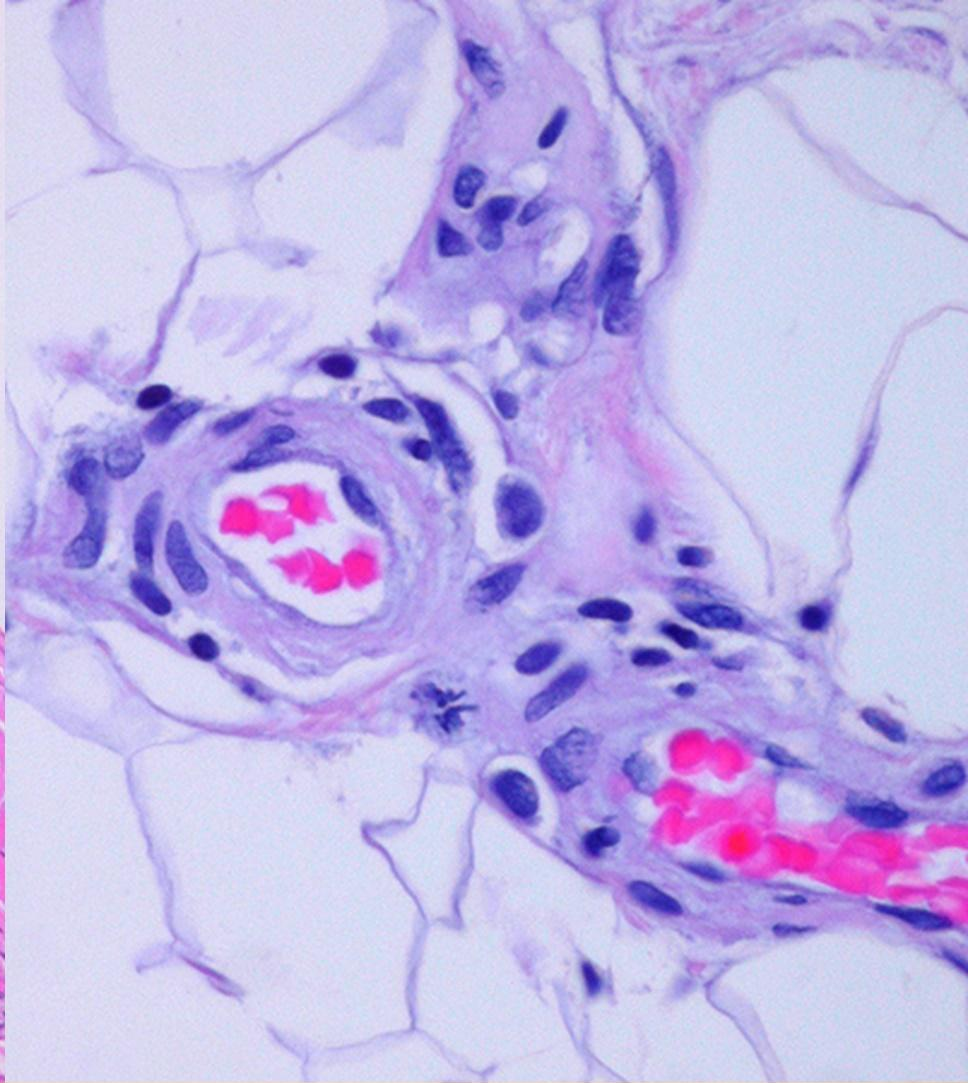


Syncytial clusters

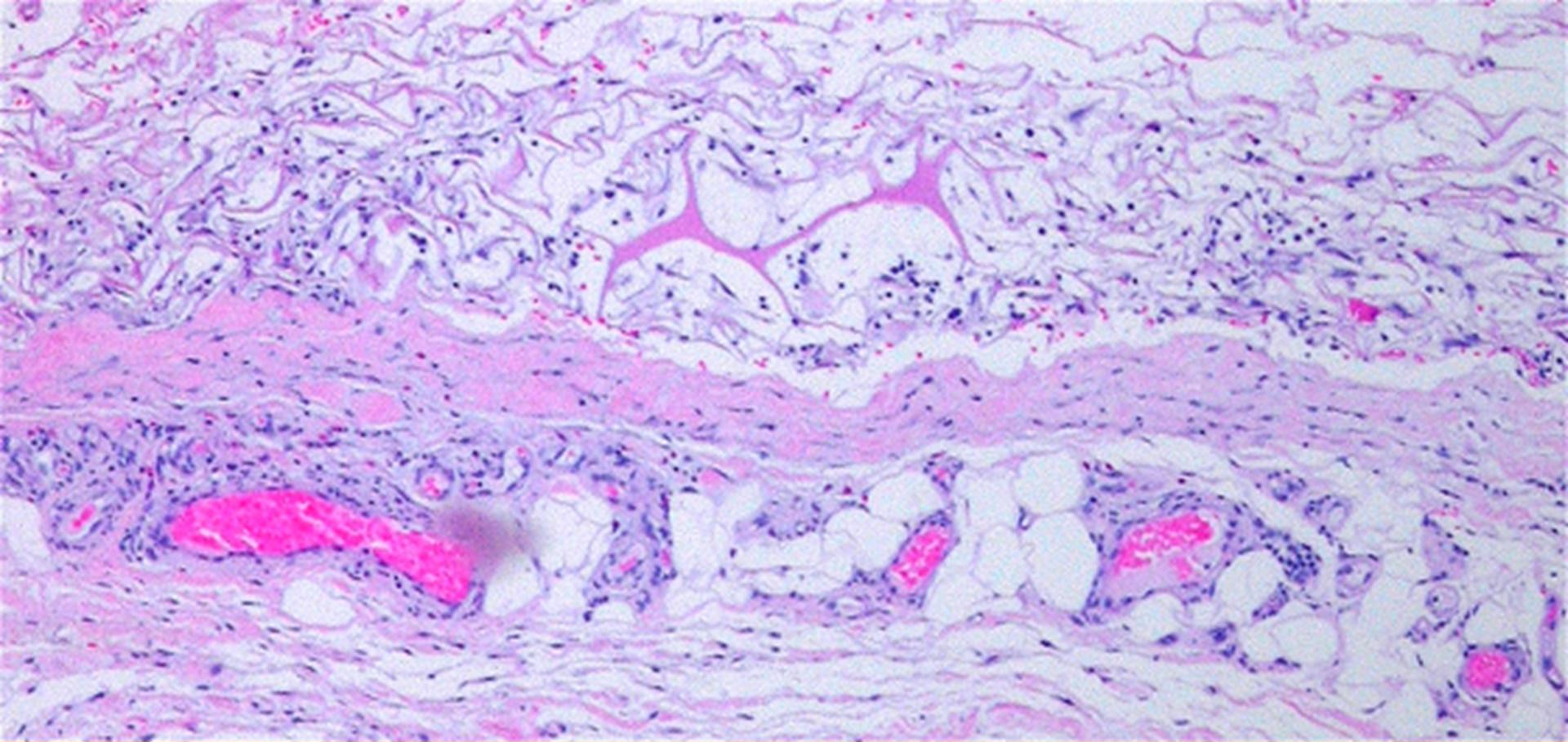
Holbrook KA, Smith LT: Ultrastructural aspects of human skin during the embryonic, fetal, premature, neonatal, and adult periods of life. *Birth Defects* 17: 9-38, 1981.



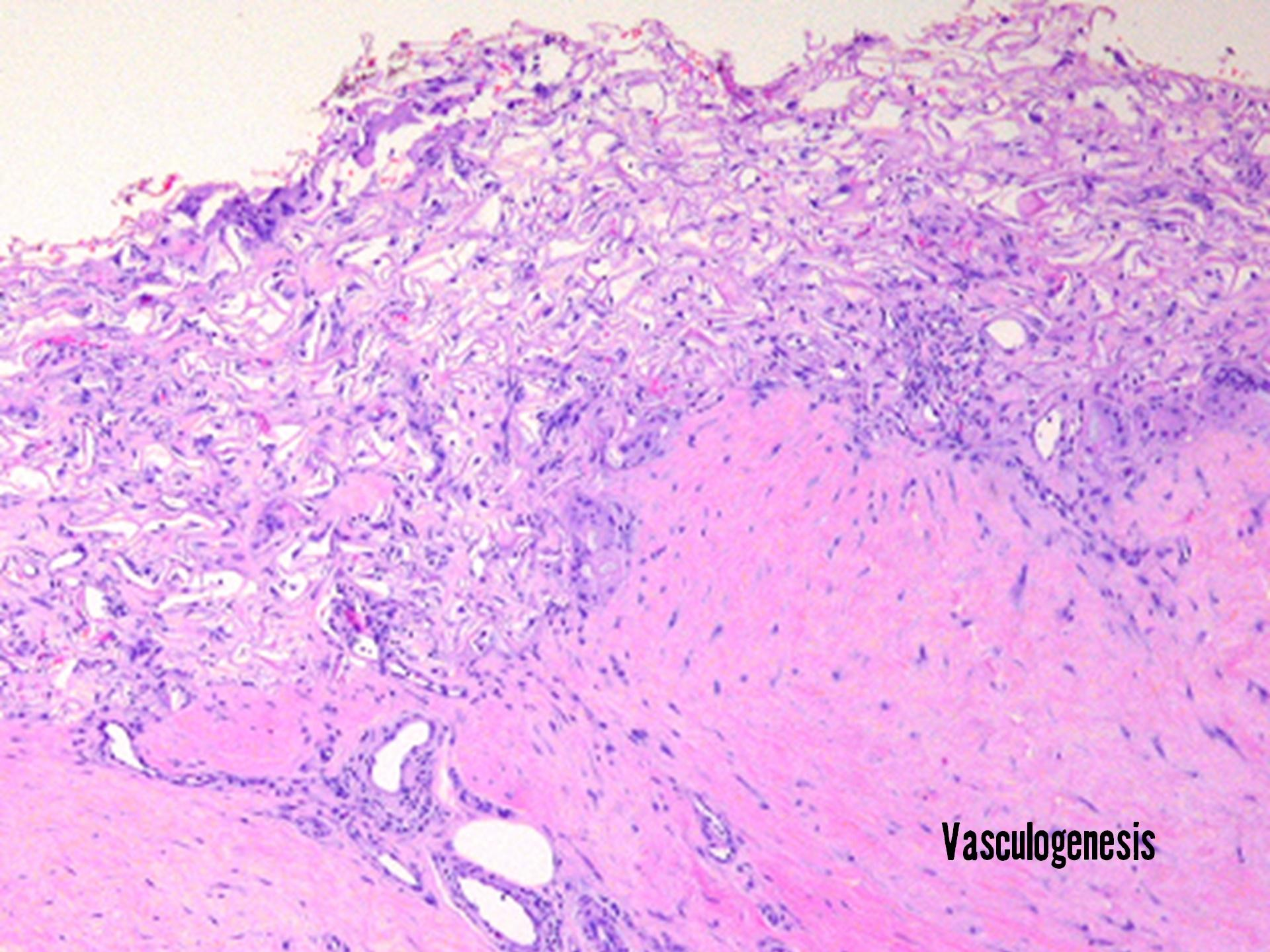
Normal angiocytes prior to Integra



Stimulation of perivascular cells

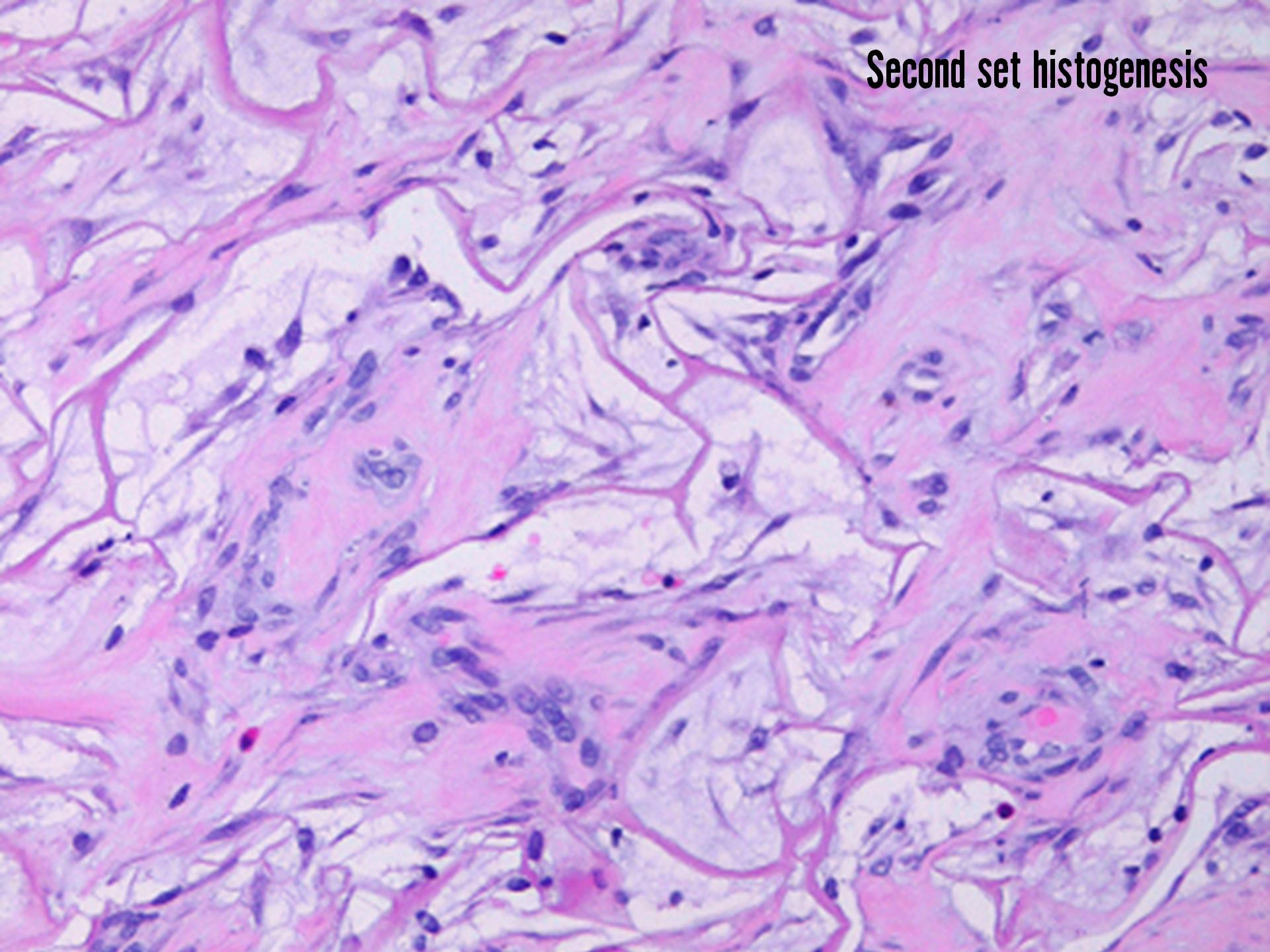


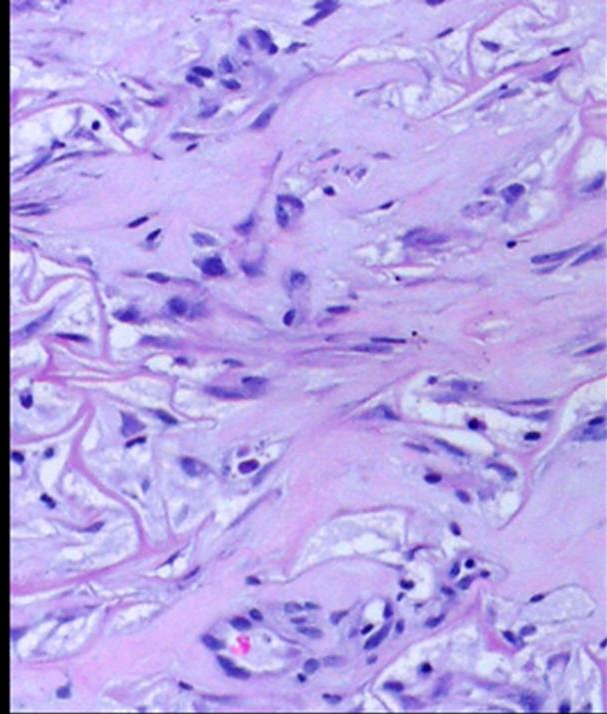
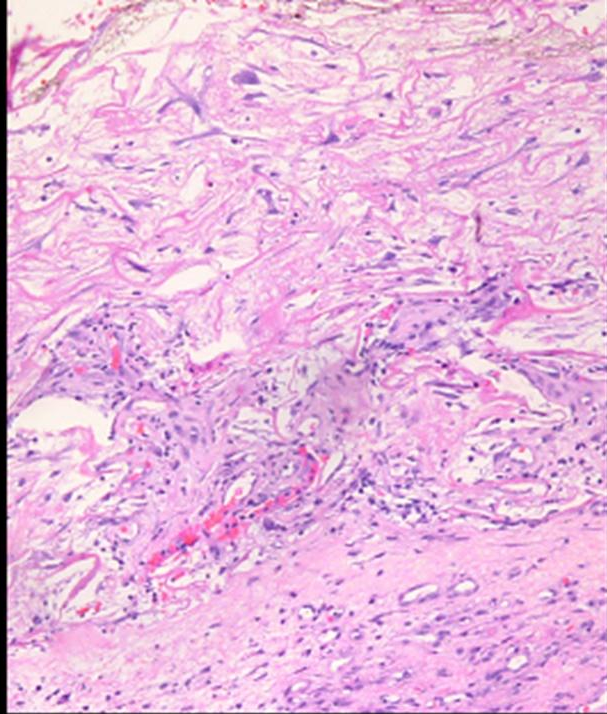
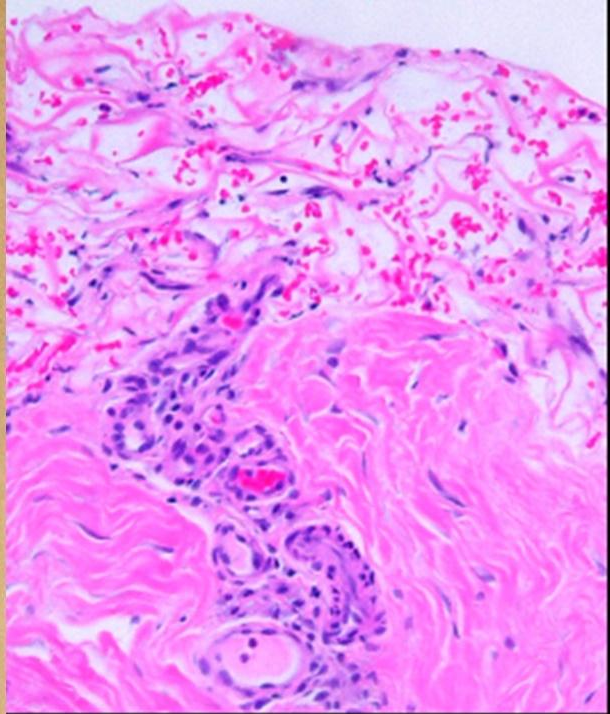
Entrainment of perivascular cells



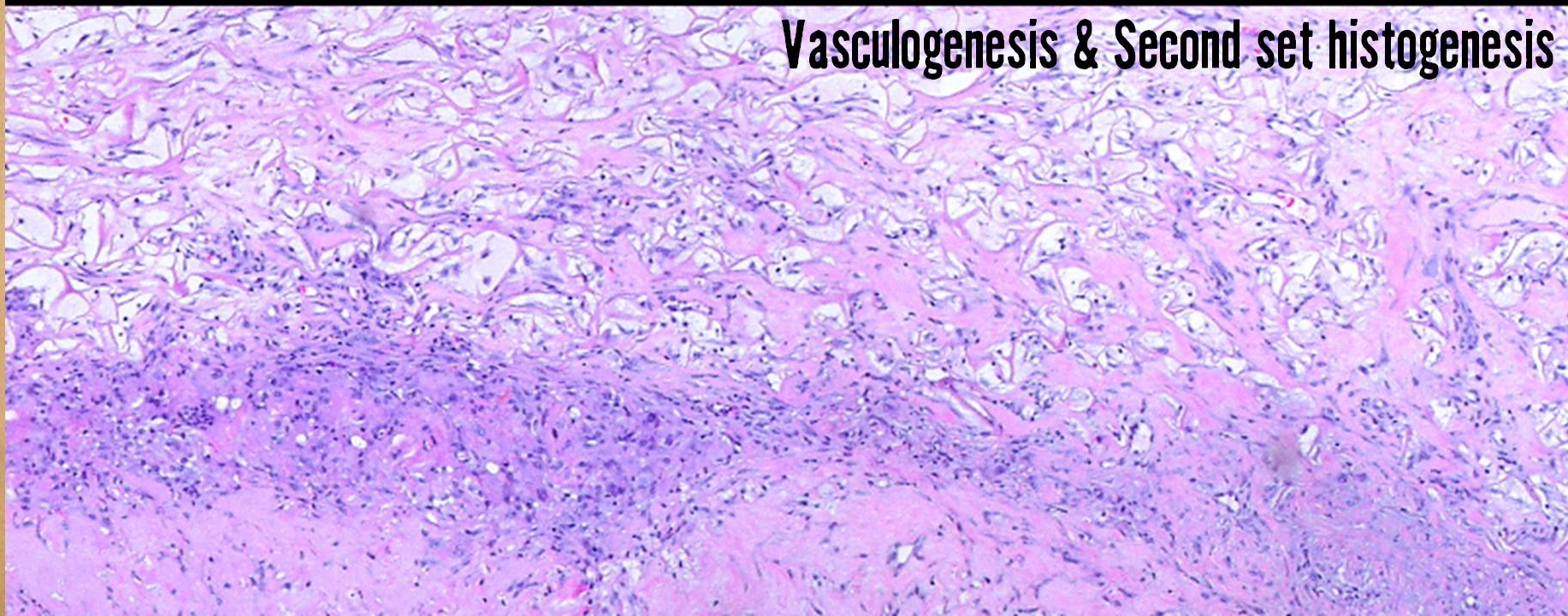
Vasculogenesis

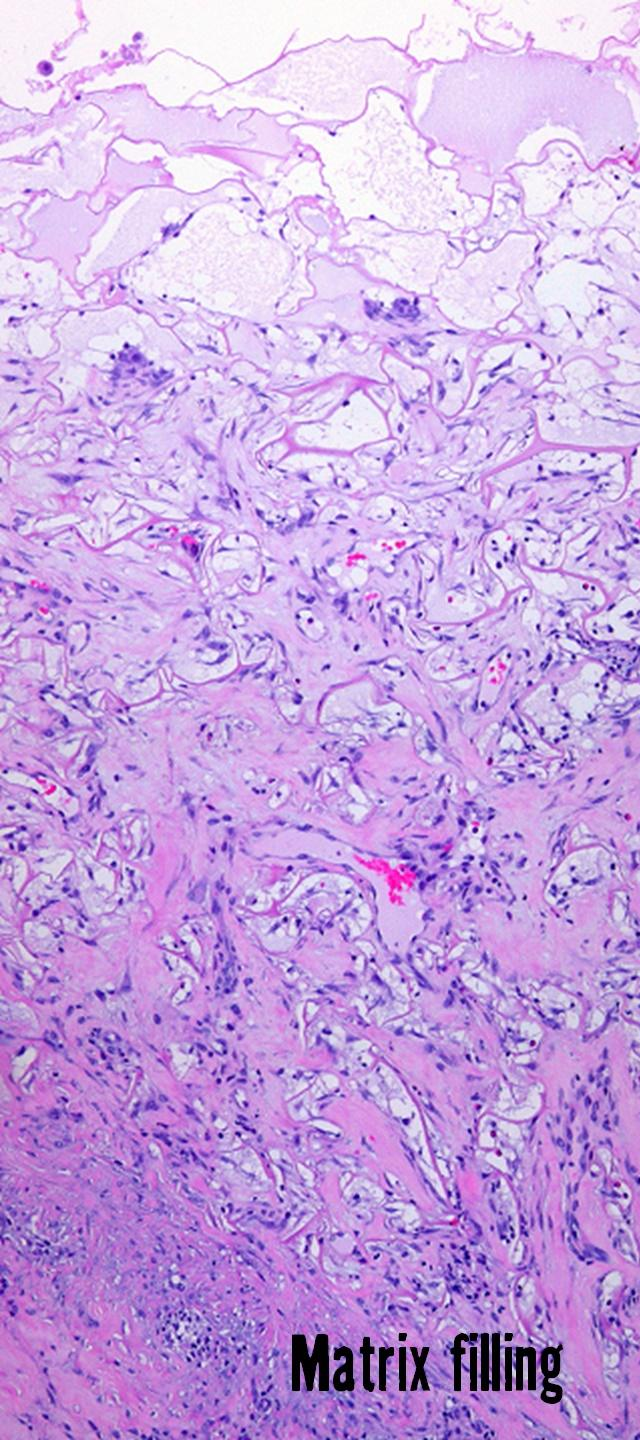
Second set histogenesis



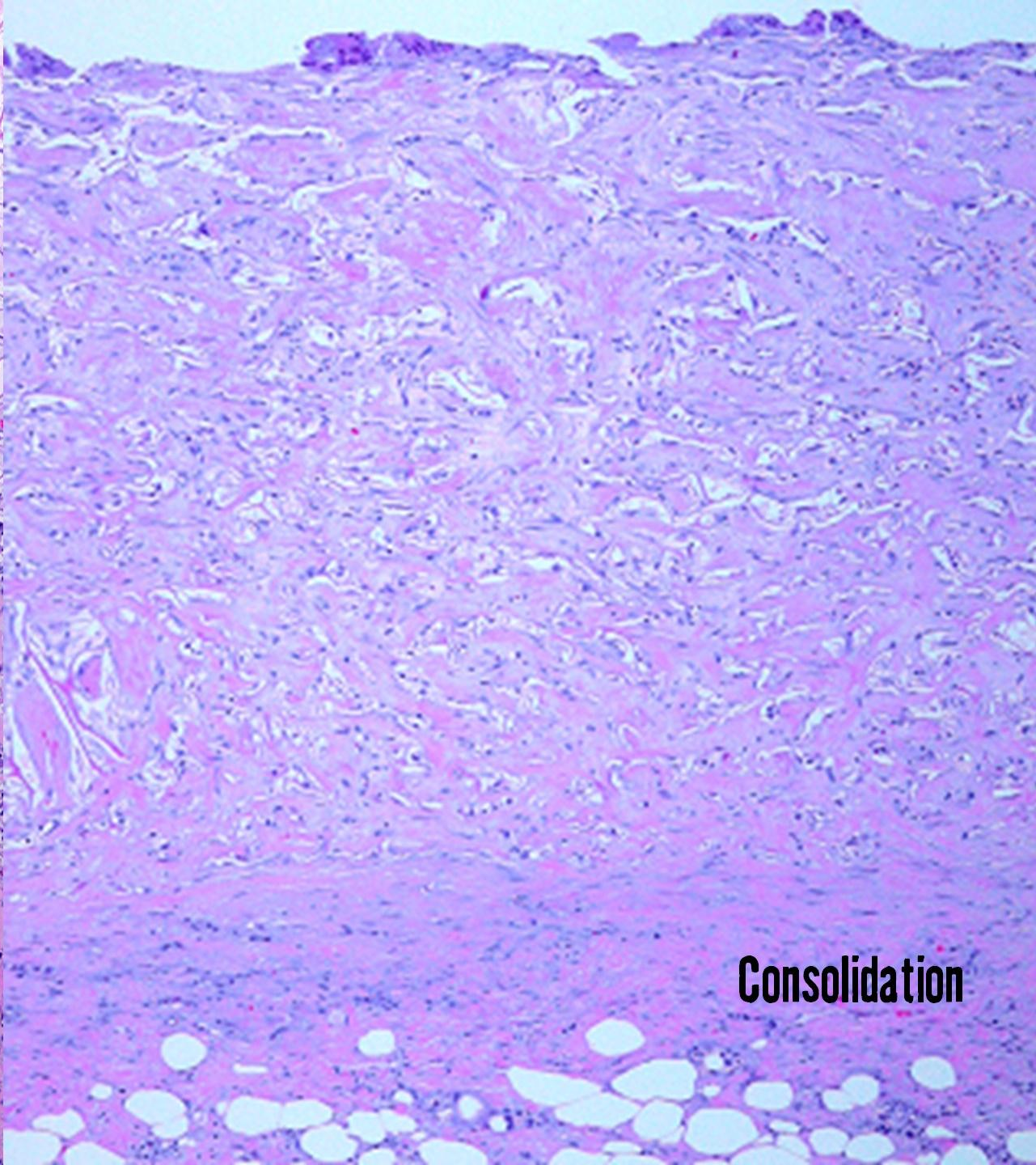


Vasculogenesis & Second set histogenesis

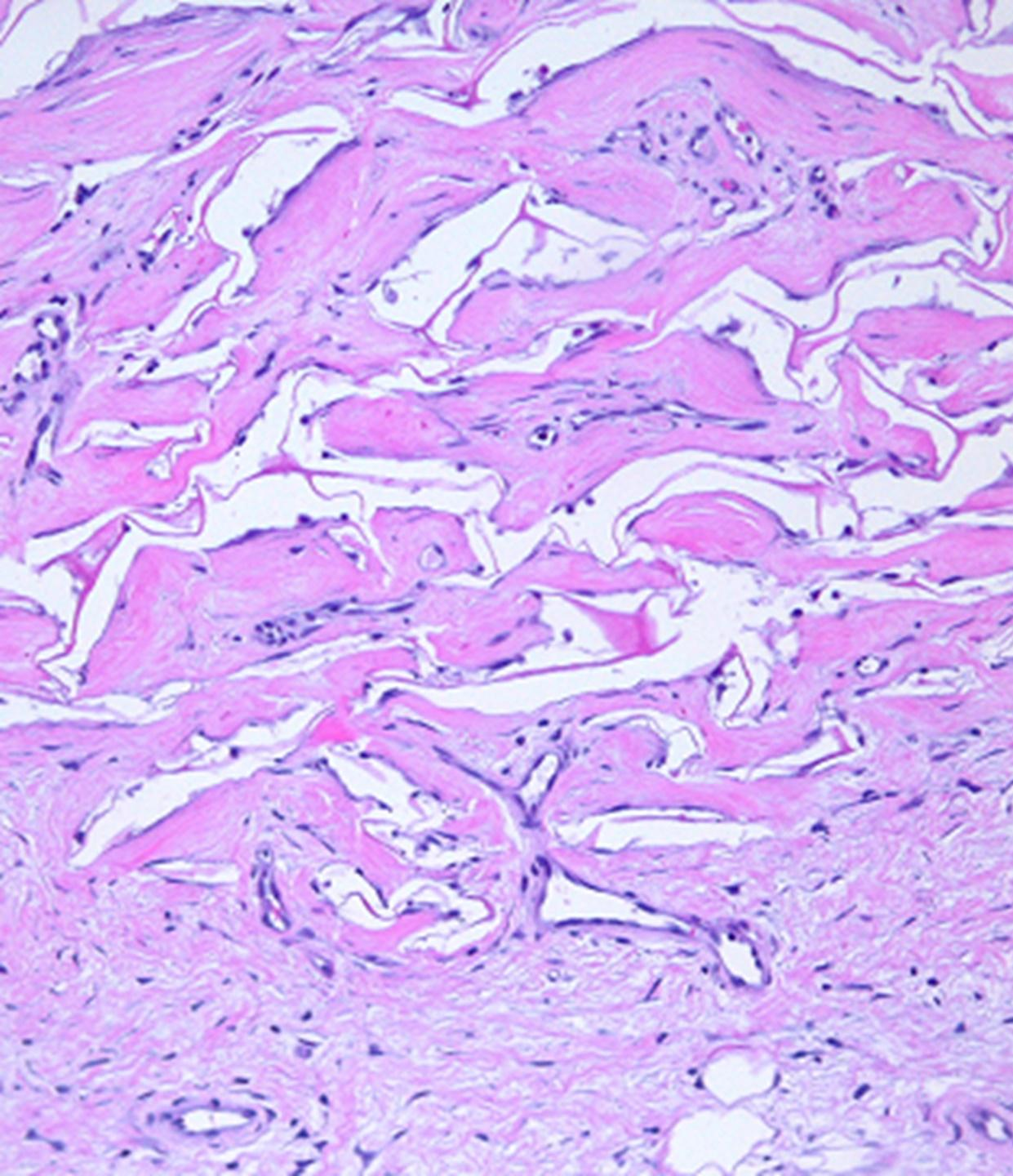




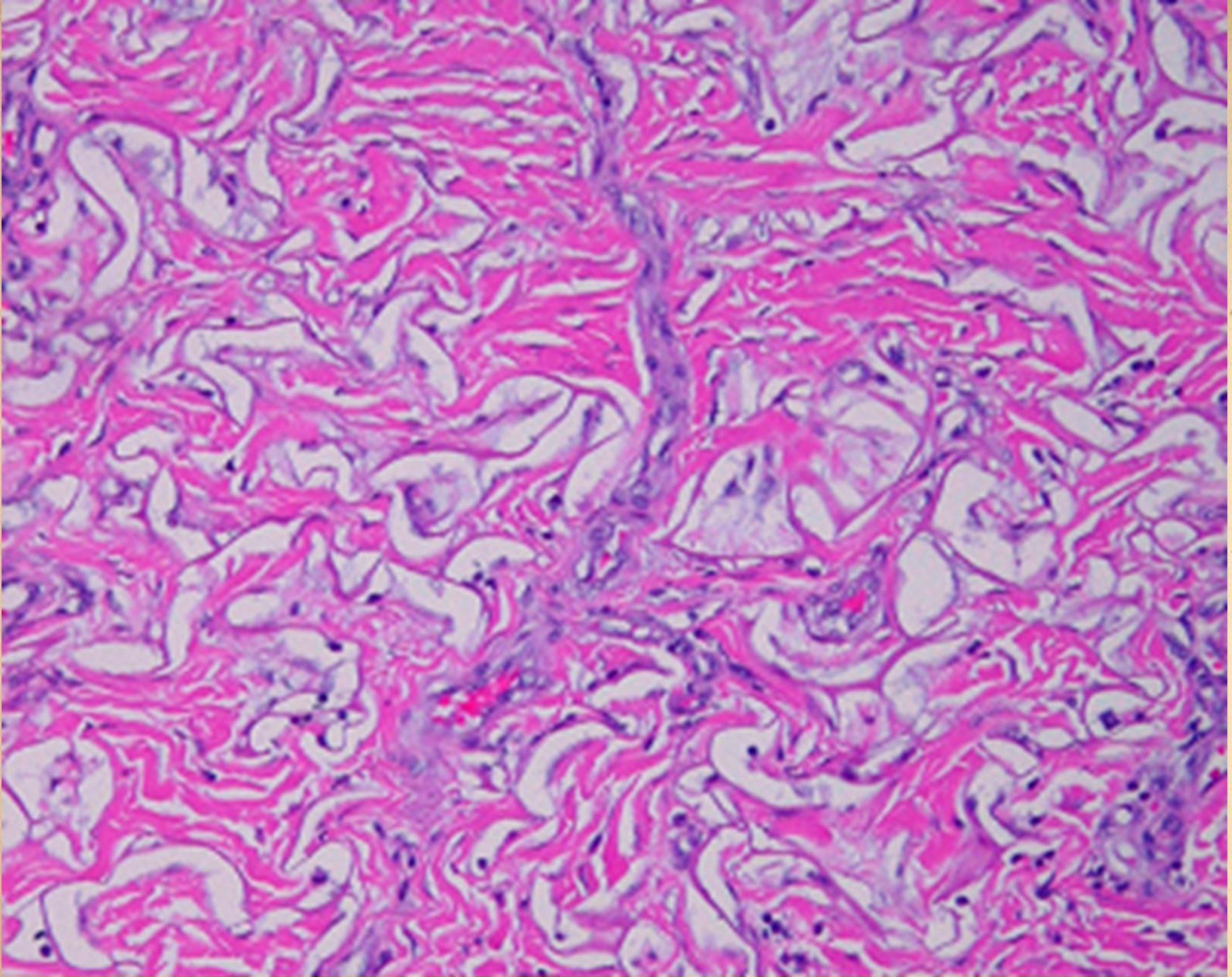
Matrix filling



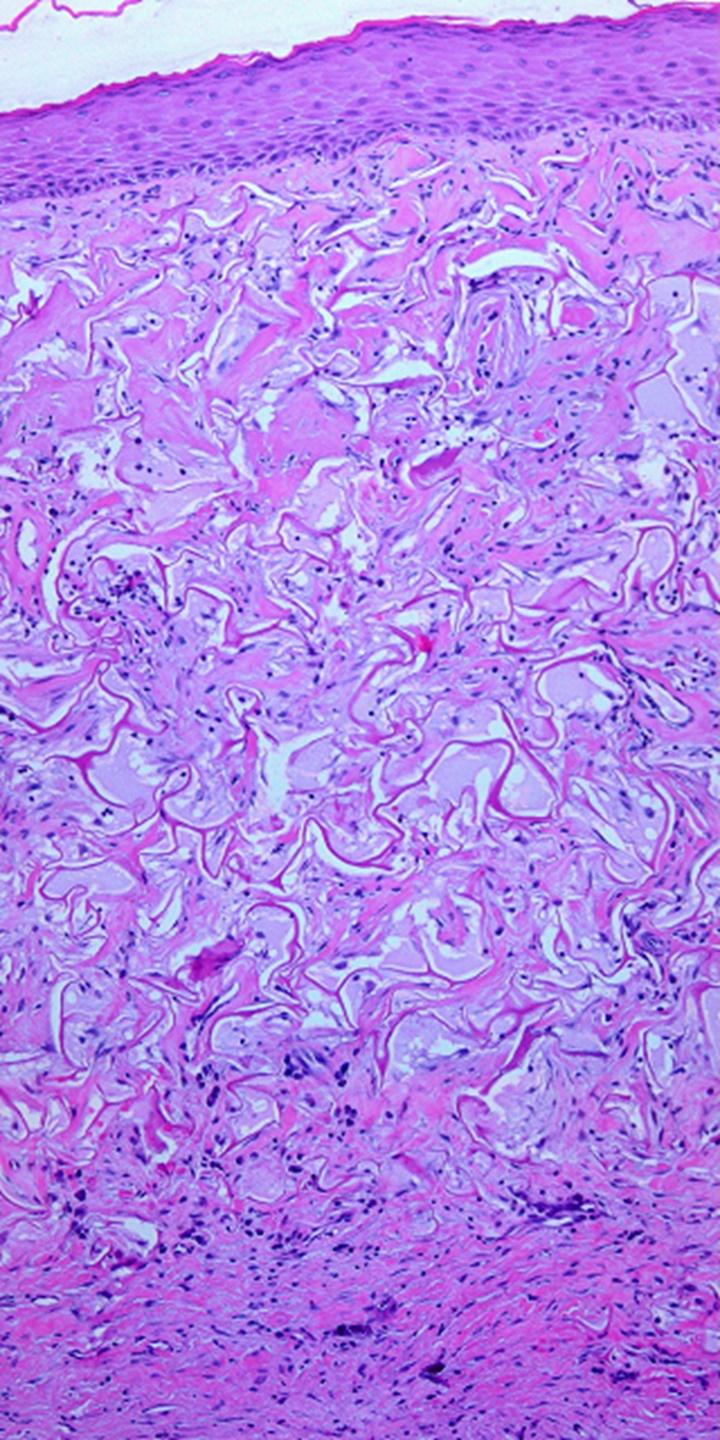
Consolidation



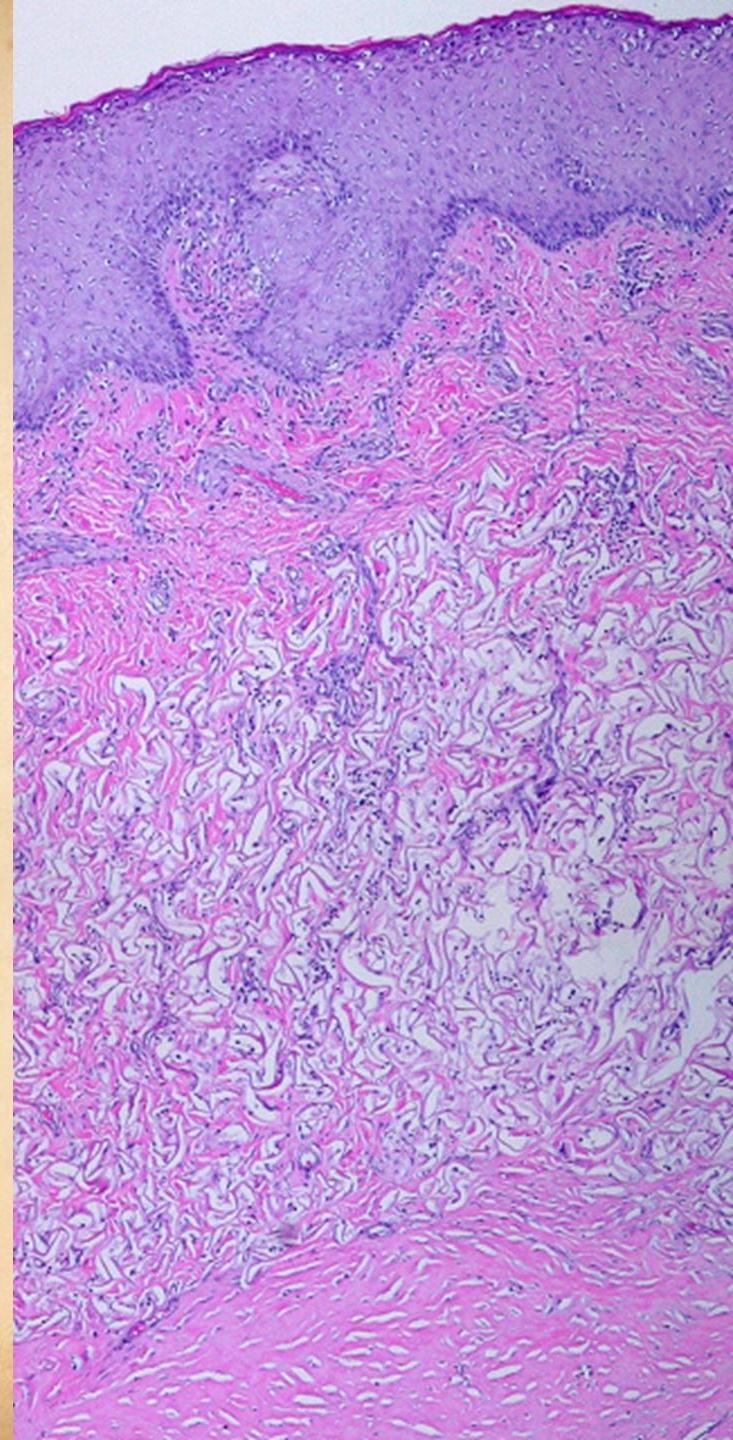
Domain maturation



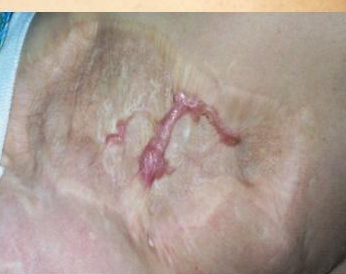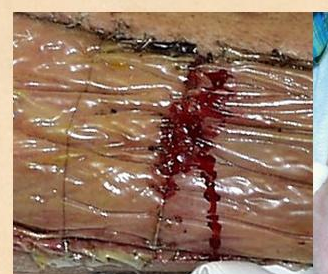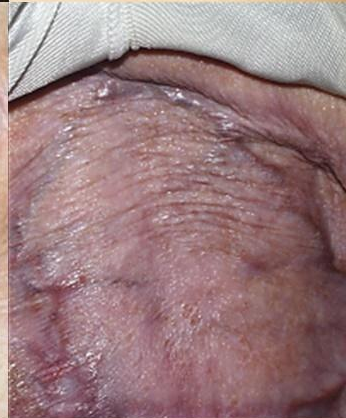
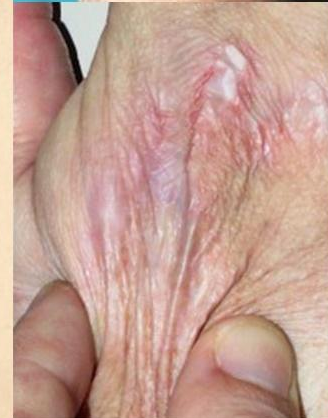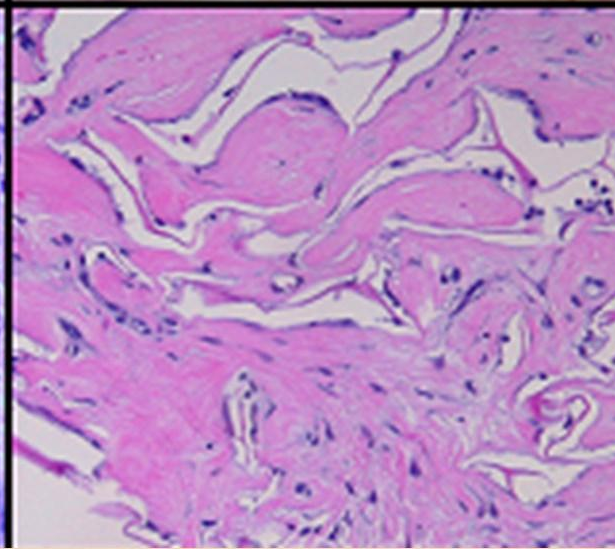
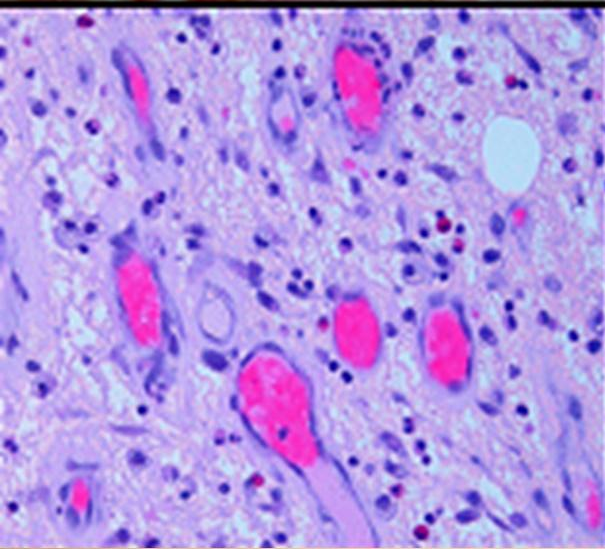
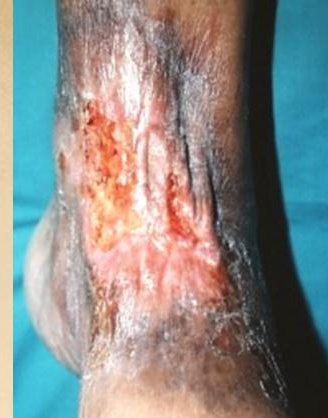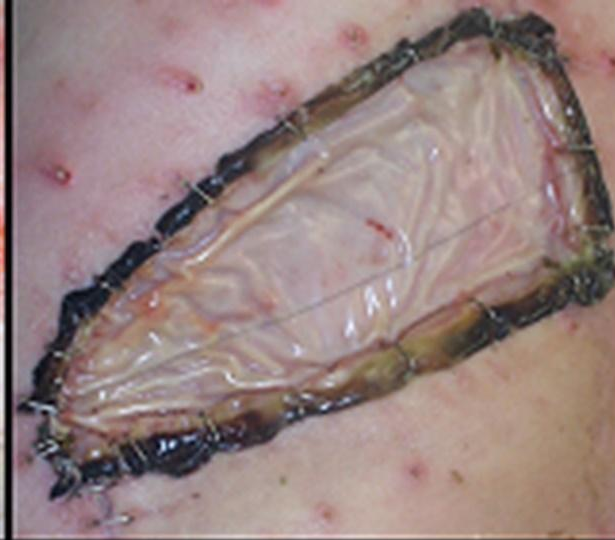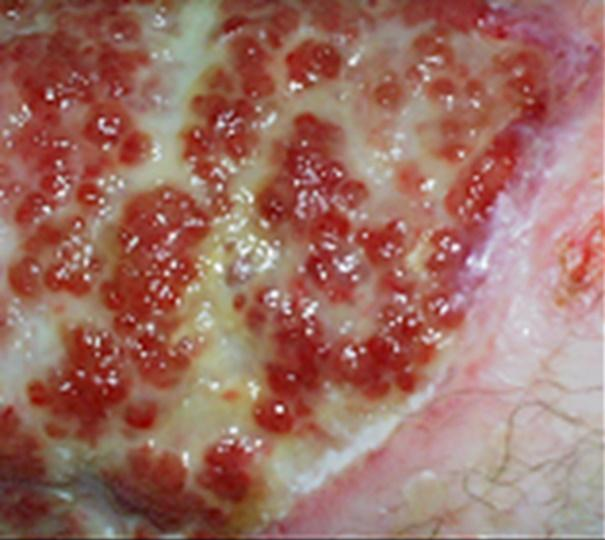Late maturation



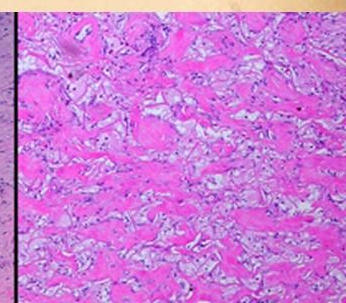
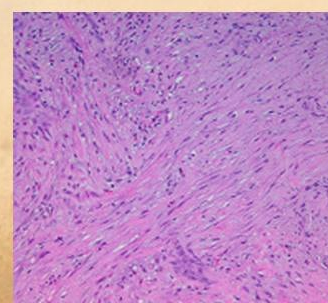
**Epidermal
events, early**

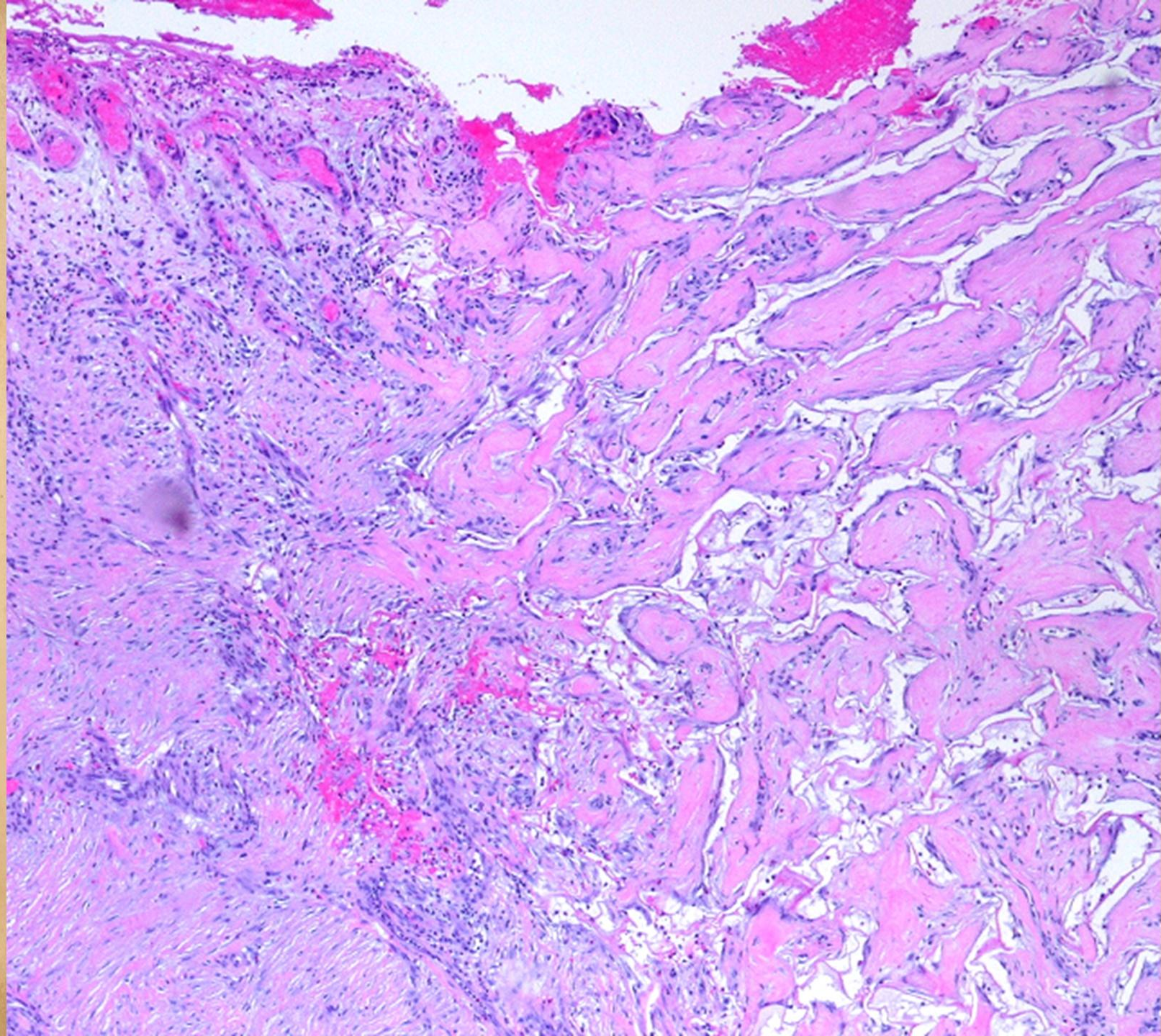


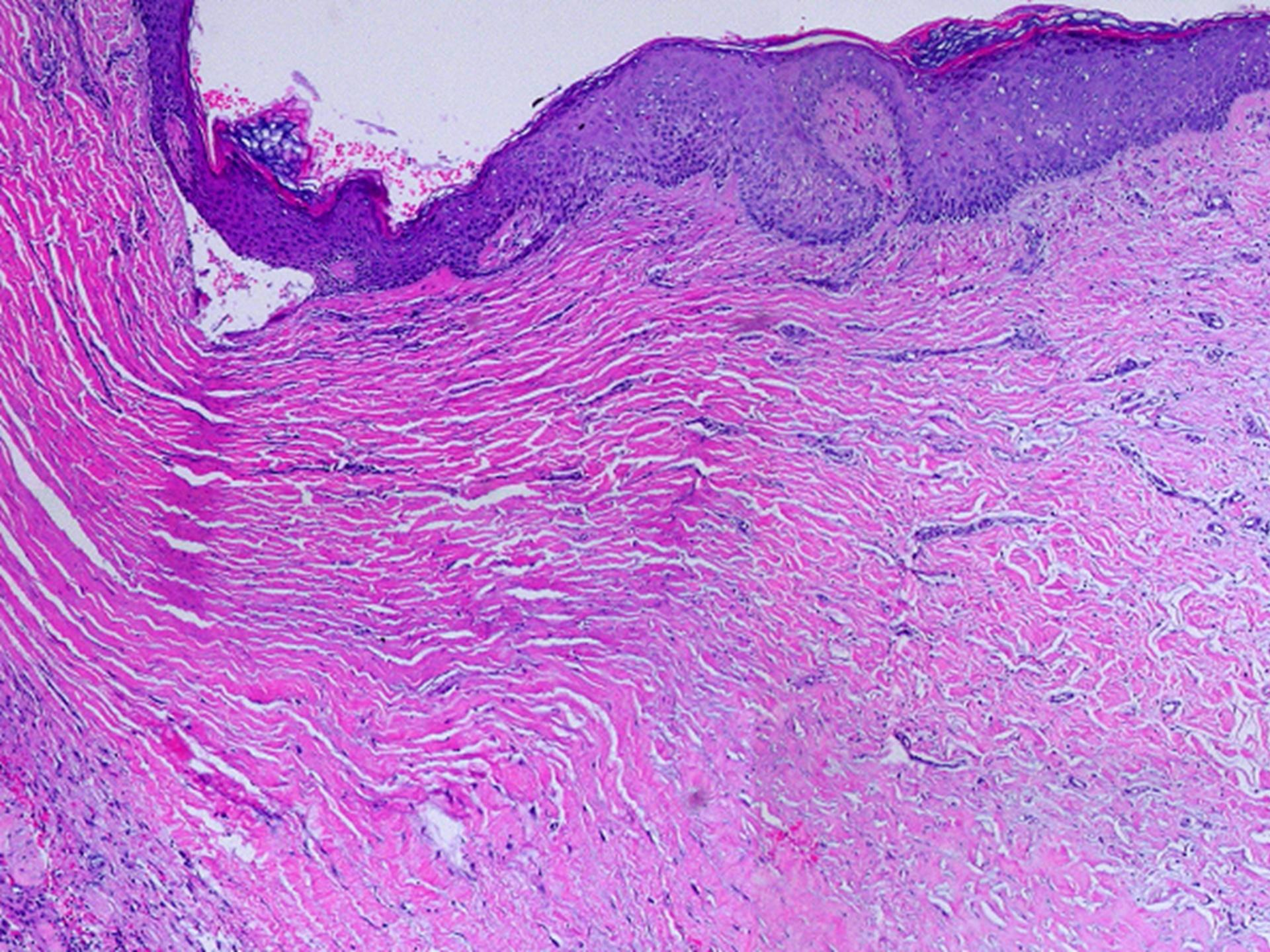
**Epidermal
events, late**



wound healing
versus
integra histogenesis





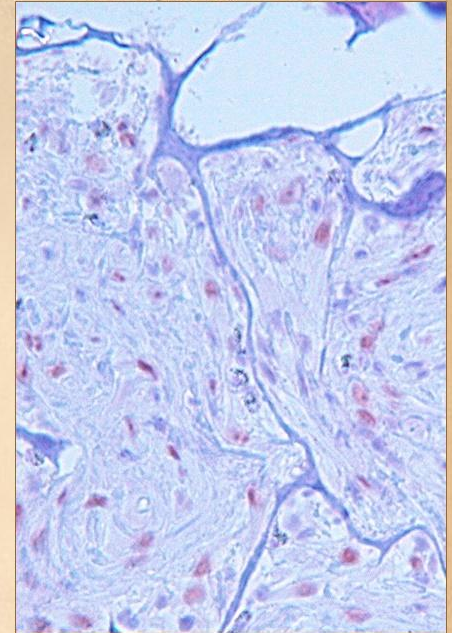
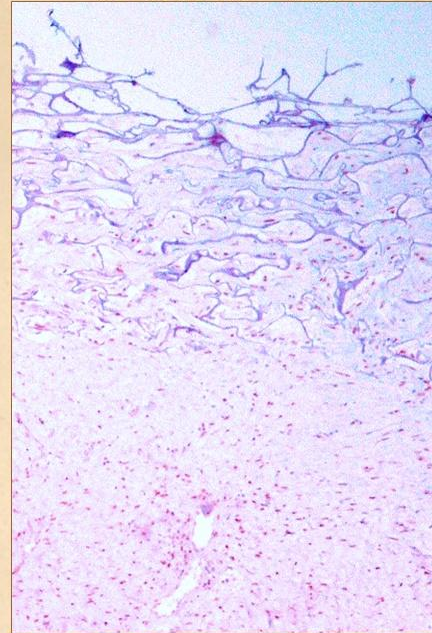
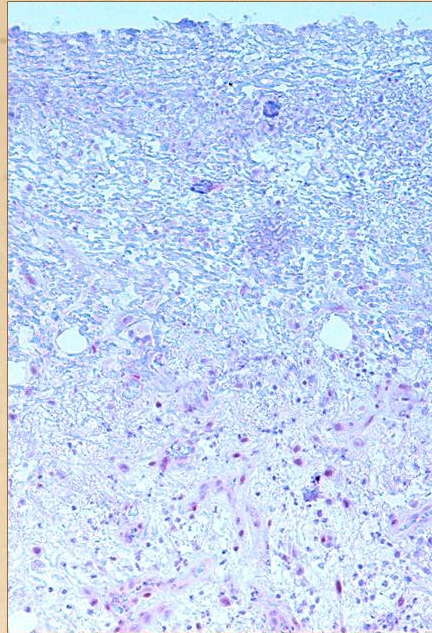


DAY 0

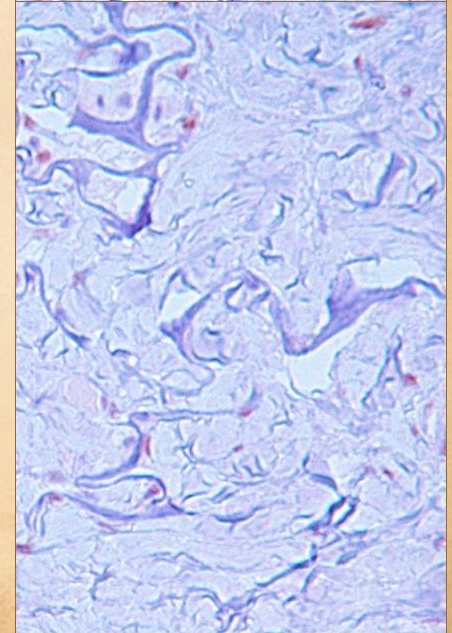
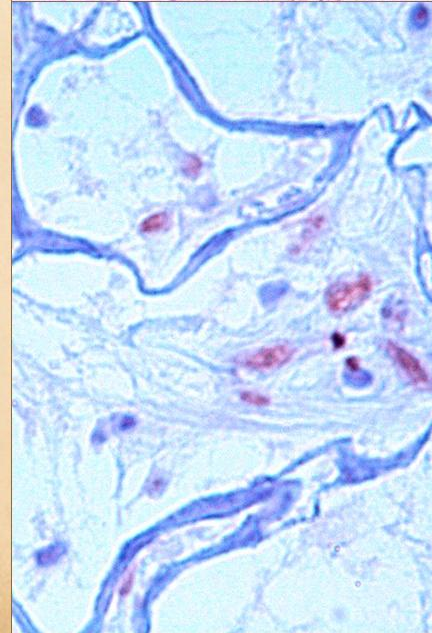
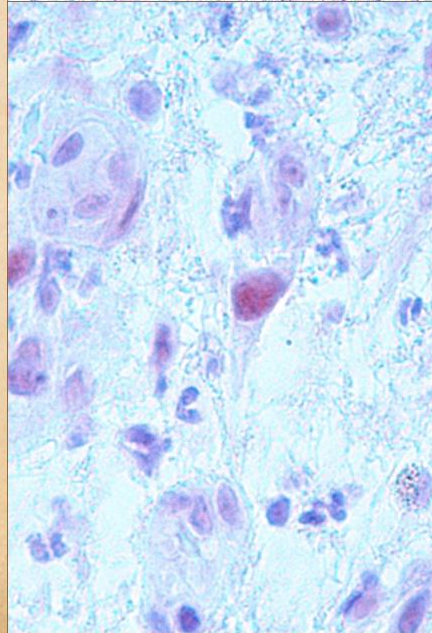
DAY 17

DAY 30

V



B



C

B

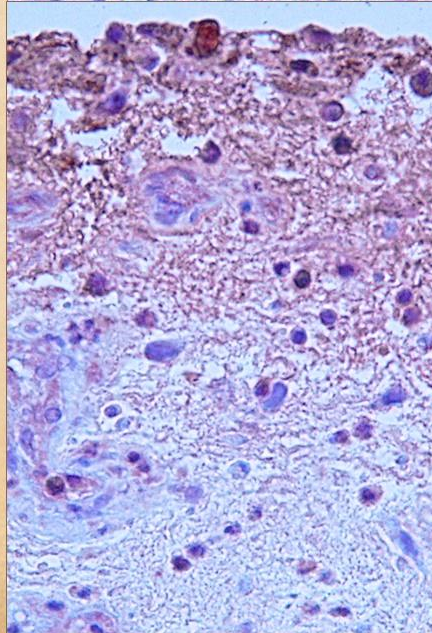
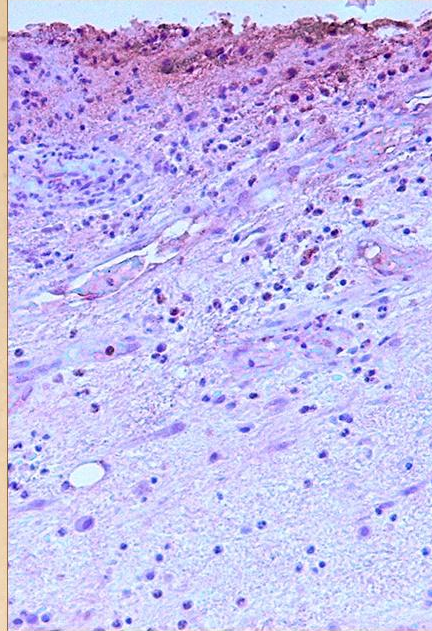
P

D

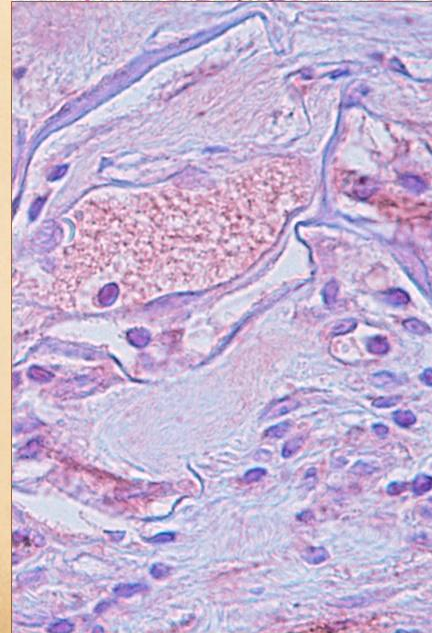
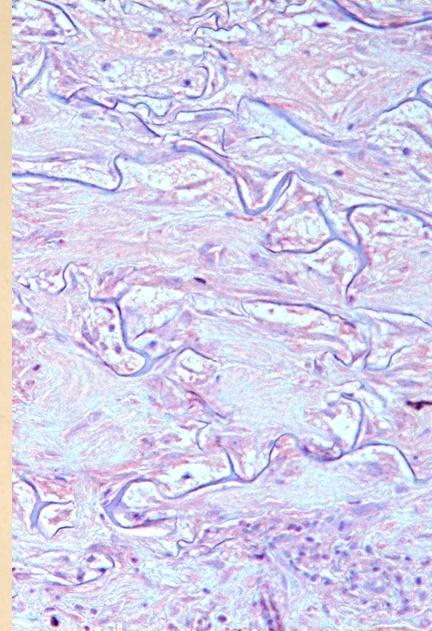
G

R

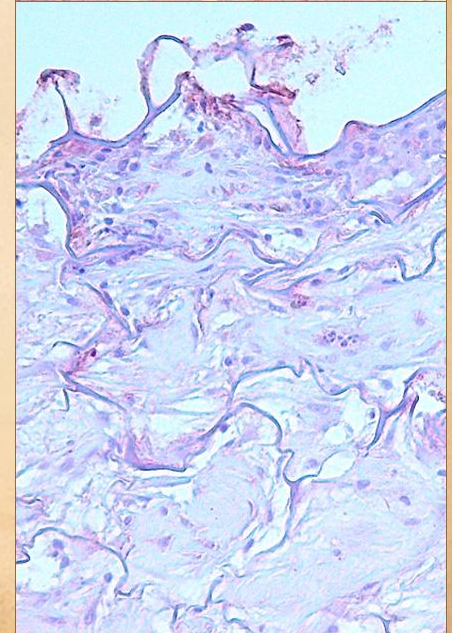
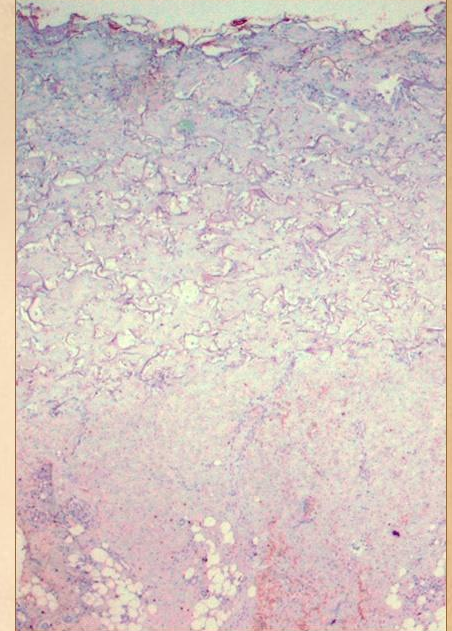
DAY 0



DAY 17



DAY 30



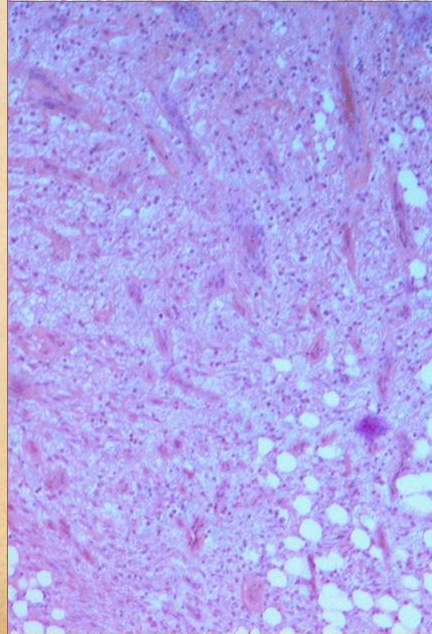
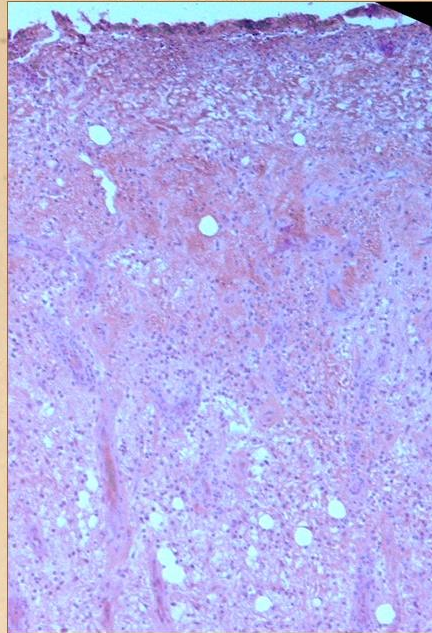
B

R

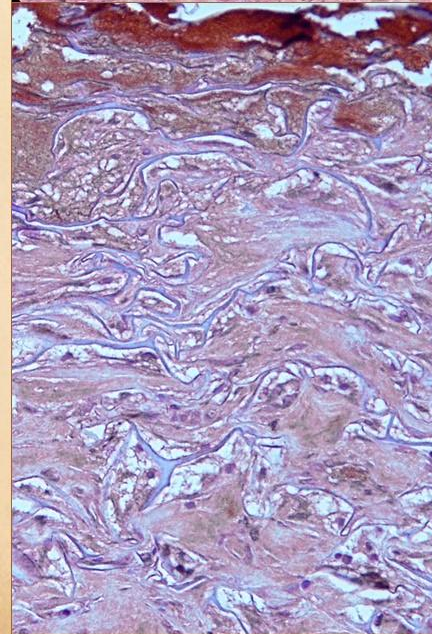
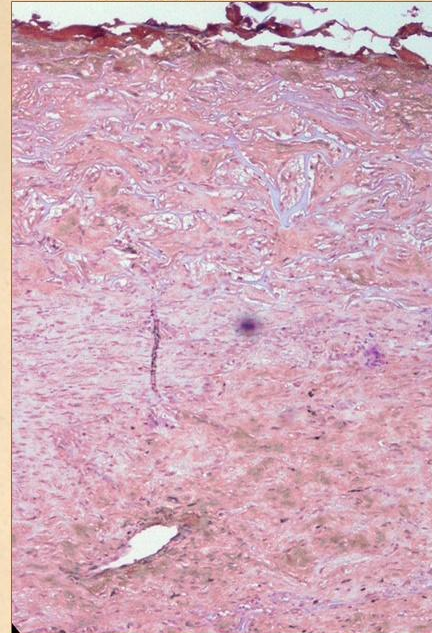
G

R

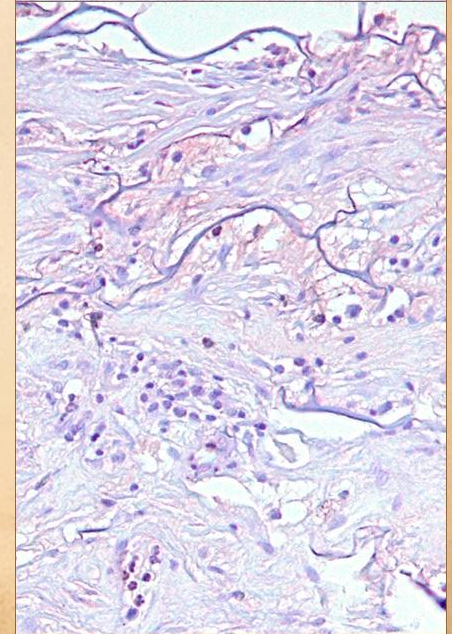
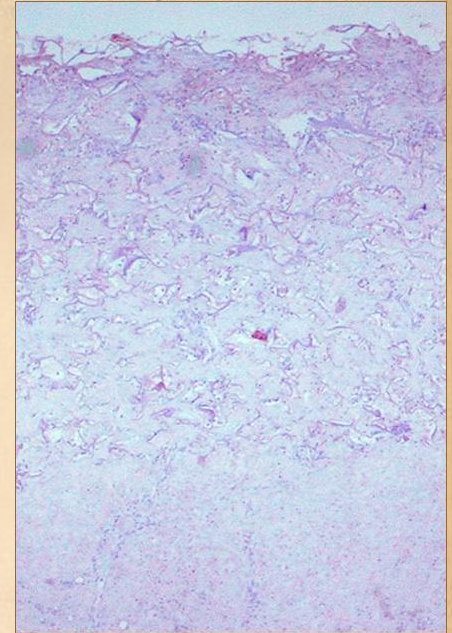
DAY 0

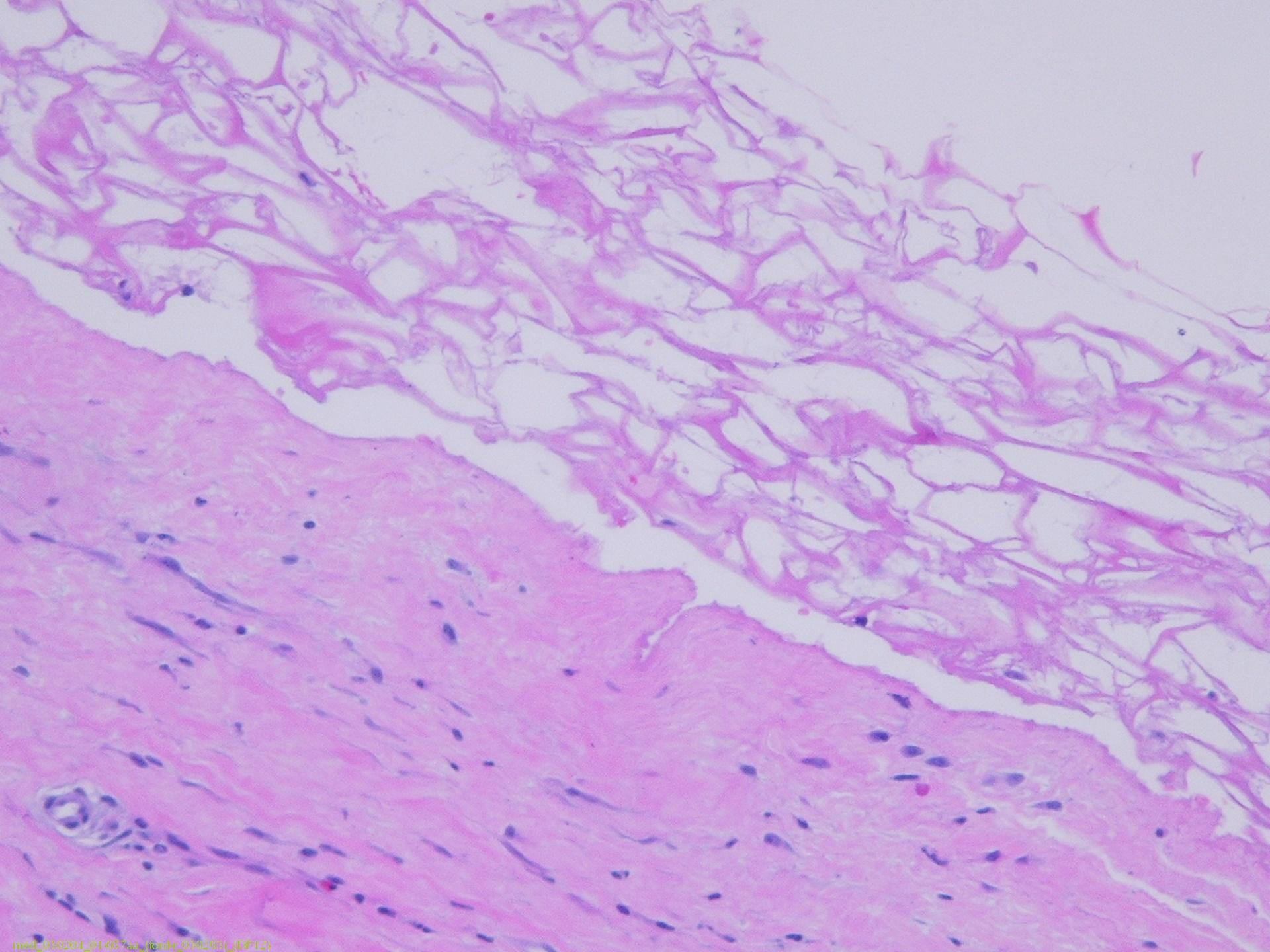


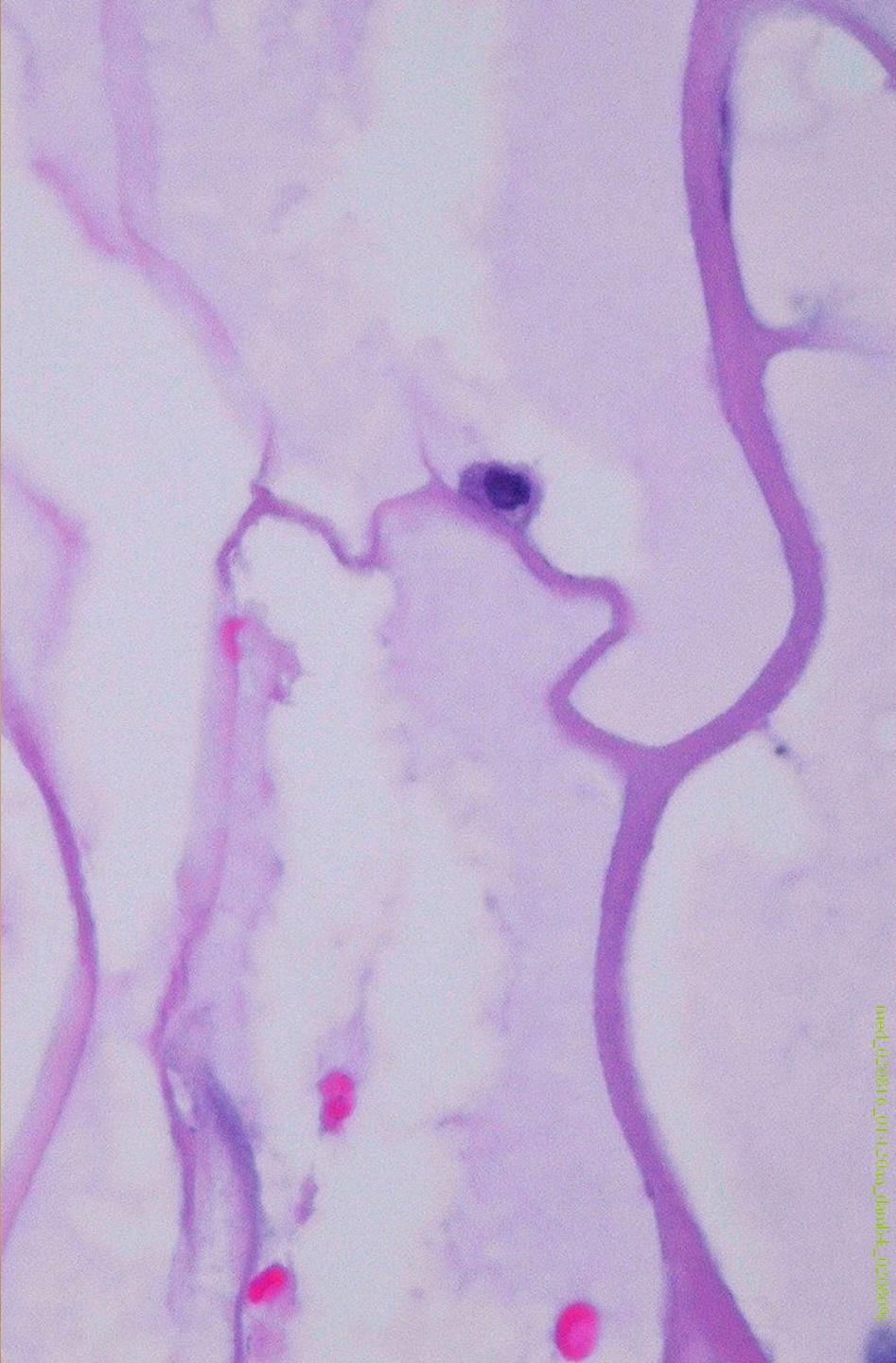
DAY 17



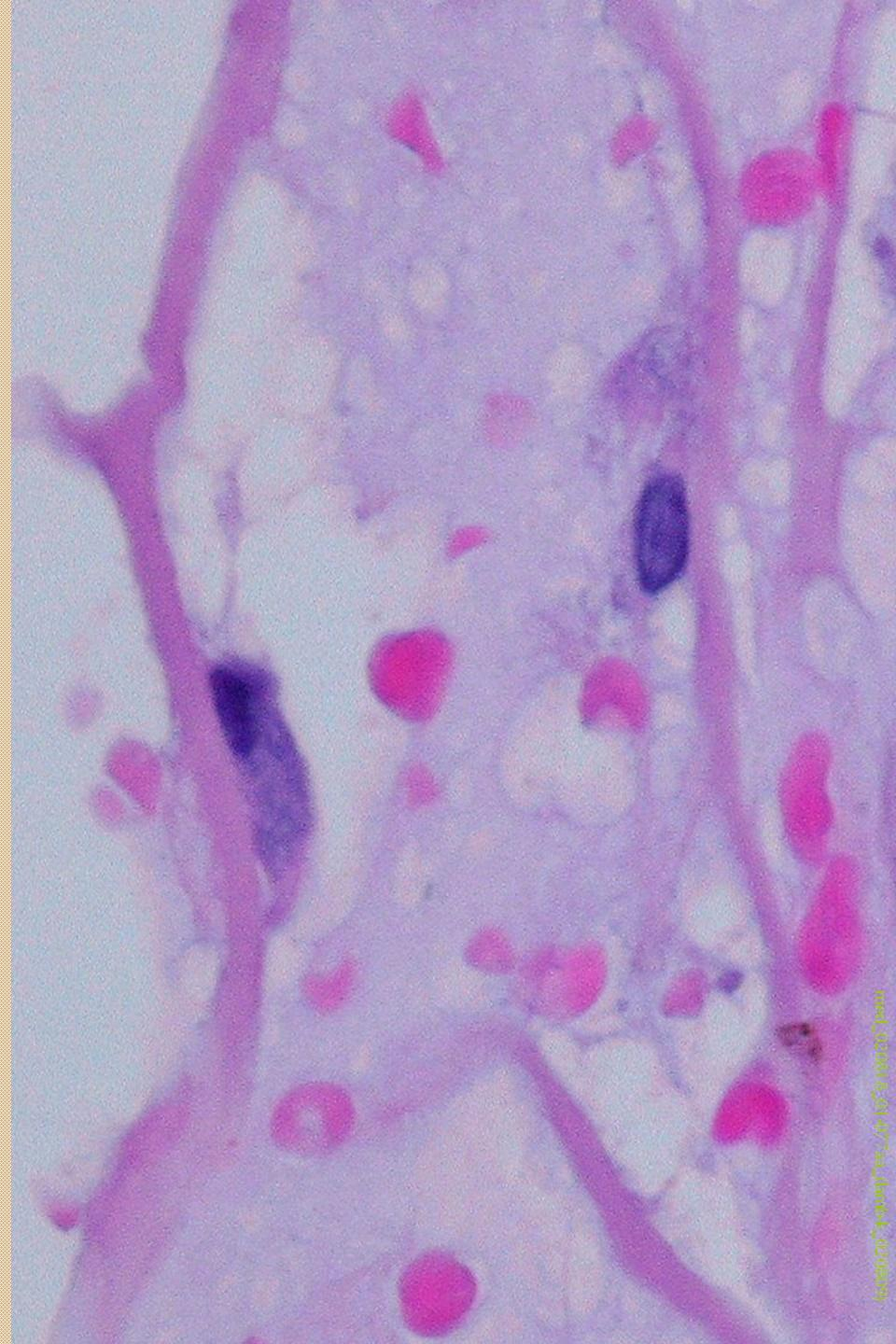
DAY 30





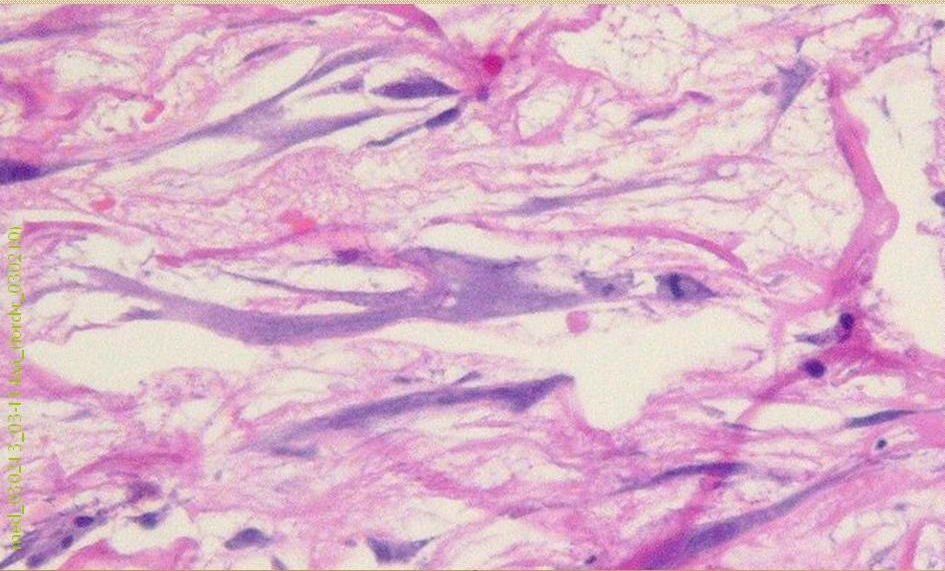
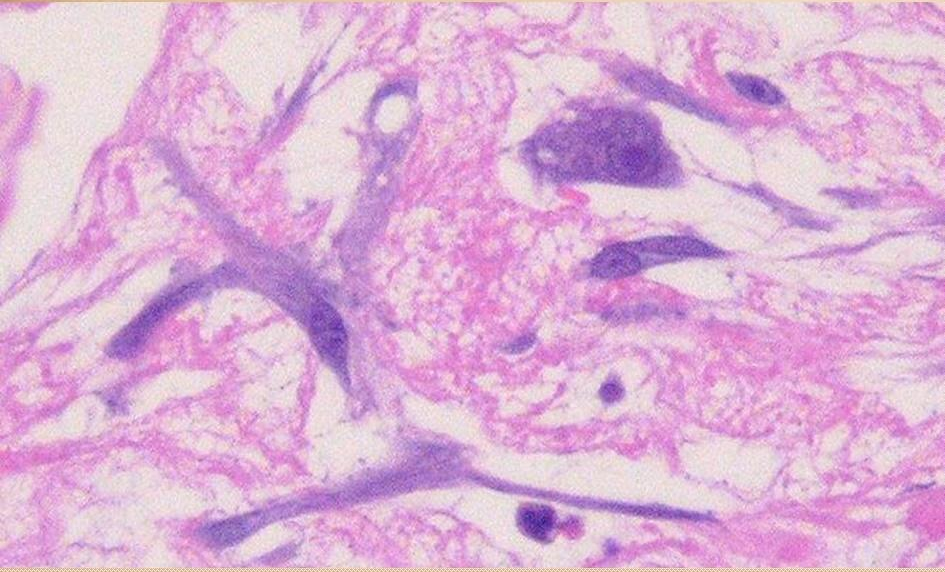


Micrograph showing plant tissue structure, likely a vascular bundle, stained with a purple dye.

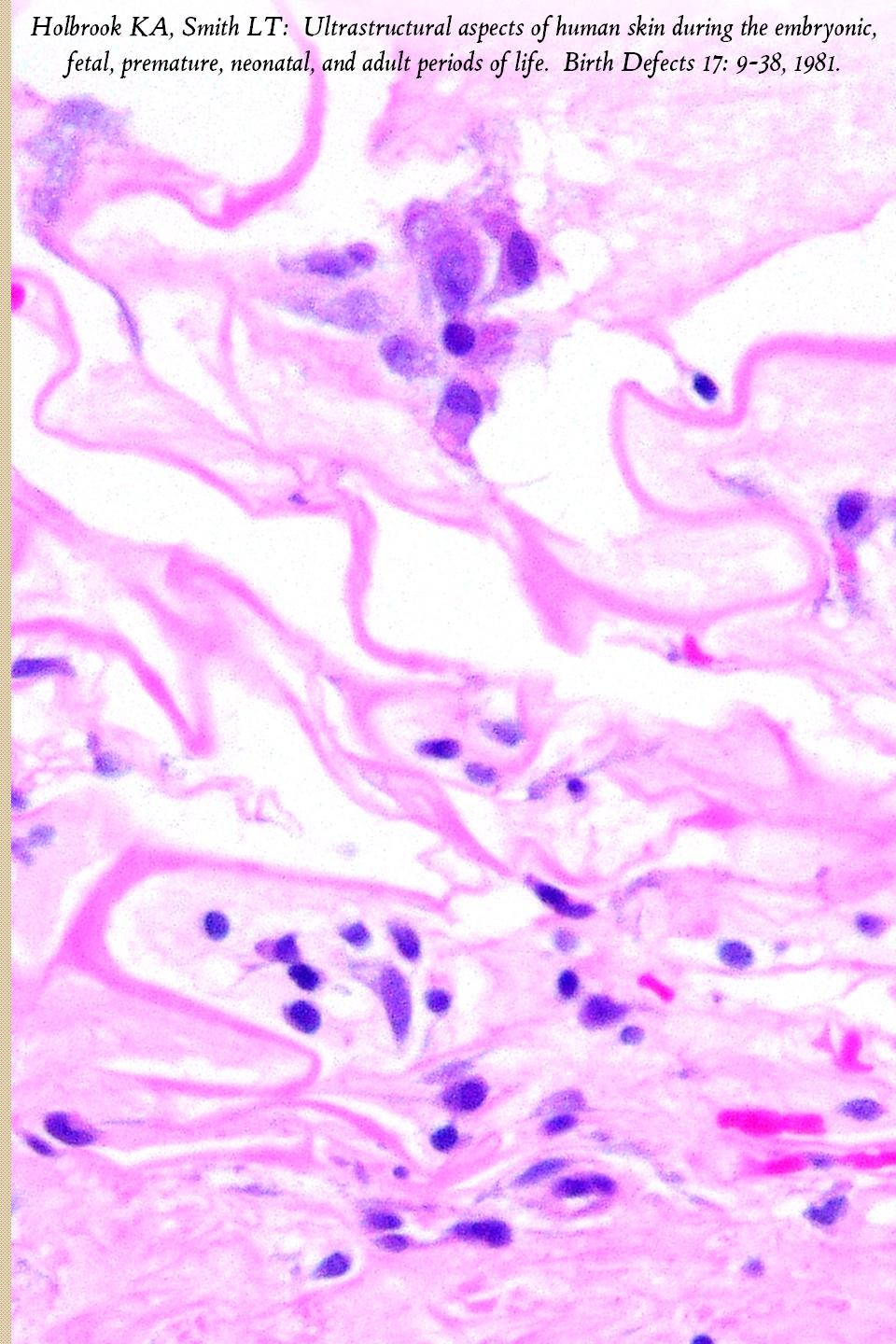


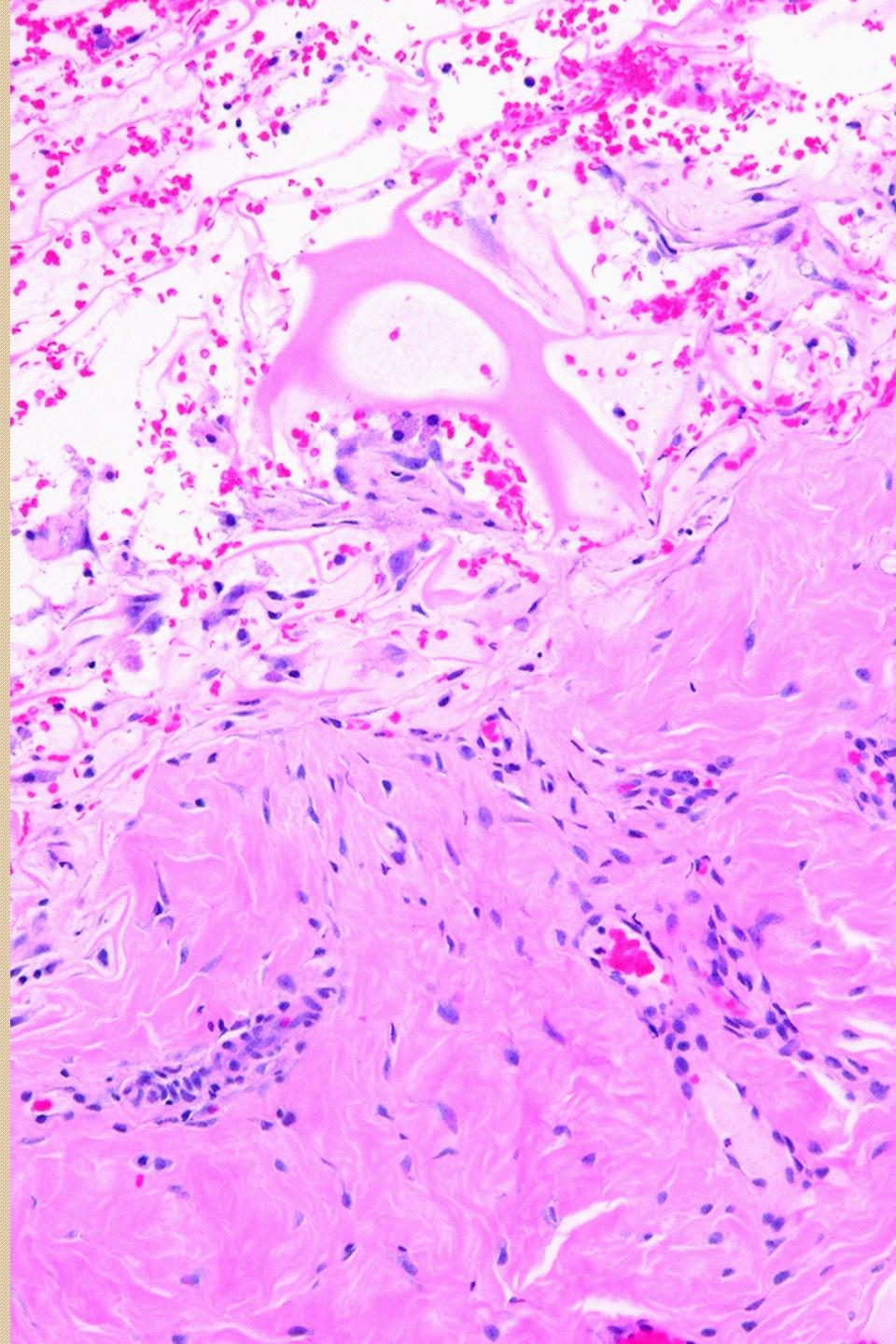
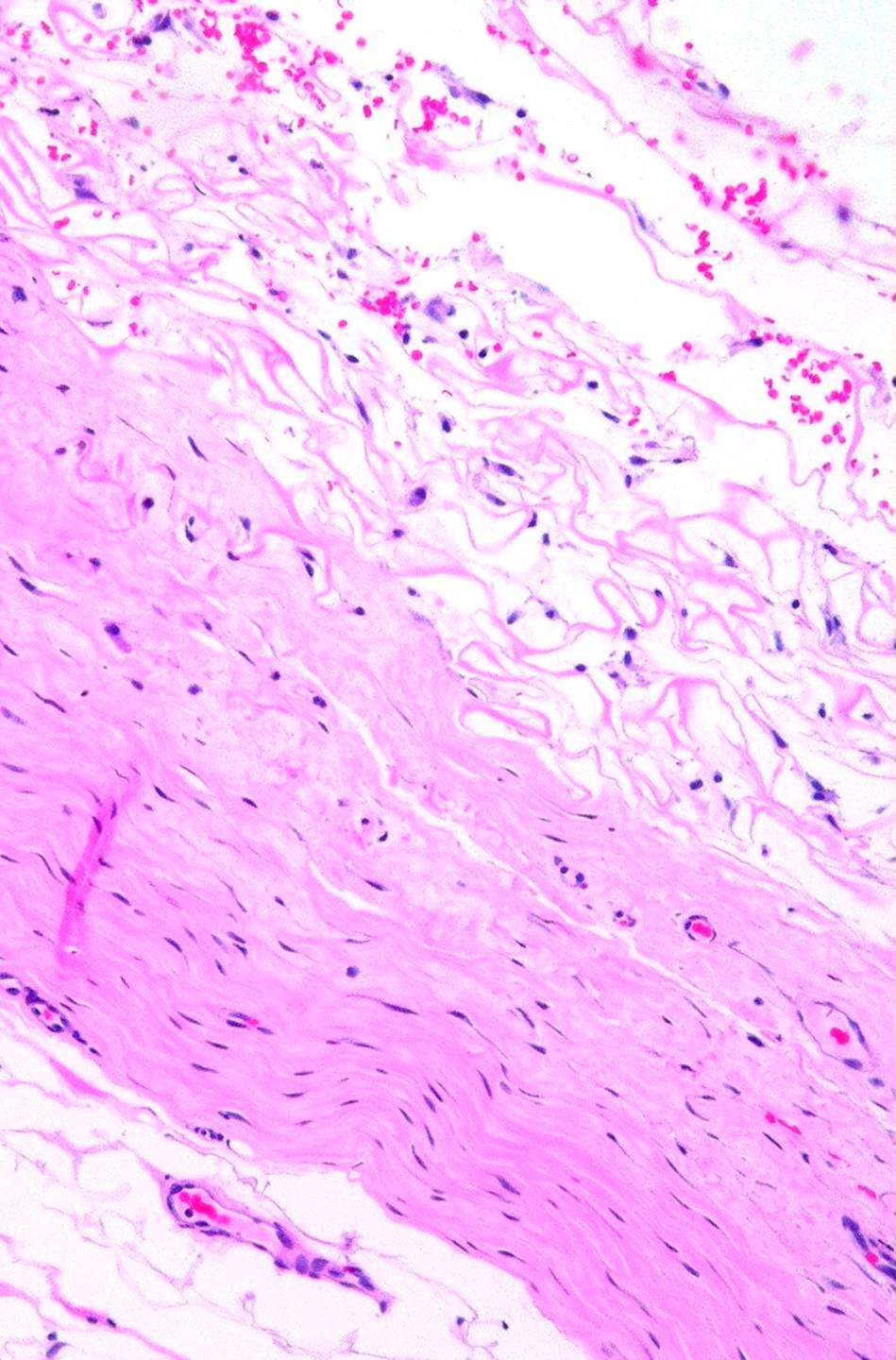
Micrograph showing plant tissue structure, likely a vascular bundle, stained with a purple dye.

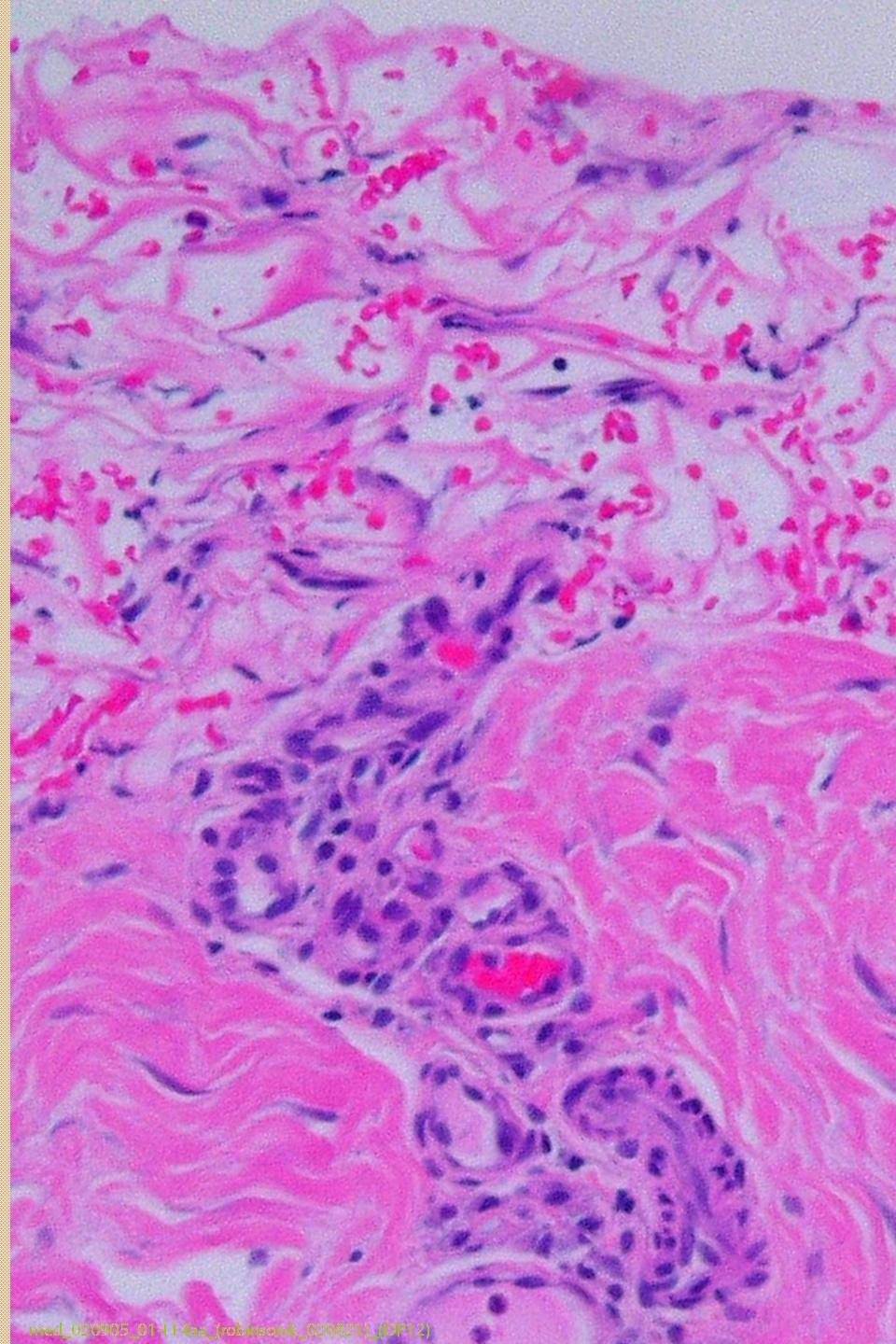
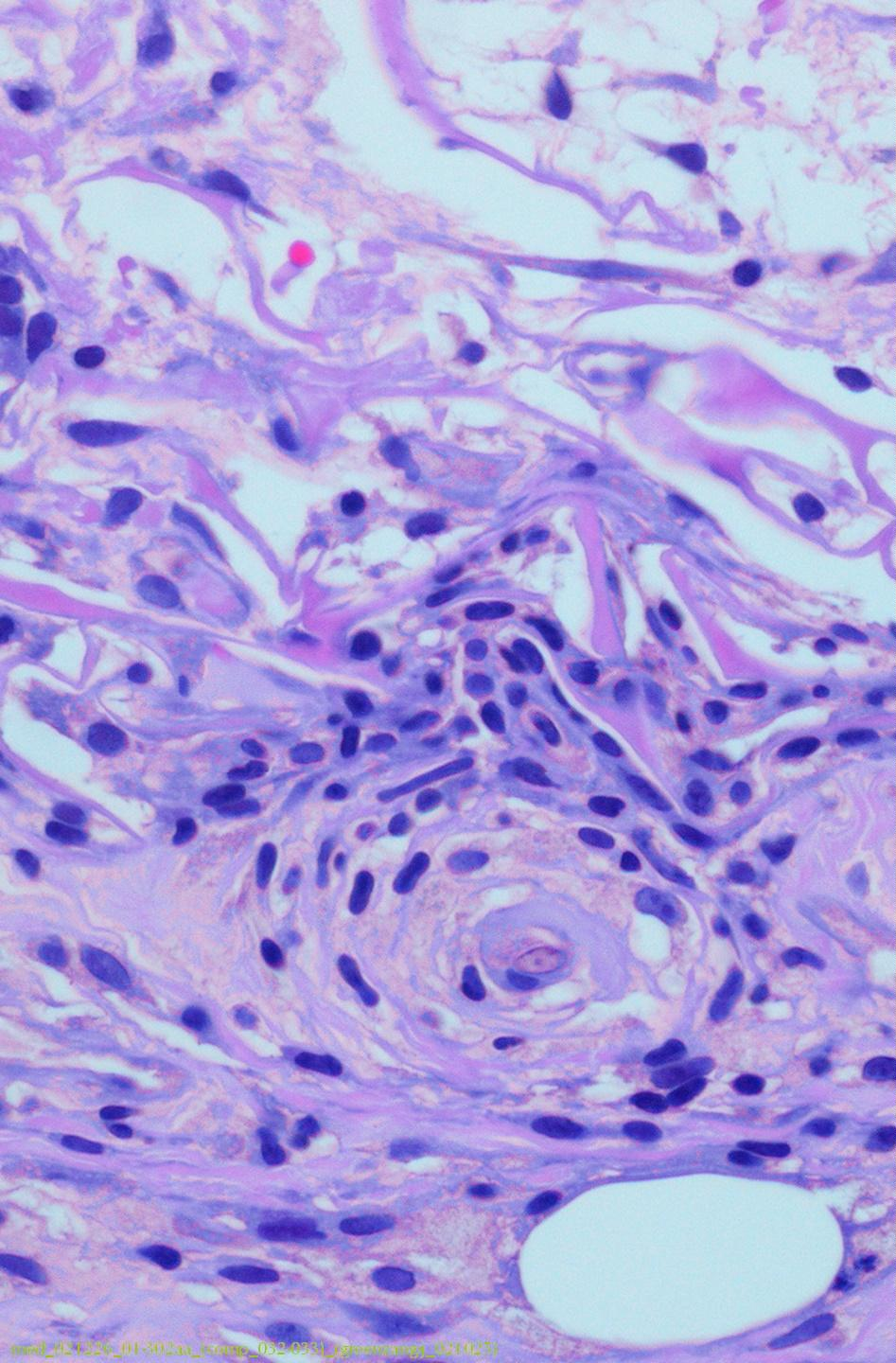
“ . . . a watery, cellular network of mesenchyme that is joined through long slender pseudopodia processes and specialized intercellular junctions into a syncytium . . . ”

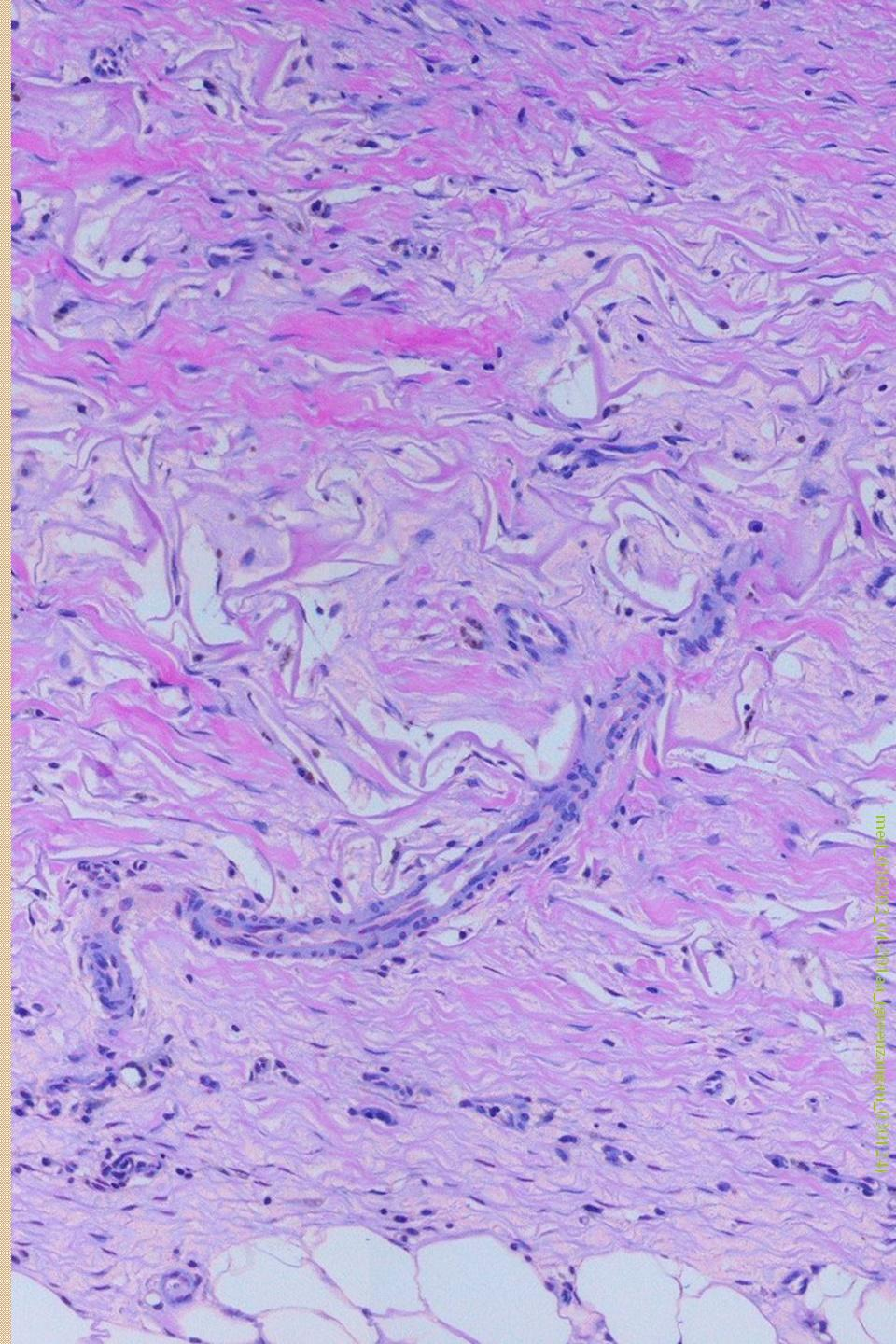
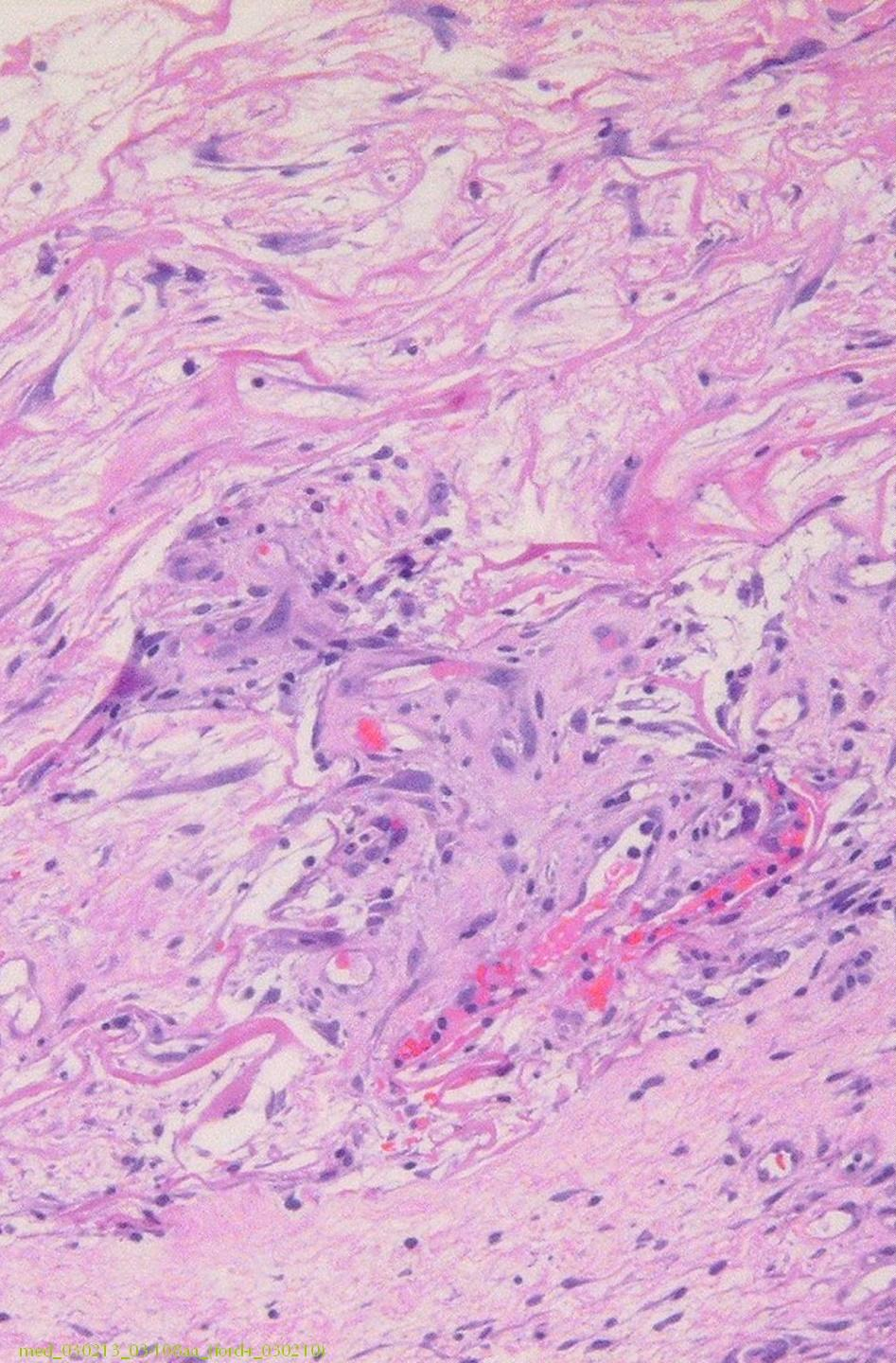


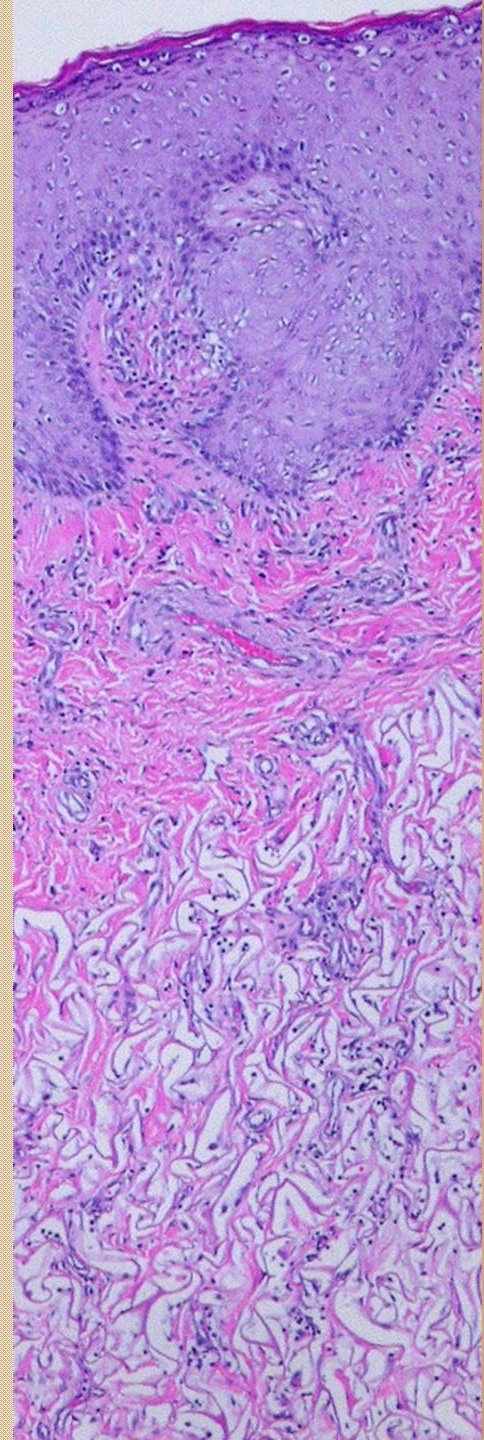
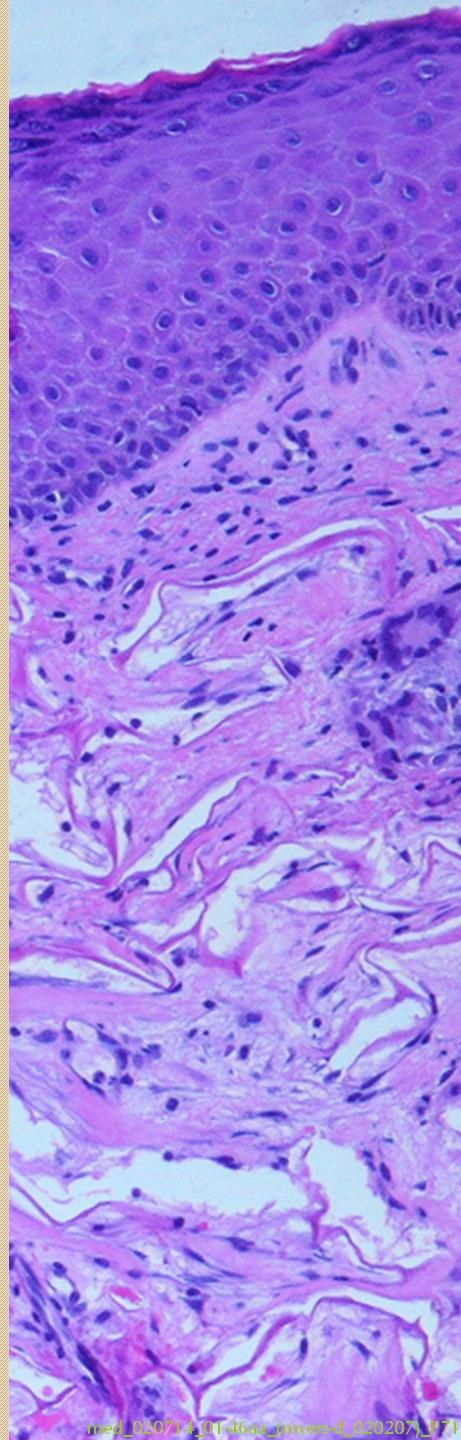
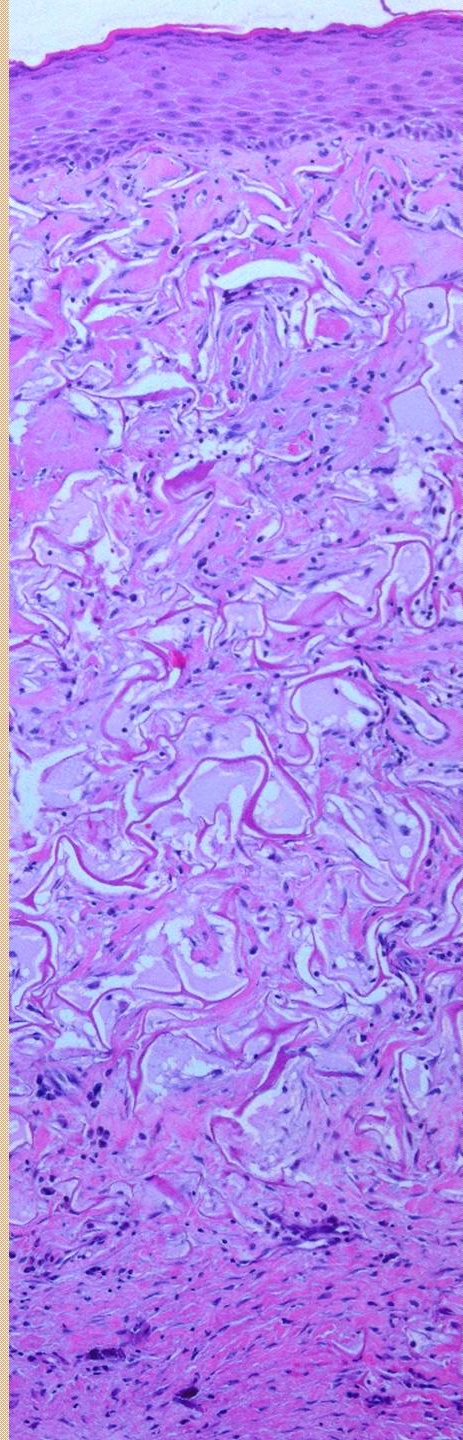
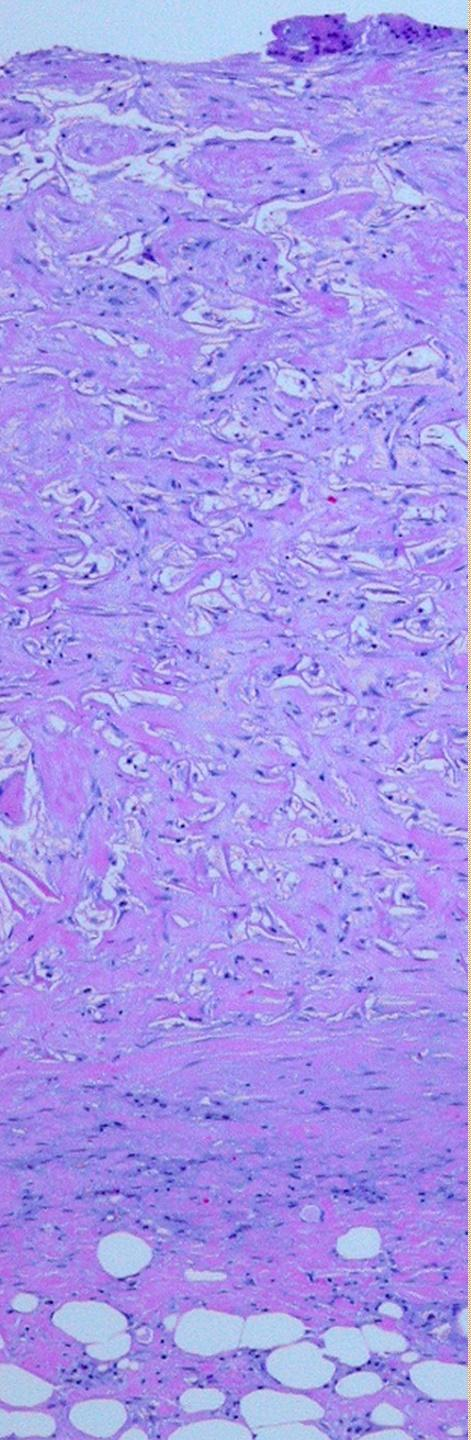
Holbrook KA, Smith LT: Ultrastructural aspects of human skin during the embryonic, fetal, premature, neonatal, and adult periods of life. Birth Defects 17: 9-38, 1981.

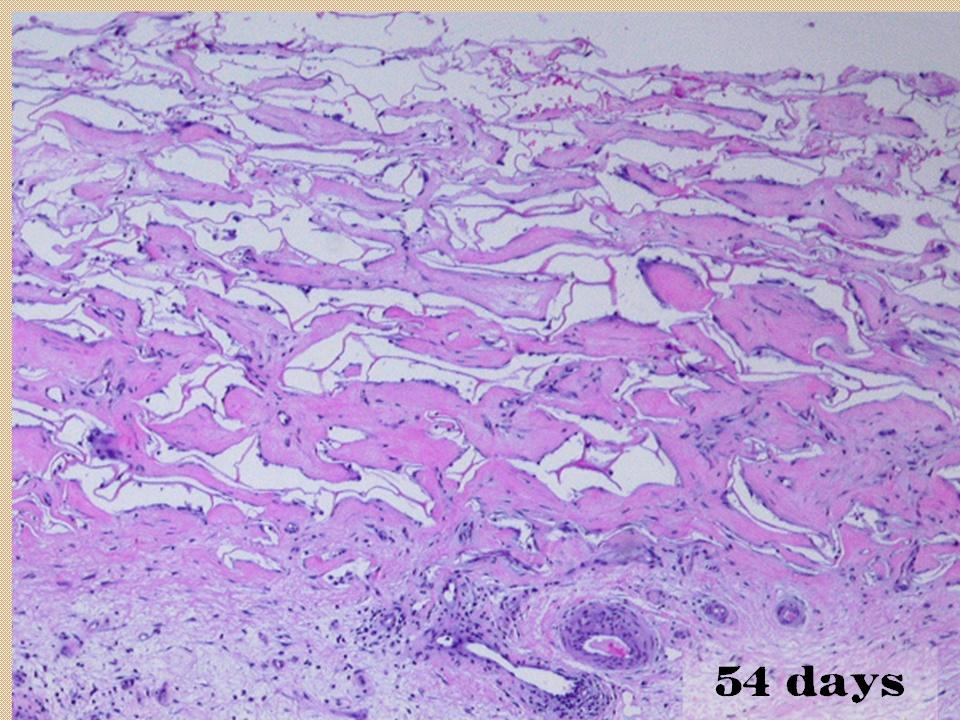
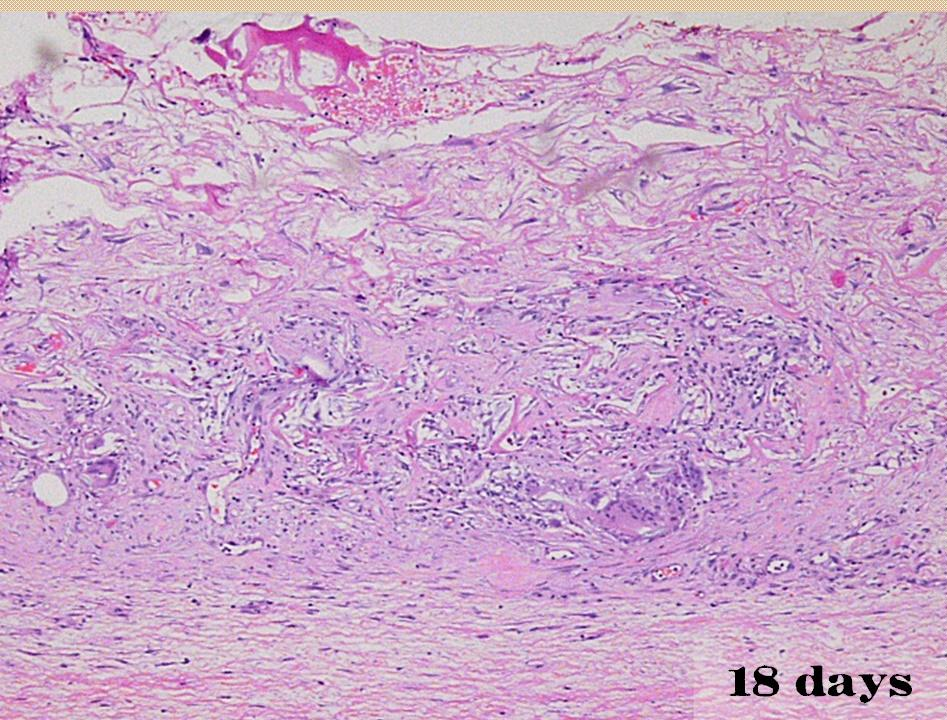
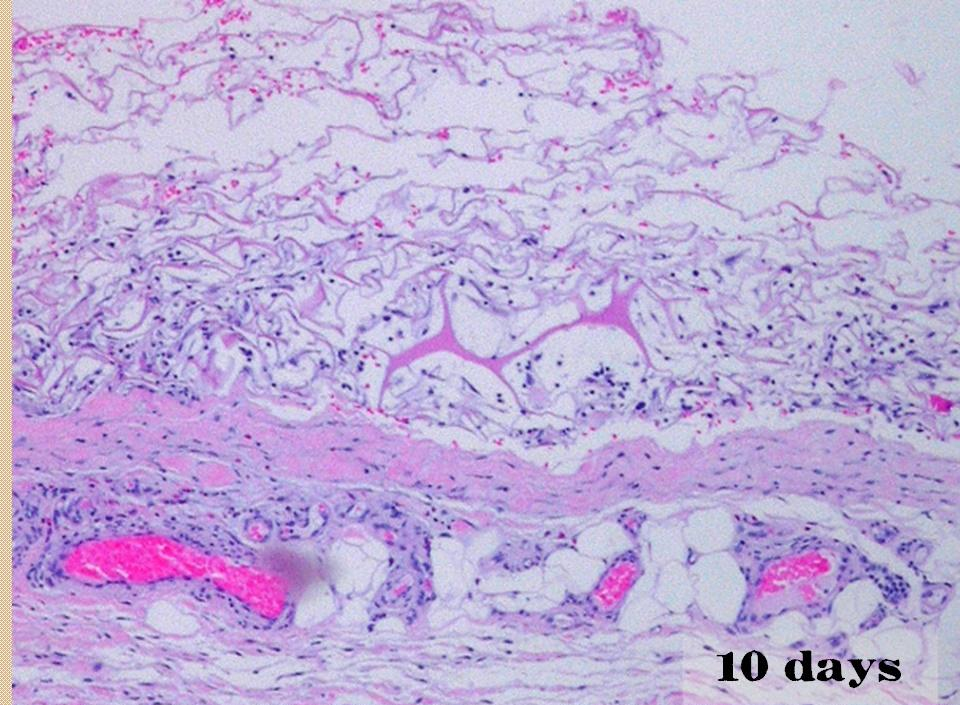
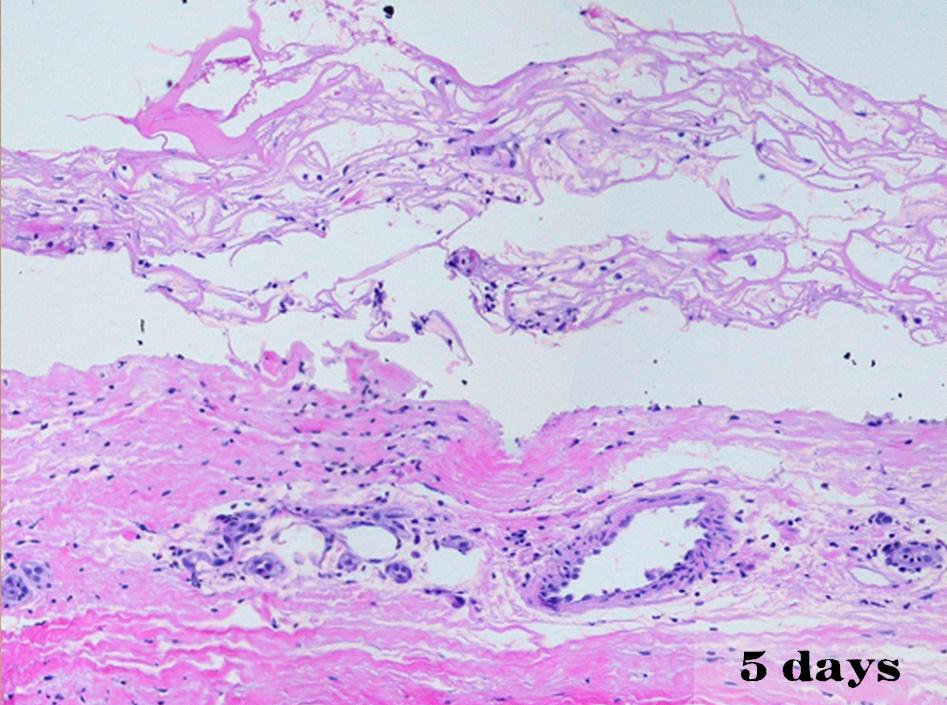


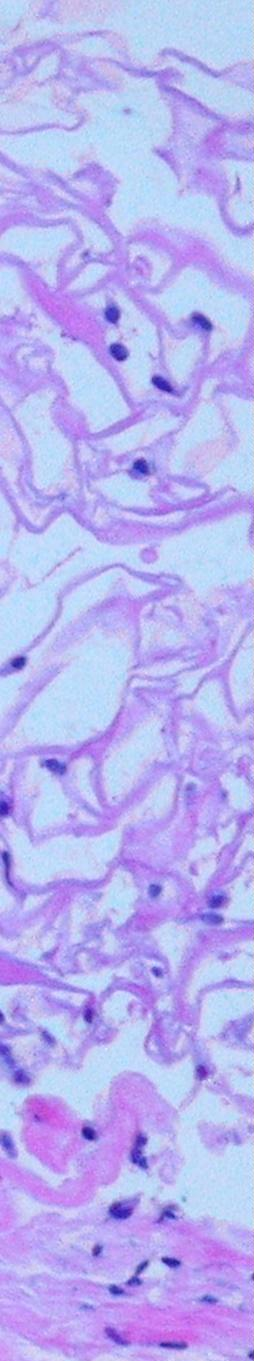




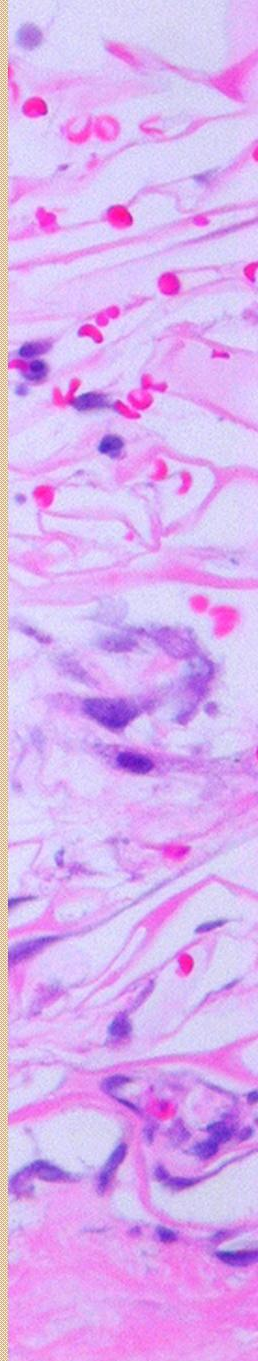




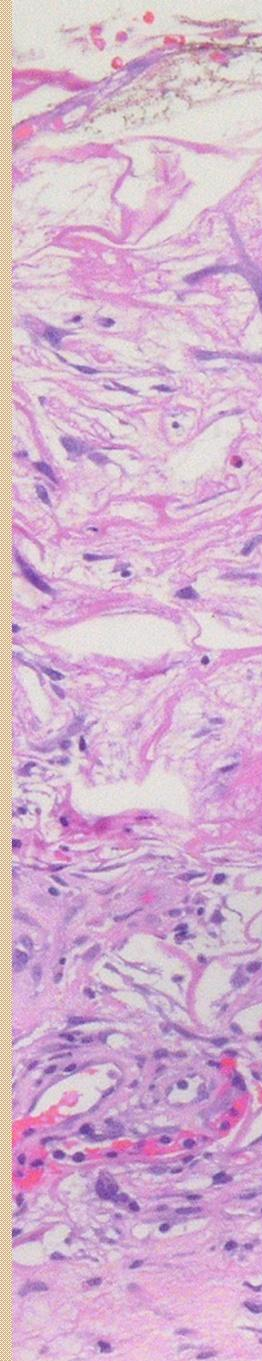




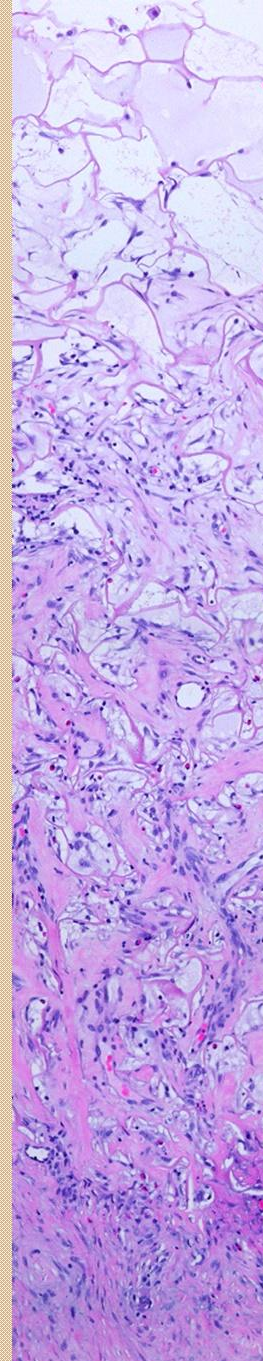
5 days



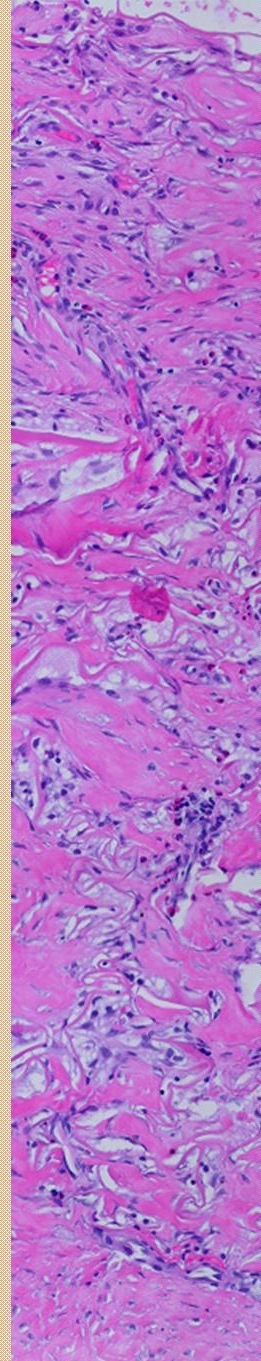
13 days



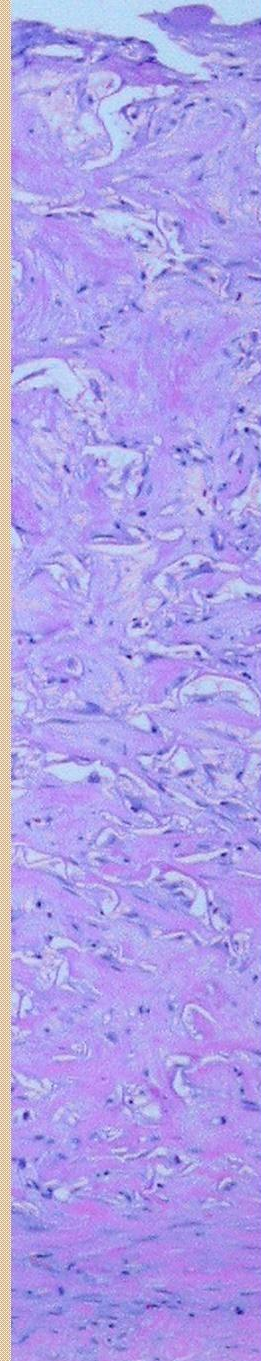
17 days



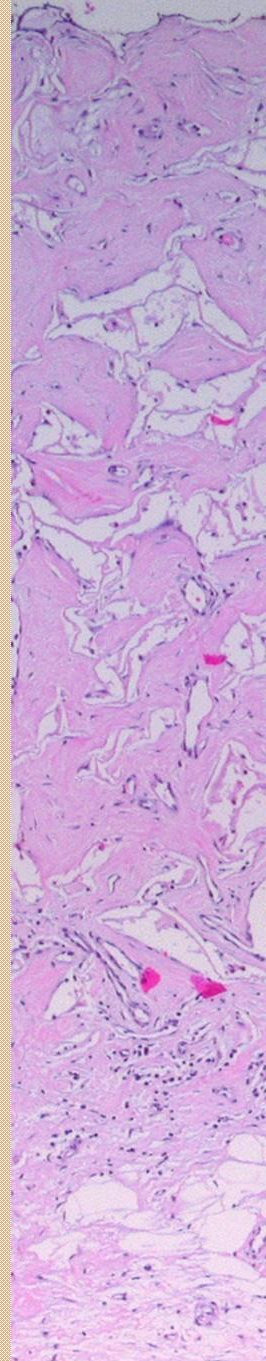
17 days



30 days



42 days



70 days

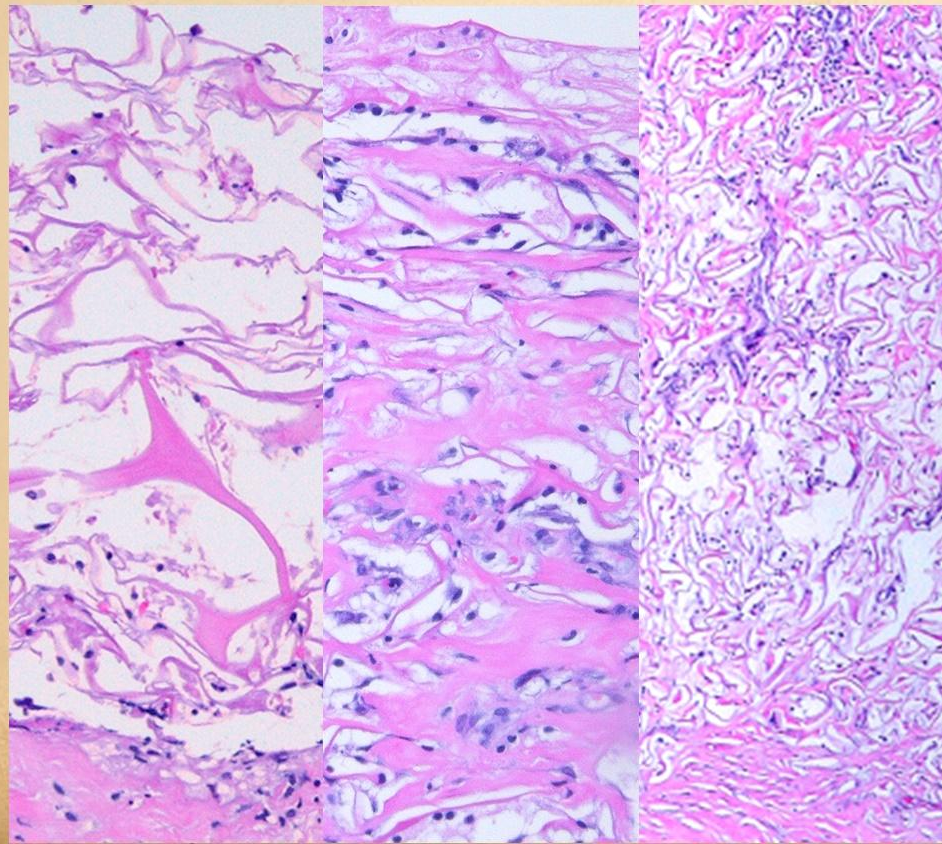
Integra Histogenesis

Normal stroma

GRADUAL RISE TO CORRECT MODEL

Early : closed loop, regulated, distributed

Late : consolidation to reference anatomy



host

entry

consolidation

fibroplasia

primary histogenesis

3 weeks

10 weeks

host

entry

consolidation

consolidation

fibroplasia

fibroplasia

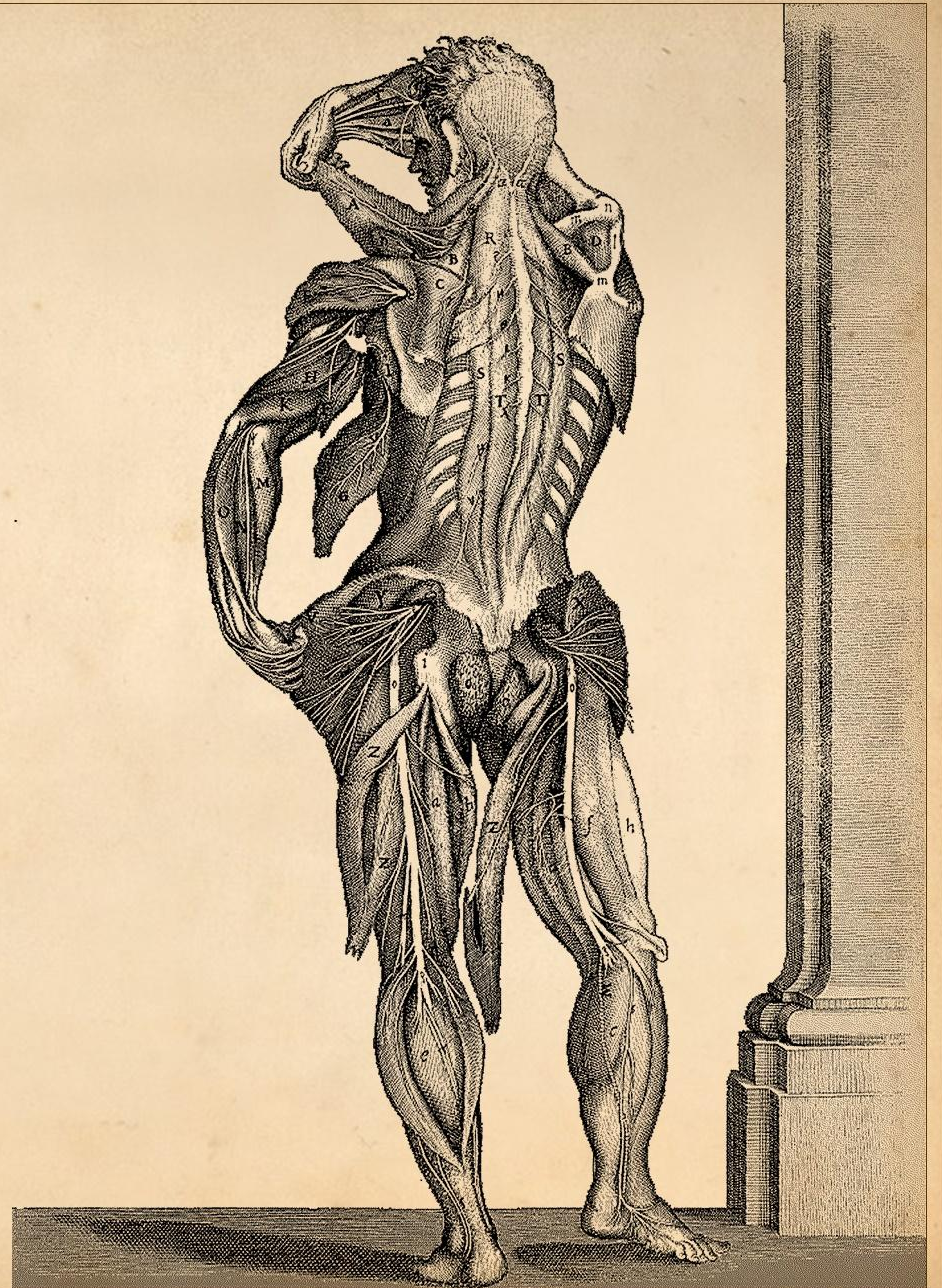INTEGRA REGENERATION

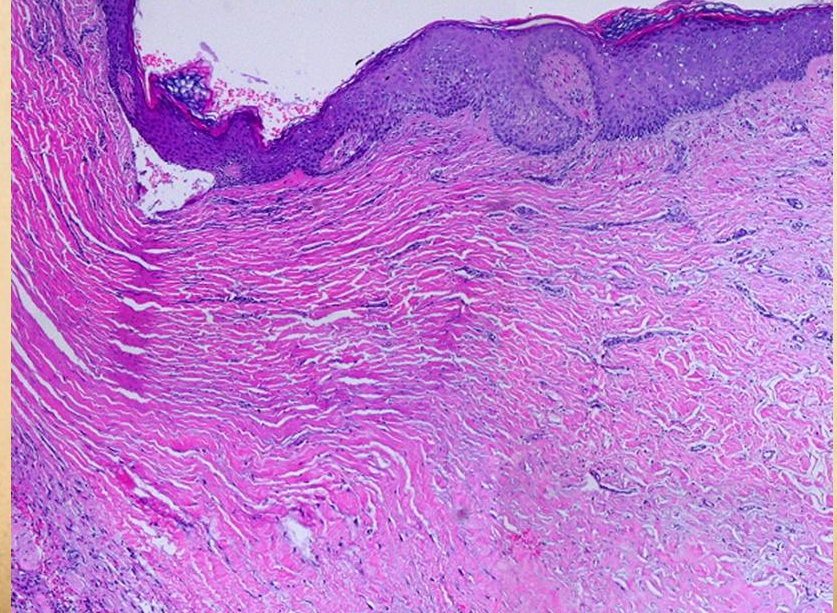
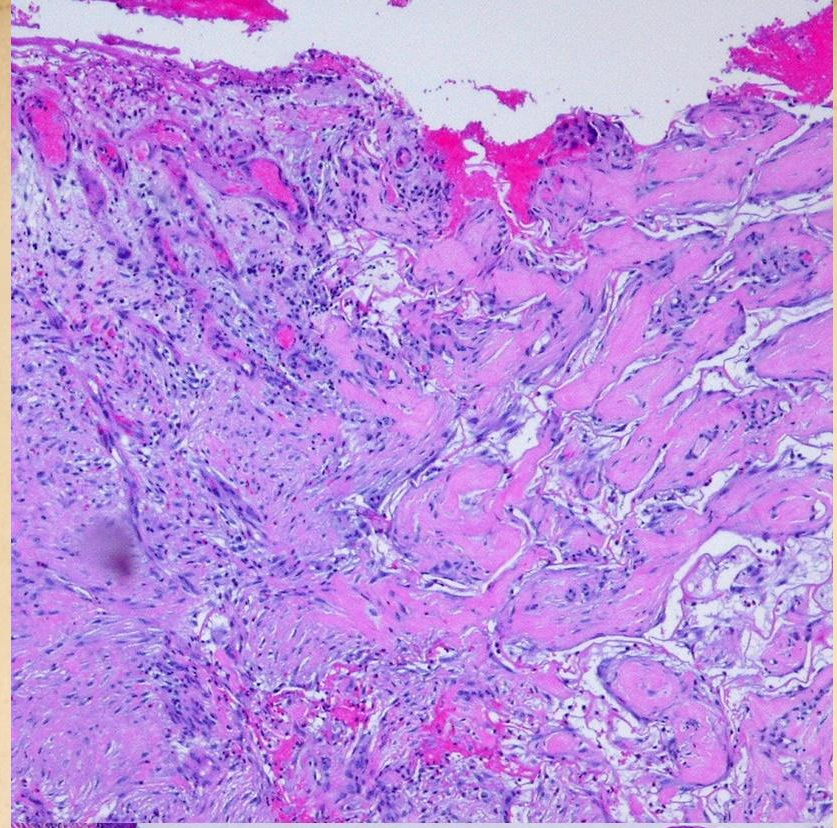
CORRELATION WITH PRIMARY DEVELOPMENTAL HISTOGENESIS



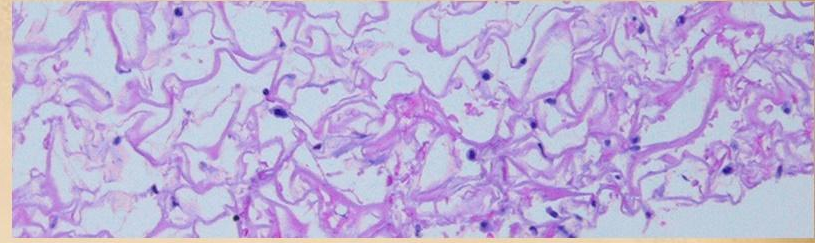
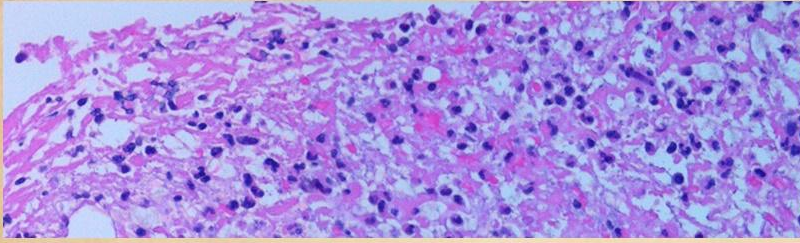
VARIANCES FROM ORDINARY
INFLAMMATORY-FIBROUS
WOUND HEALING

EMBRYONIC
TISSUE FORMATION

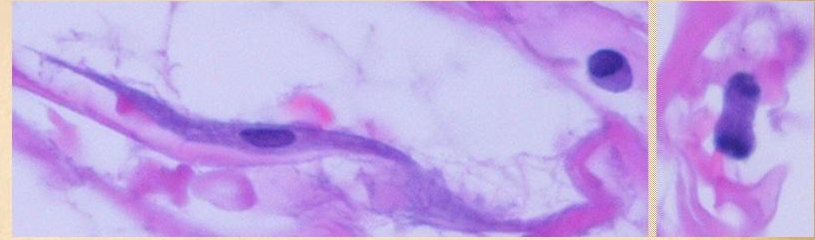
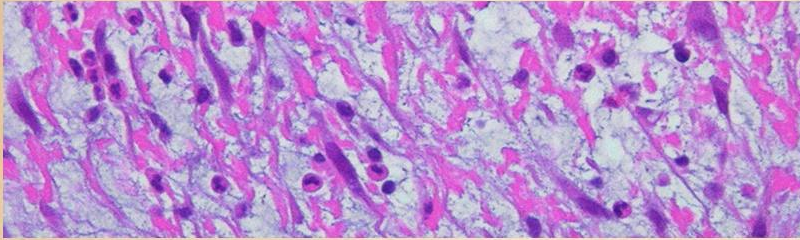




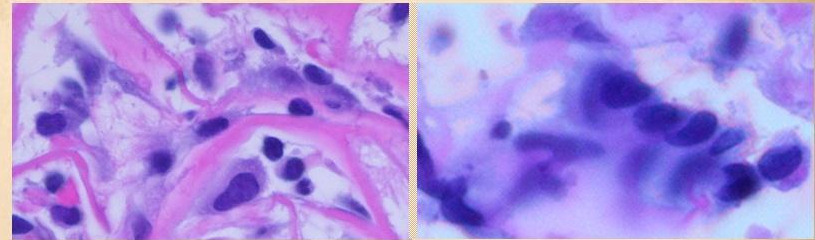
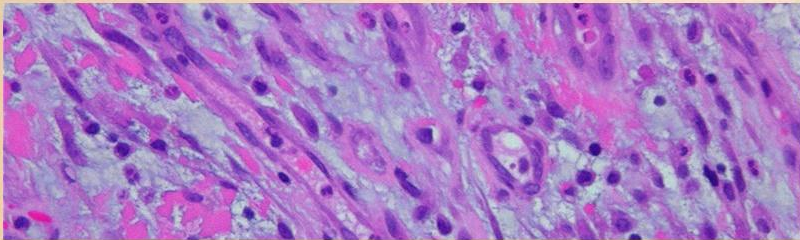
arrival
recognition



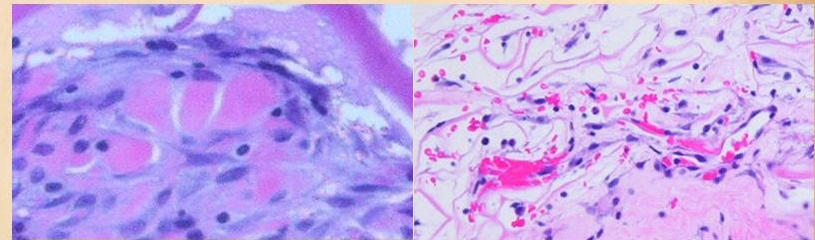
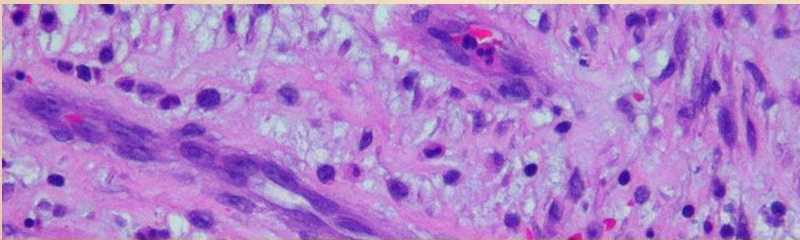
stimulus
activation



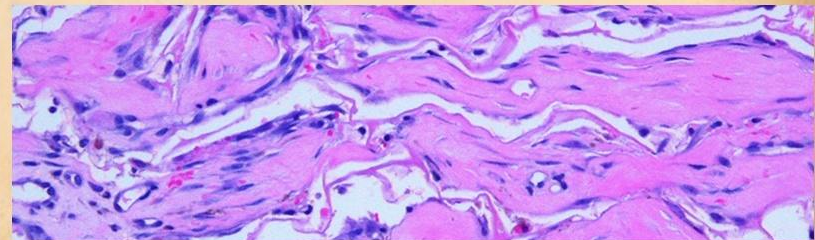
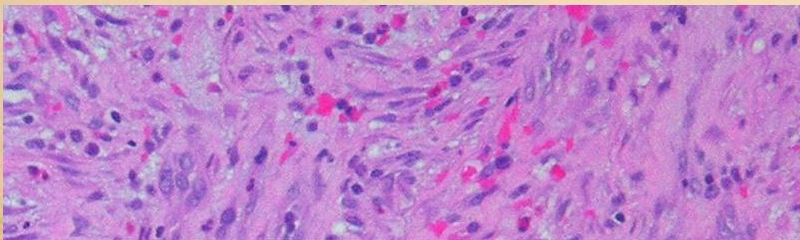
organization



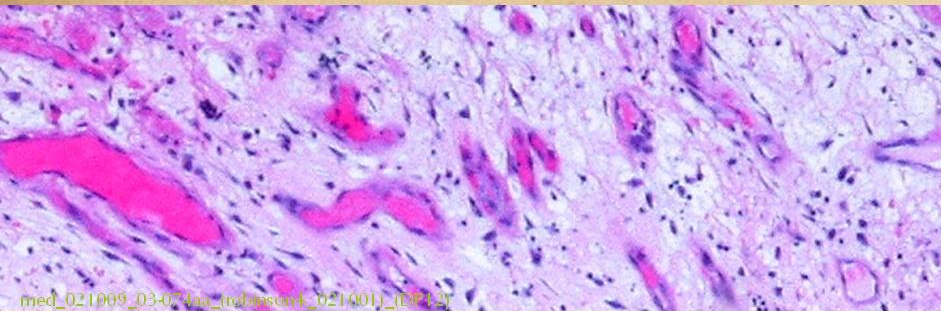
early
structure



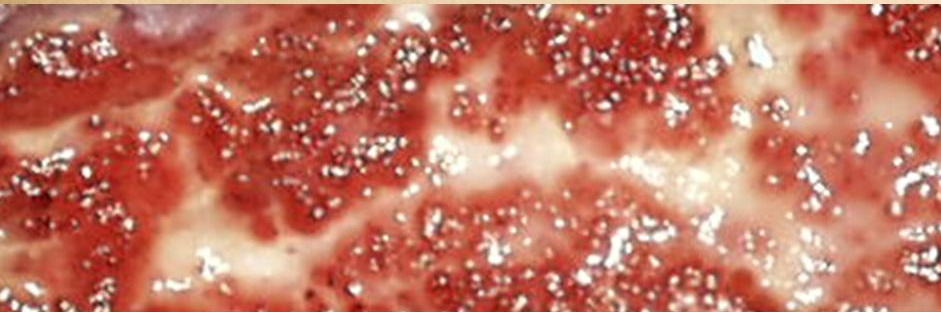
advanced
structure



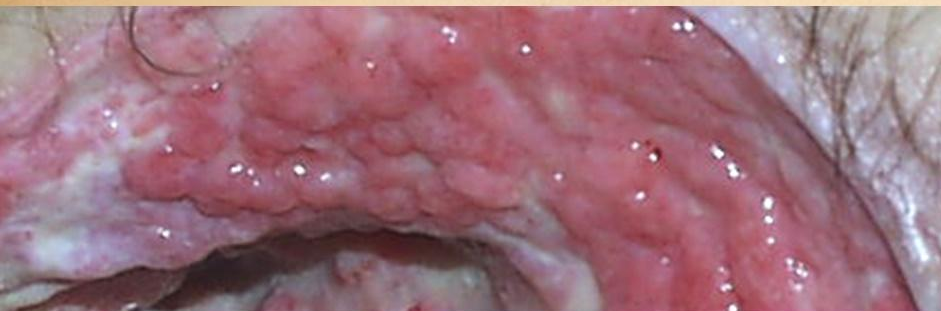INFLAMMATORY REPAIR



inflammatory angiogenesis :
unregulated open loop, forced by extrinsic cells

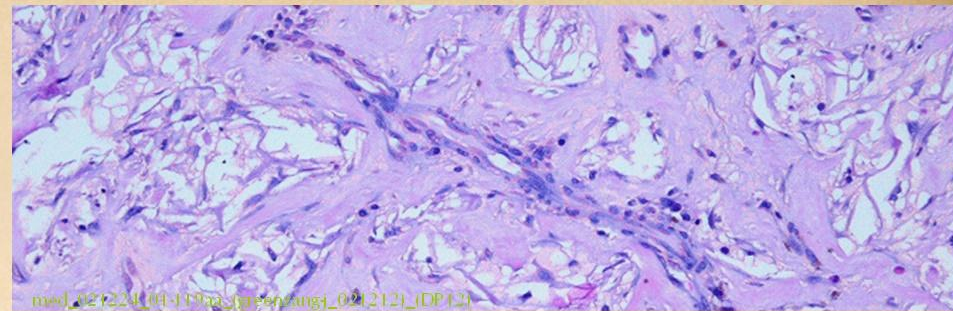


result of unregulated angiogenesis :
highly proliferative, excess vascular density

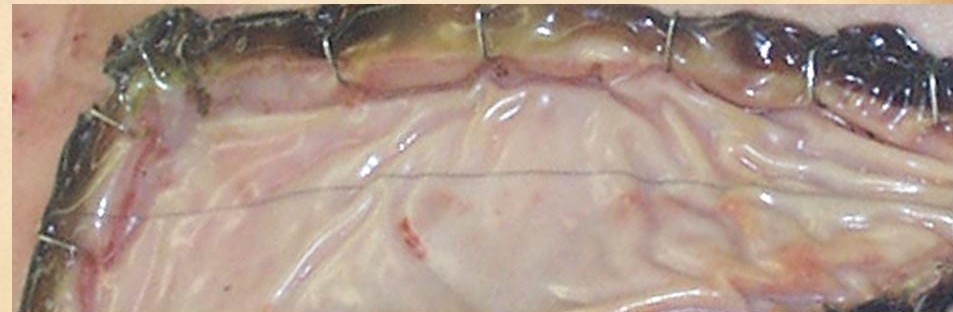

granulation tissue : dense red color
from high blood volume in excess vessels

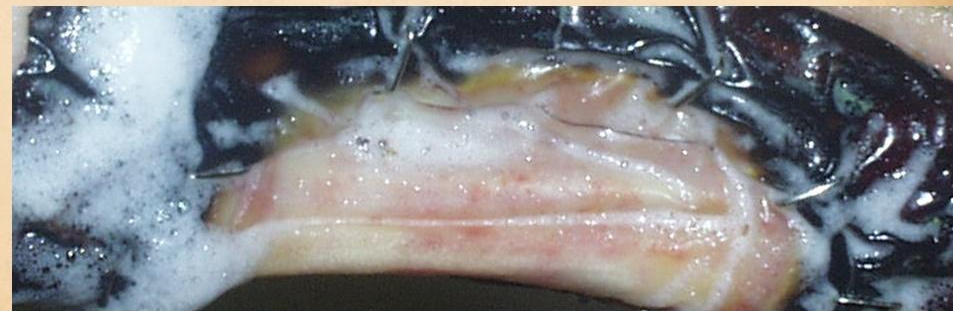
INTEGRA HISTOGENESIS



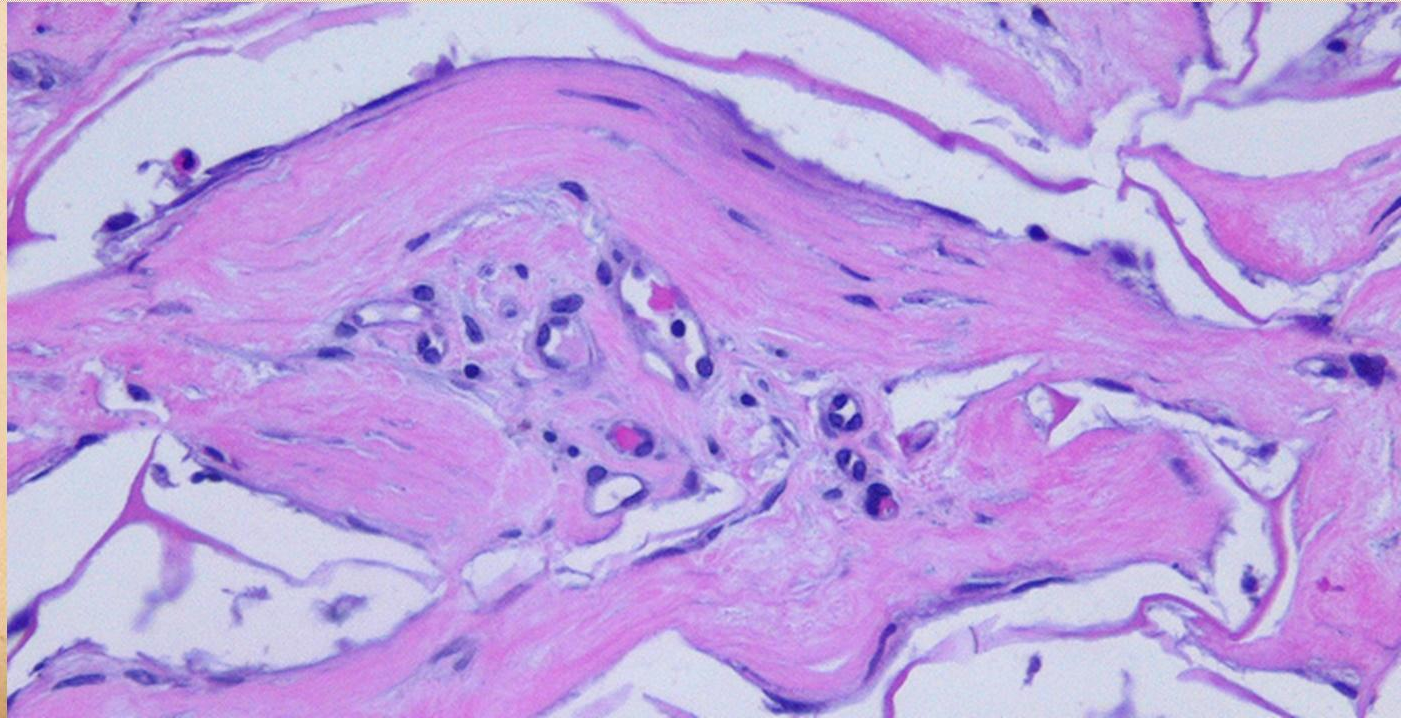
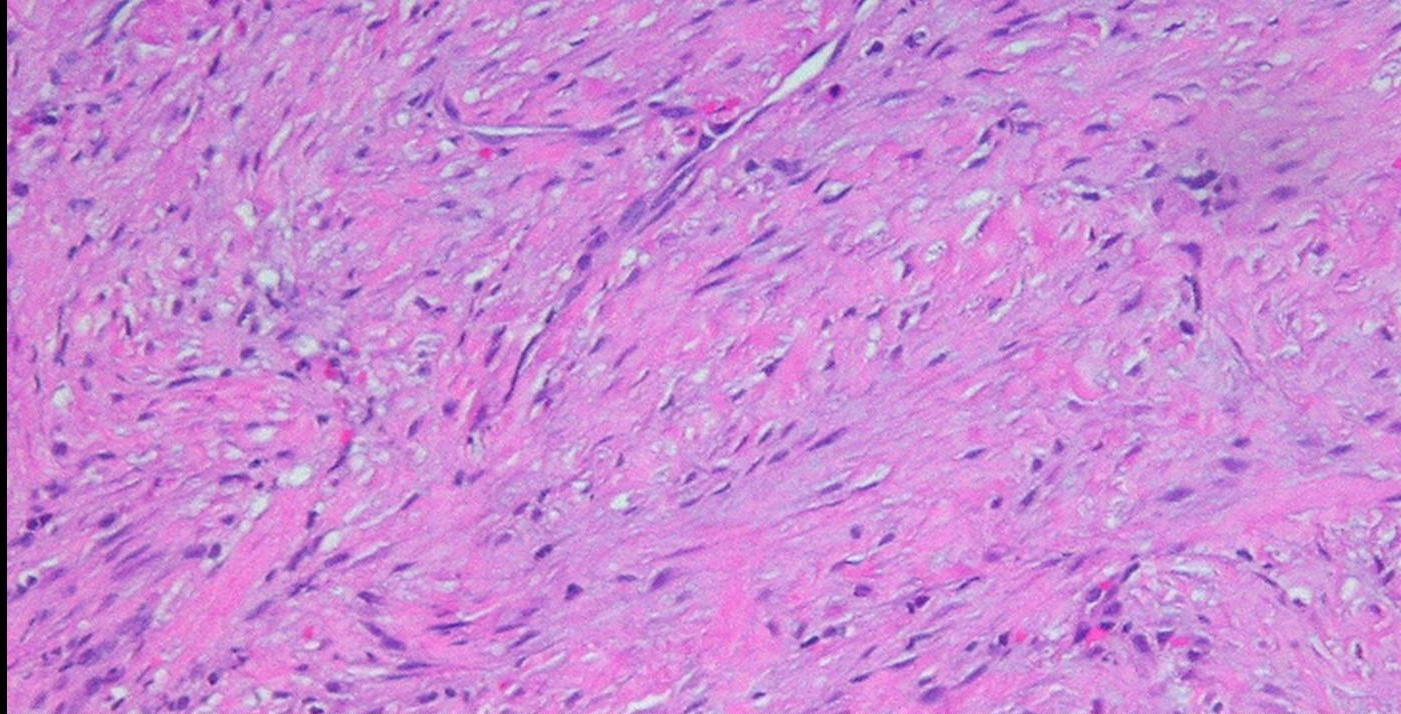
embryonic angiogenesis :
closed loop process, regulated by intrinsic tissue



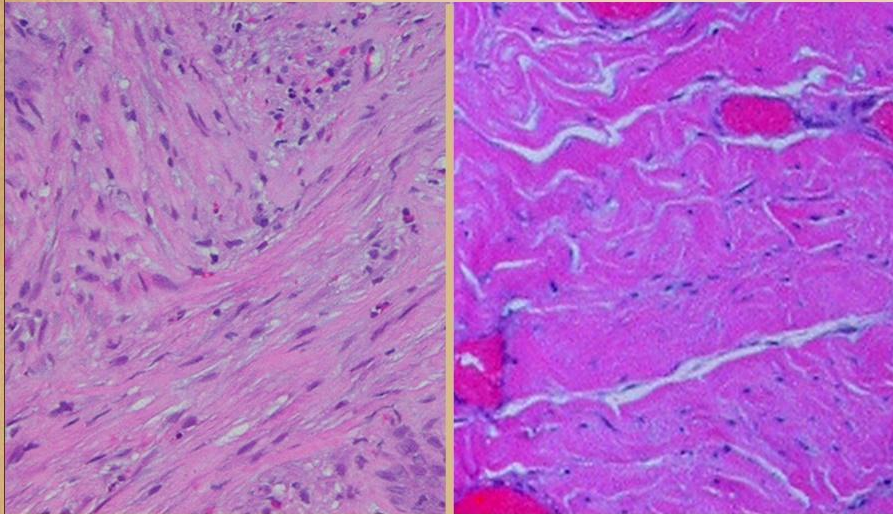
regulation by normal tissue development :
precise and efficient vascular density



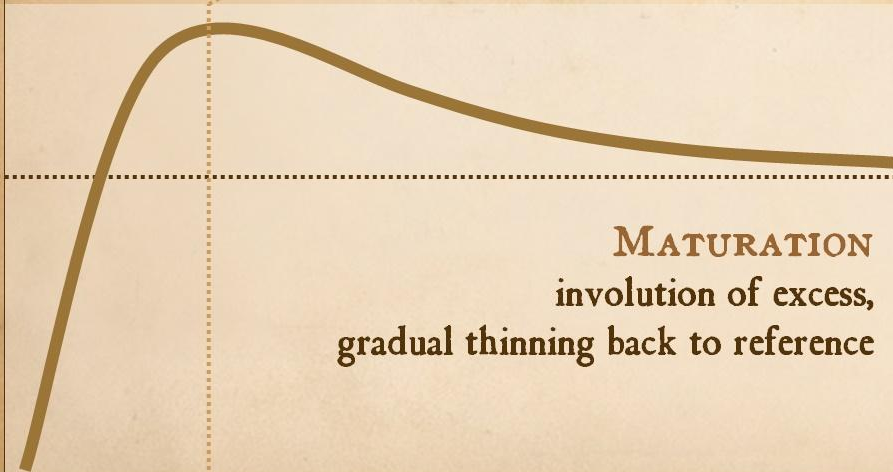
embryonic tissues : white or pink
from lower blood volume & proper vessel density



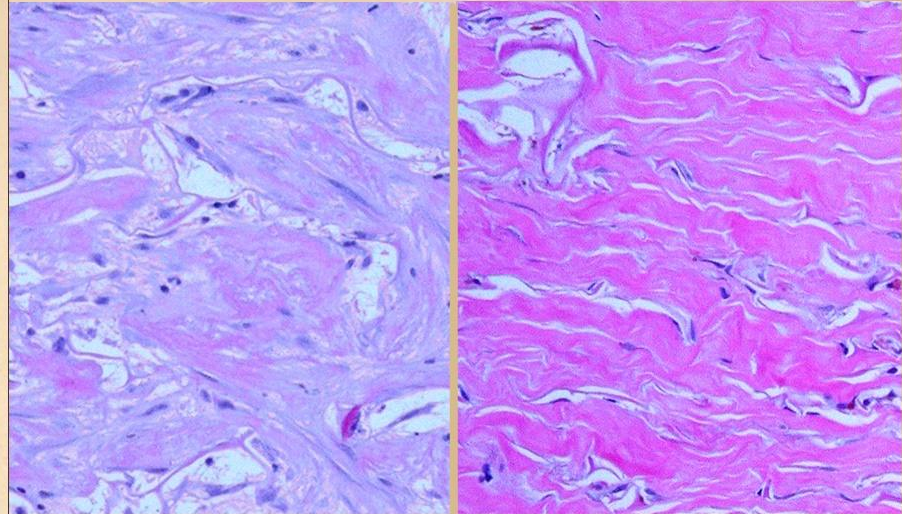
INFLAMMATORY WOUND HEALING OVERSHOOT, THEN INVOLUTE



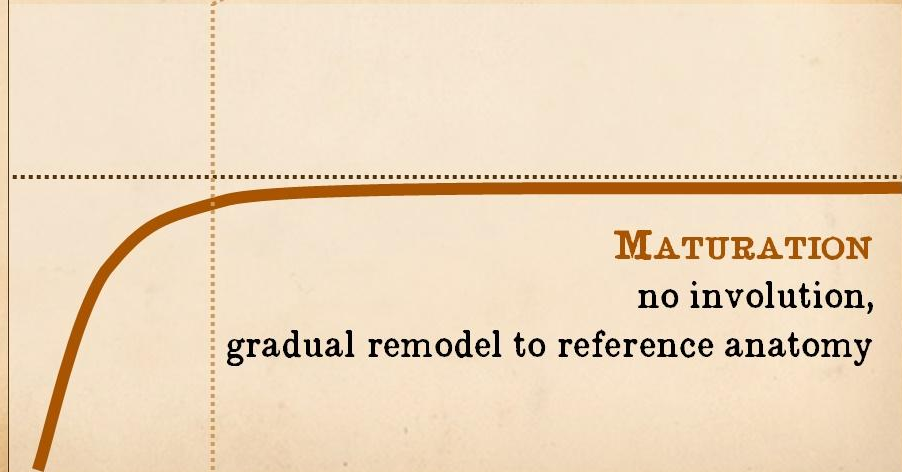
PROLIFERATION
auto-amplifying,
hyper-density,
open loop



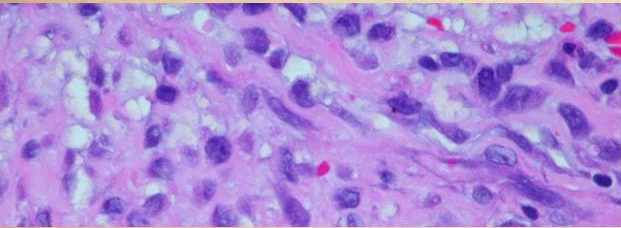
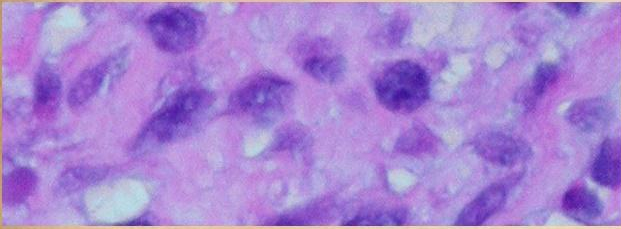
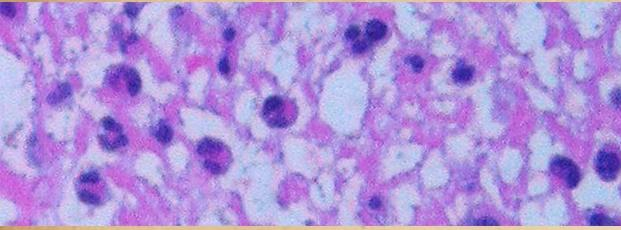
Integra Histogenesis GRADUALLY BUILD CORRECT MODEL



PROLIFERATION
proper density,
closed loop,
regulated



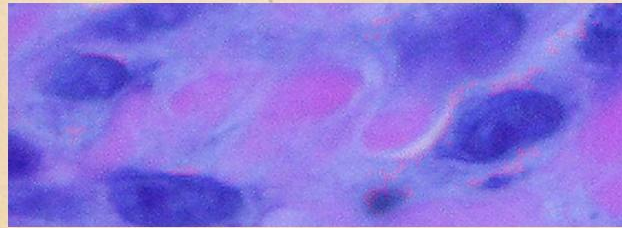
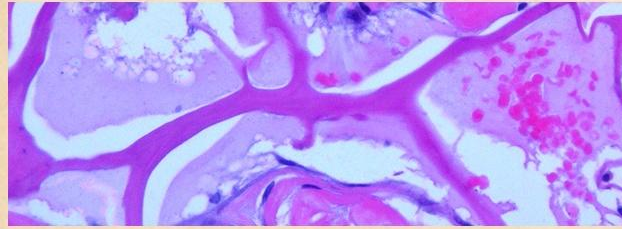
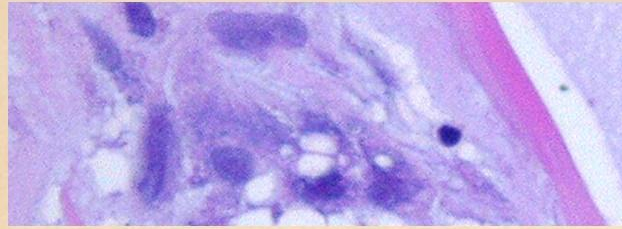
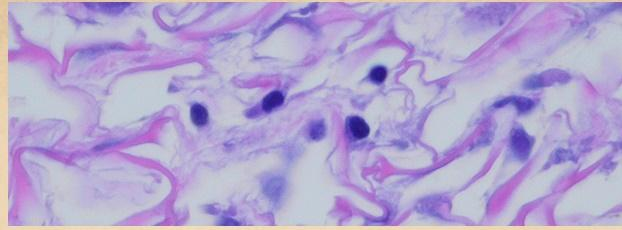
Inflammatory Repair



Inflammatory Repair

involution of excess
wound module

Integra Histogenesis



Integra Histogenesis

consolidation to
reference anatomy

Embryonic Histogenesis

Histogenic embryonic cells.
No inflammation.

The Embryonic Dermatoblast

Holbrook & Smith, "Birth Defects", 1981

Dermis of 1-2 month embryo:

Watery, cellular, long slender pseudopodia,
syncytium, secrete ground substance matrix,
fibrils 20-30nm visible in light microscopy.

Role of glycosaminoglycans
and ground substance.

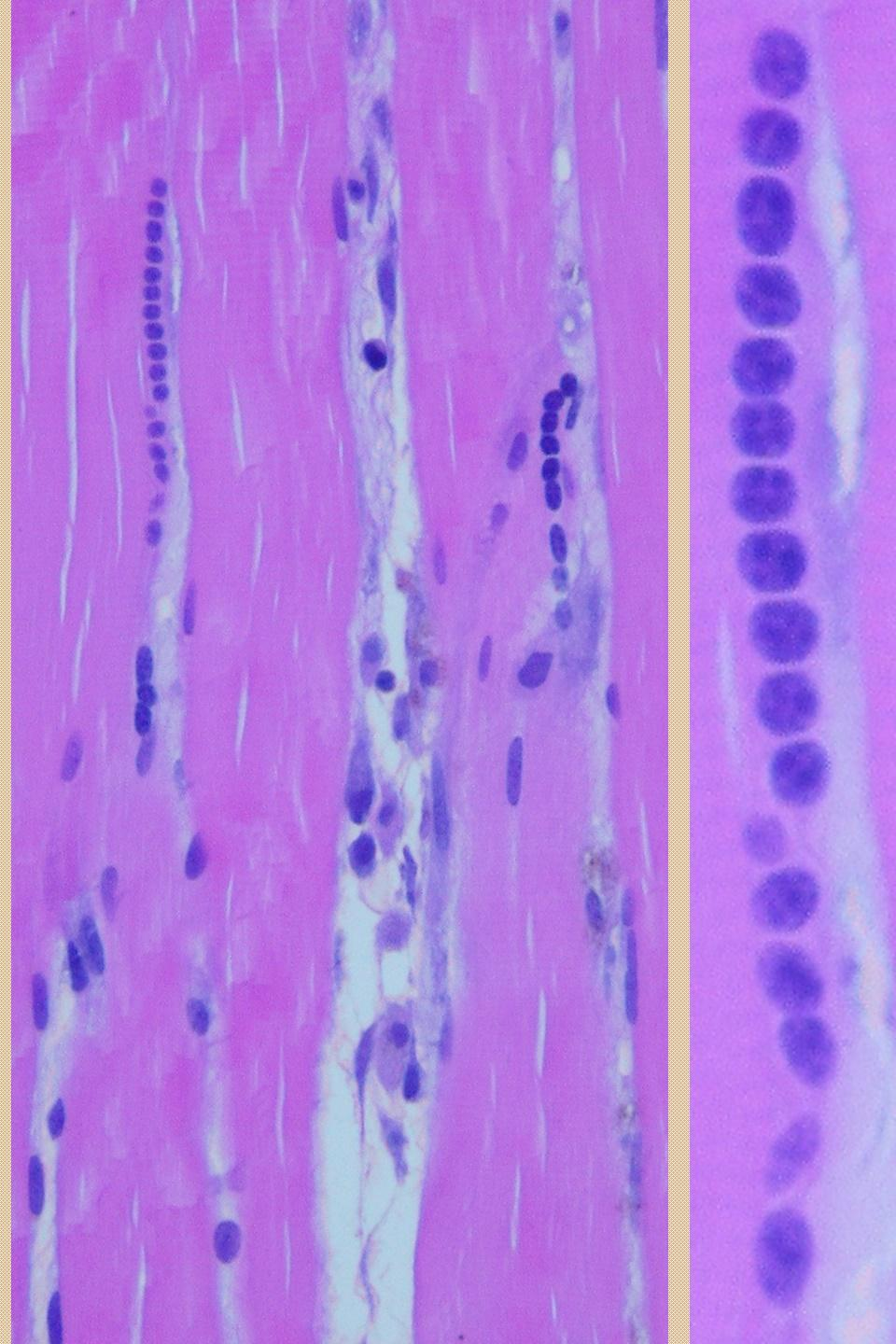
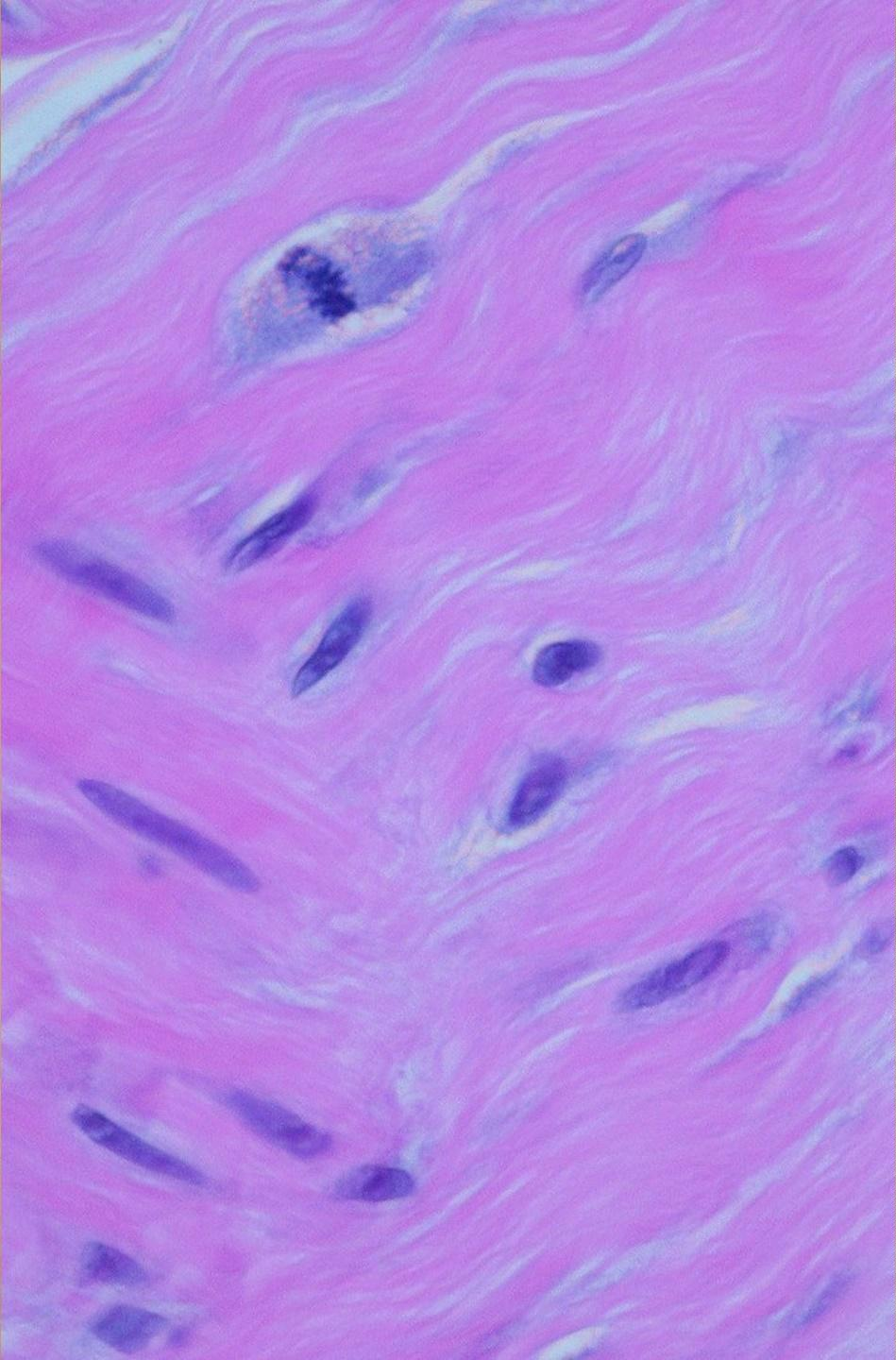
Characteristics of collagen
fibers and bundles.

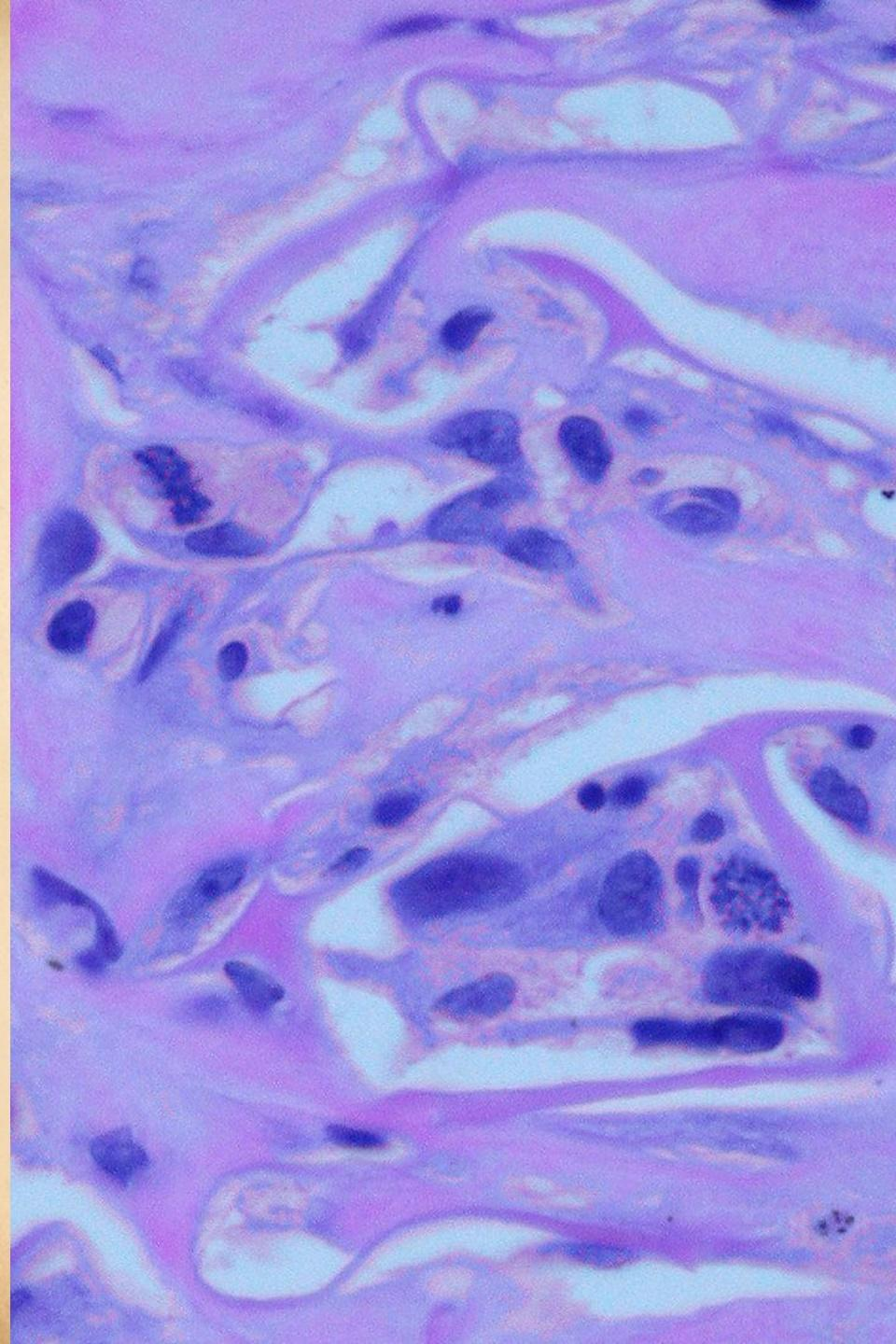
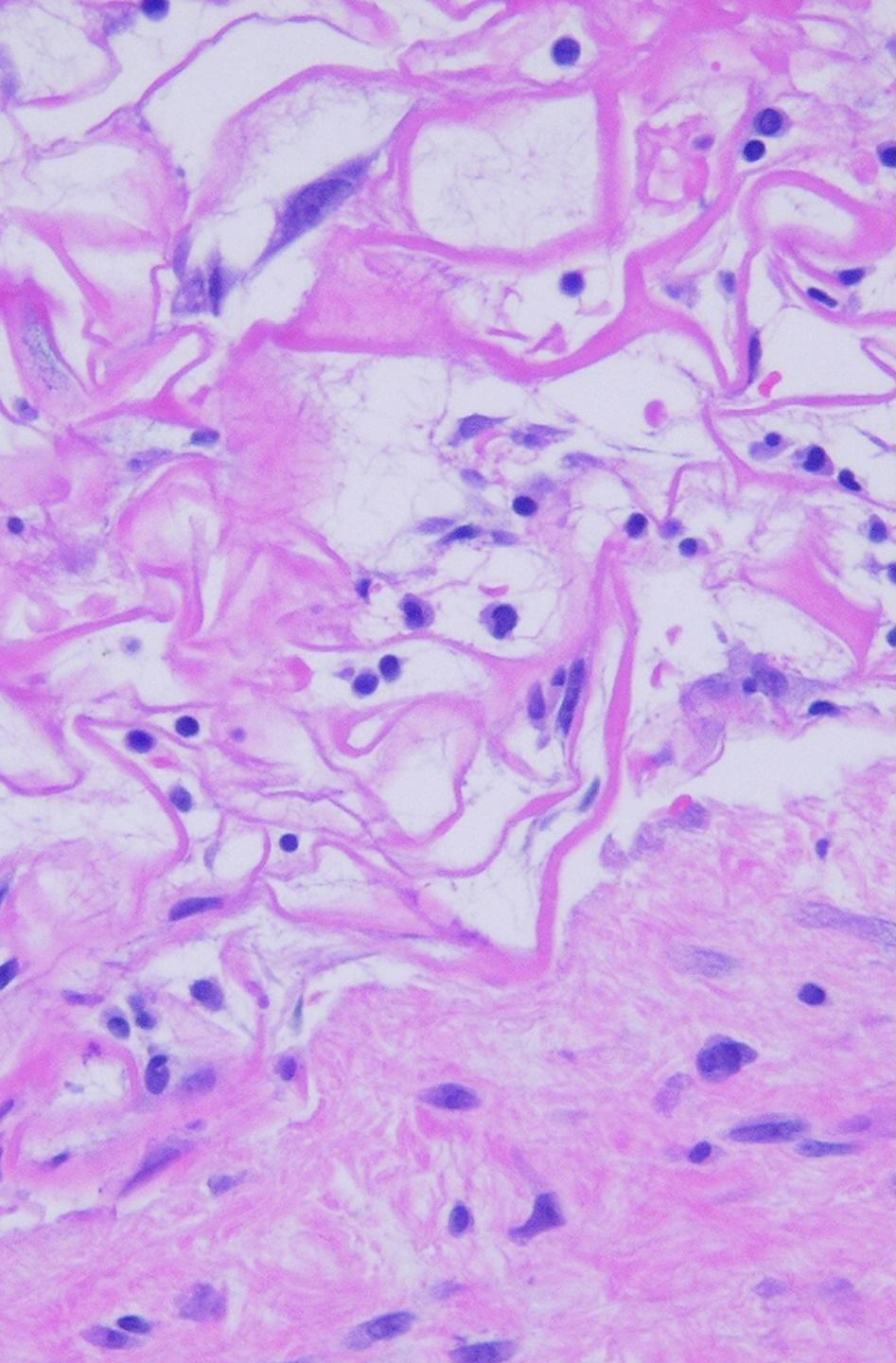
Embryonic Histogenesis

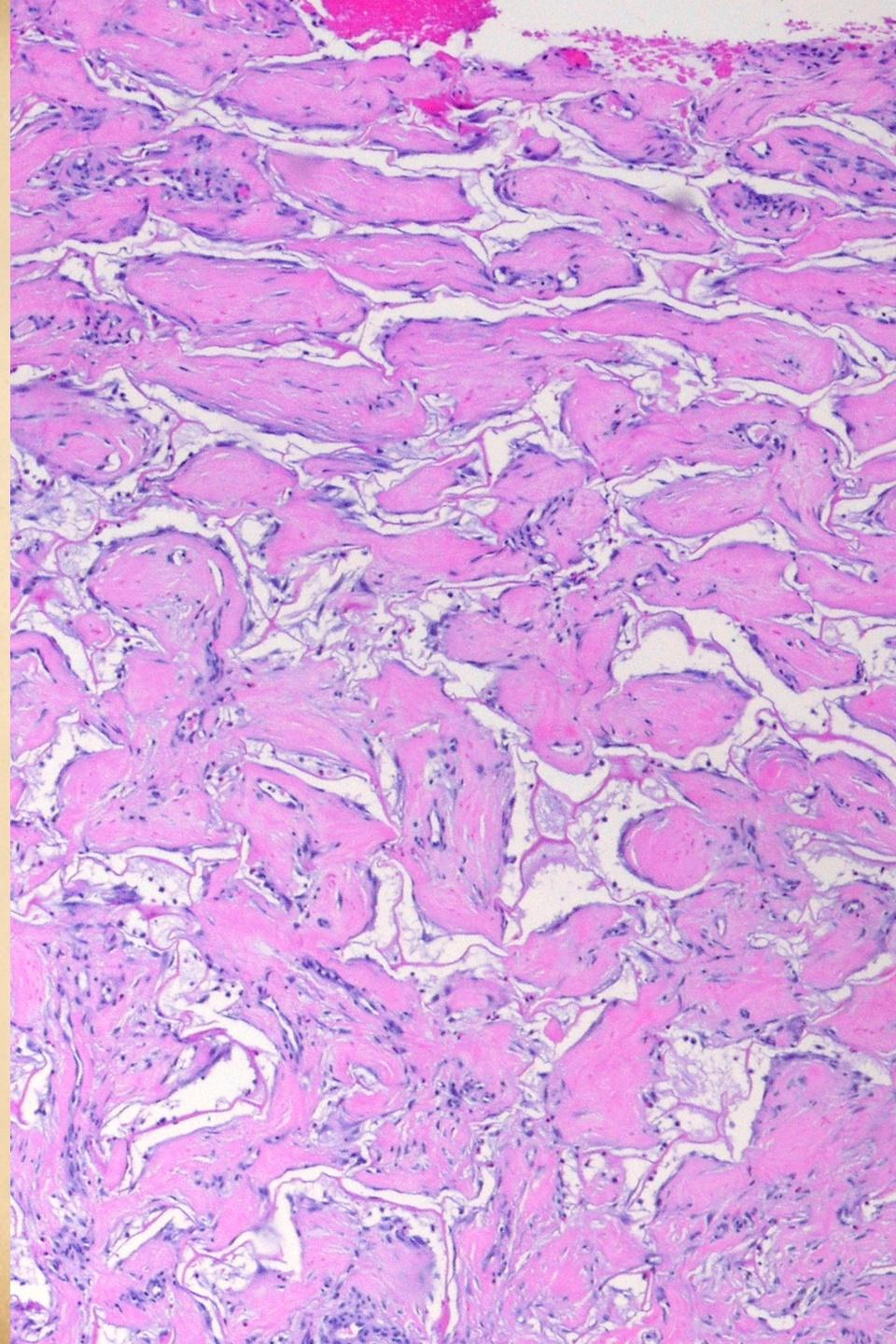
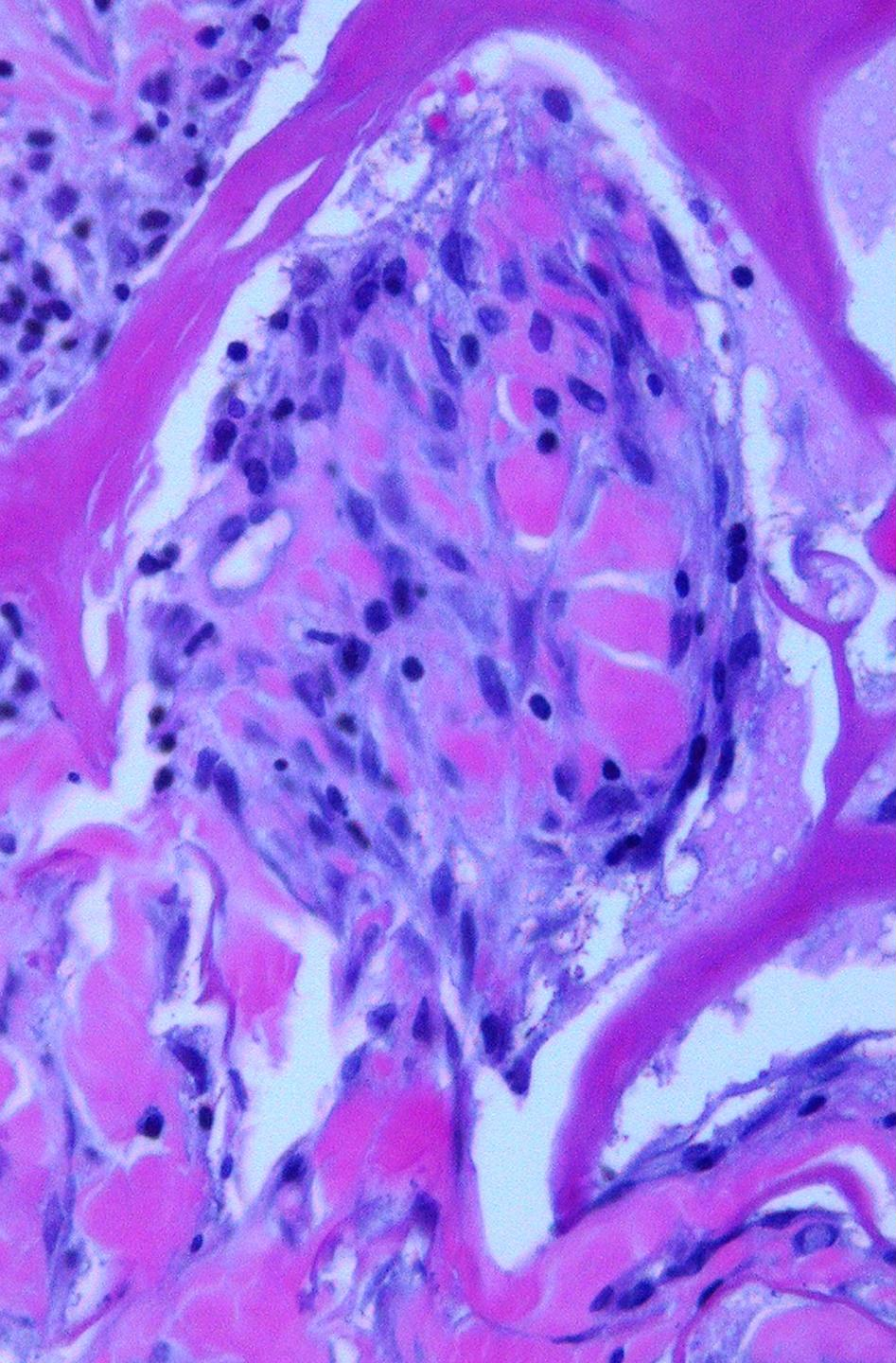
creation of
reference anatomy

REPAIR - VS - HISTOGENESIS

CONDITION	INFLAMMATORY REPAIR	INTEGRA HISTOGENESIS	EMBRYONIC DERMATOGENESIS and FETAL WOUND REPAIR
INFLAMMATION	inflammation triggers the process	inflammation is suppressed	no inflammation
CONTROL CELLS	chemotactically summoned marrow-derived cells	resident local mesenchyme (or possibly marrow derived patrol cells)	locally developing mesenchyme
CONTROL CELL INITIATION	extrinsic direction by summoning cells	intrinsic direction by arriving cells	intrinsic direction by resident cells
TYPE OF CELL RESPONSE	defensive	non-defensive, histogenetic	non-defensive, histogenetic
TYPE OF HEALING	wound module inflammatory repair	generative (embryonic) histogenesis	generative and regenerative histogenesis
DYNAMICAL CONTROL SYSTEM	open-loop, controllers extrinsic to tissue	closed-loop, controllers intrinsic to tissue	closed-loop, controllers intrinsic to tissue
ORDER OF HISTOGENESIS	angiogenesis leads, fibroblasts follow	fibroblasts lead, angiogenesis follows	dermatoblasts lead, angiogenesis follows
VASCULOGENIC DYNAMICS	target or gradient angiogenesis	distributed field angiogenesis	distributed field angiogenesis
VASCULAR DENSITY	hyperdensity angiogenesis	correct density angiogenesis	correct density angiogenesis
TYPE OF HISTOGENETIC CELL	classic fibroblasts	syncytial fibroblasts	syncytial fibroblasts (dermatoblasts)
COLLAGEN ARCHITECTURE	dense, non-compliant	percolated, distensible	percolated, distensible
SCAR CONTRACTION	prominent	absent	absent
STAR CHEMICAL	collagen (structural)	glycosaminoglycans (process regulator)	glycosaminoglycans (process and structure)







IN SITU TISSUE ENGINEERING WITH REGENERATIVE MATRICES

Integra · Collagen-GAG Matrix

Normal post-inflammatory proliferative wound healing is cancelled.

Embryonic histogenesis & dermatogenesis is induced.


These materials turn on a genetic or biodynamical “subroutine” that is key to embryonic and fetal development, but which is turned off at birth, not normally meant to appear again.

Aminoglycans are key.

A new paradigm of surgical wound closure that is independent of normal wound healing, and succeeds where conventional surgery fails.

Not an alternative, but the indicated option for problems of wound and scar pathology.

**IN SITU TISSUE ENGINEERING
AND THE
BIOPHYSICS OF REGENERATIVE MATRICES**



INTEGRA collagen-GAG matrix solves problems when classical paradigms of surgery will not work, by suppressing normal inflammation and wound healing and inducing embryonic regeneration.

... risolve i probleme quando paradigmi classici di chirurgia non funzionerà, sopprimendo infiammazione e la guarigione normale delle ferite, — e inducendo la rigenerazione embrionale.



END

FINE

ספר חנוכה

ו

ספר חנוכה

